

Balanitis Xerotica Obliterans: A Case Report

BALANİTİS KSEROTİKA OBLİTERANS: BİR OLGU BİLDİRİMİ

Deniz SEÇKİN*, M. İleriş TEKİN**, A. Tülin OĞUZ GÜLEÇ*

* Dept. of Dermatology, Başkent University Faculty of Medicine,

** Dept. of Urology, Başkent University Faculty of Medicine, Ankara, TURKEY

Summary

Balanitis xerotica obliterans (BXO), or lichen sclerosus et atrophicus of the penis, is a chronic, progressive disease with uncertain etiology. It is one of the most common causes of acquired meatal stenosis, and is the cause of phimosis in up to ten percent of children. Few reports have been made of squamous cell carcinoma arising from or in association with BXO. We present a patient with BXO with meatal involvement in whom urethral meatotomy was performed. The patient remains free of recurrence after 11 months postoperatively.

Key Words: Balanitis xerotica obliterans, Lichen sclerosus et atrophicus, Meatal stenosis, Squamous cell carcinoma, Treatment

T Klin J Dermatol 1999, 9:164-166

Balanitis xerotica obliterans (BXO) or lichen sclerosus et atrophicus (LSA) of the penis is a progressive, sclerotic, constrictive, scar-forming disease process of the penile prepuce that can involve the frenulum and urethral meatus (1,2). The term BXO was first used by Stühmer in 1928 (3). There have been some case reports of squamous cell carcinoma (SCC) arising from or in association with BXO (4-7). We describe a patient with BXO in whom urethral meatotomy was the treatment of choice.

Case Report

A 35-year-old man was seen in consultation from Urology Department, because of white, sclerotic area around the urethral meatus. He had com-

Geliş Tarihi: 13.04.1998

Yazışma Adresi: Deniz SEÇKİN
16.sok. 11/3
Bahçelievler 06490, ANKARA

Özet.

Balanitis kserotika obliterans (BKO) veya penis yerleşimli liken sklero-atrofik, etyolojisi tam olarak bilinmeyen, kronik, progresif seyir gösteren bir hastalıktır. BKO, edinsel meatal stenozun en sık nedenleri arasında yer alır ve çocuklardaki fimozisin de yaklaşık olarak %10'undan sorumludur. BKO ile birlikte seyreden veya BKO'dan kaynaklanan az sayıda skuamöz hücreli karsinoma olgusu bildirilmiştir. Bu makalede üretral meatotominin uygulandığı, meatal tutulum gösteren bir BKO olgusu sunulmaktadır. Operasyondan sonraki onbirinci ayda hastada rekürrens izlenmemiştir.

Anahtar Kelimeler: Balanitis kserotika obliterans, Liken sklero-atrofik, Meatal stenoz, Skuamöz hücreli karsinoma, Tedavi

T Klin Dermatoloji 1999, 9:164-166

plaints of burning sensation and narrowing at the tip of the penis for the last 2 years. He was able to urinate with difficulty and with a narrow stream. Physical examination of the glans penis revealed white, sclerotic area measuring 1 cm in diameter around the external meatus, and stenosis of the external meatus (Figure 1). He was circumcised at age 6. Histopathologic examination showed hyperkeratosis, hyalinization of collagen, capillary proliferation and mononuclear inflammatory cell infiltration in the dermis, indicative of BXO. Complete dermatologic examination excluded extragenital LSA.

Urethroscopy performed to determine the full extent of urethral involvement showed that sclerosis was confined only to urethral meatus. The disease was managed with urethral meatotomy and excision of the sclerotic area. The cure was achieved with good functional results and no recurrence was observed after 11 months.

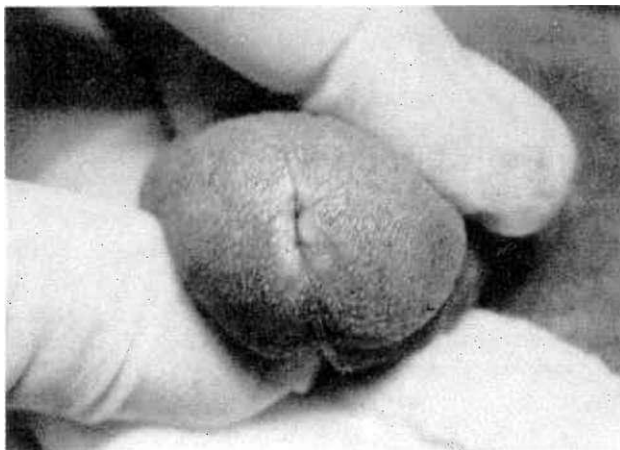


Figure 1. BXO shows white, sclerotic area around the external meatus.

Discussion

BXO, now generally considered to be synonymous with LSA of the penis, is one of the most common causes of acquired meatal stenosis in children and adults (1). In prepubertal boys, examination of foreskins submitted to histopathologic examination for various conditions (usually phimosis) revealed a significant percentage (3.6% to 19%) of BXO (1,2,8). Chalmers et al stated that scarring phimosis in boys is one of the most common manifestations of BXO (8). Because BXO can also be asymptomatic, many cases probably go unrecognized. The course of the disease is usually chronic and slowly progressive, but it may be rapidly progressive (6).

Patients with BXO present with itching, loss of glans sensation, painful erections, sudden phimosis in a previously retractable foreskin, adhesions to the glans, meatal stenosis, dysuria, urethral discharge, diminution in force or caliber of urinary stream, or urinary obstruction. Typical lesions are white, blue-white, or yellow-white plaques with an atrophic, mottled appearance, which may be found on the foreskin, glans, and parameatal area. Progression can lead to obliteration of the coronal sulcus and frenulum. Meatal stenosis and submeatal stricture develop when the lesion extends into the urethral meatus and fossa navicularis (1,2,6,8).

There have been a long debate about an association of BXO and penile cancer. SCC arising in documented BXO has been reported only infre-

quently (4-7). The potential risk is mistaking similar conditions like leukoplakia, which is considered premalignant, for BXO without confirmation by biopsy. Some authors, therefore, believe that the association of BXO and SCC is coincidental (1,6). Although the pathogenesis of SCC arising in BXO is not clear, a common thought has been the lack of neonatal circumcision (6).

The histologic features of BXO are fairly typical and consists of hyperkeratosis, effacement of epidermis, interface vacuolization, homogenization and edema of papillary dermis, and lichenoid infiltration (1,2).

Clinically and histologically, BXO must be distinguished from similar lesions affecting the glans, the prepuce, and the penile skin such as leukoplakia, lichen planus, and erythroplasia of Queyrat (1).

The etiology of BXO is uncertain, but it is an inflammatory condition often associated with trauma, autoimmune diseases, and various infectious agents (1,2). Previous trauma to the lesion site is the most common etiological association (1). BXO has been described after circumcision, surgery for squamous cell carcinoma, and surgery to correct hypospadias (2,3). Weigand speculated that ischemic effects of local factors such as chronic occlusion and irritation may have been the responsible factors in the development of BXO, since he found the typical histologic features of LSA in two percent of skin tags he examined (9). The strong association with autoimmune diseases (e.g. vitiligo, alopecia areata, Graves' disease, type I and type II diabetes, lichen planus, polymyalgia rheumatica, psoriasis, primary biliary cirrhosis, systemic lupus erythematosus, achlorhydria with or without pernicious anemia), various autoantibodies (e.g. thyroid antimicrosomal, antigastric parietal cell, antinuclear antibodies), and class II DQ antigens of the HLA system suggests an immunological factor in the pathogenesis of BXO (1,2). BXO has been reported in monozygotic twins displaying the possible genetic component of this disease (10). Many investigators have suggested the roles of various infectious agents, such as viruses and atypical mycobacteria, in the development of LSA. Recently, many reports have linked LSA to a spirochet, *Borrelia burgdorferi* (1,2).

The treatment of BXO should be preceded by the histologic diagnosis. The management of early and mild lesions of glans and meatus that are not complicated by voiding difficulties, is pharmacologic. Topical and intralesional estrogen have been used with some success (1,2). Topically applied testosterone 2% to 2.5% in petrolatum or paraffin has demonstrated both clinical efficacy and histologic regression (11). Topical, intraurethral or intralesional hydrocortisone or triamcinolone have been found to be effective. Marked benefit has been reported from brief courses of topical fluorinated steroids or clobetasol (2).

Meatal and paramental involvement by BXO requires more aggressive investigation such as dynamic retrograde and voiding urethrograms, and urethroscopy to determine the extent of urethral involvement. Carbon dioxide laser monotherapy has shown promise in treating meatal BXO (12). BXO of foreskin in uncircumcised patient is best treated by modified circumcision. Historically, meatal involvement with only meatal stenosis has been managed with repeated meatal dilations and meatotomy. In patients with repeated meatal stenosis, meatoplasty and fossa navicularis reconstruction have been more successful (13). When suitable genital skin is not available, buccal mucosal grafts (1) or skin grafts from the upper eyelids (14) may be used for reconstruction. Meatal stenosis and fossa navicularis strictures are best managed surgically at an early stage to prevent extension of stricturing into the proximal urethra.

Most cases of BXO are not recognized, and the frequency is higher than reported. Misdiagnosis and asymptomatic course of the disease, and reluctance to seek care might be responsible from underreporting of BXO. It is also important to recognize the possibility of SCC, since survival of pa-

tients with SCC depends on early diagnosis and treatment.

REFERENCES

1. Akporiaye LE, Jordan GH, Devine CJ. Balanitis Xerotica Obliterans (BXO). AUA Update Series 1997; 16(Lesson 21): 162-7.
2. Meffert JJ, Davis BM, Grimwood RE. Lichen sclerosis. J Am Acad Dermatol 1995; 32: 393-416.
3. Stühmer A. Balanitis xerotica obliterans (post operationem) und ihre beziehungen zur 'kraurosis glandis et praeputii penis'. Arch Dermatol Syph 1928; 156: 613-23.
4. Bart RS, Kopf AW. Squamous cell carcinoma arising in balanitis xerotica obliterans. J Dermatol Surg Oncol 1978; 4: 556-7.
5. Campus GV, Alia F, Bosmcu L. Squamous cell carcinoma and lichen sclerosis et atrophicus of the prepuce. Plast Reconstr Surg 1992; 89: 962-4.
6. Pride HB, Miller OF, Tyler WB. Penile squamous cell carcinoma arising from balanitis xerotica obliterans. J Am Acad Dermatol 1993; 29: 469-73.
7. Weigand DA. Lichen sclerosis et atrophicus, multiple dysplastic keratoses and squamous cell carcinoma of the glans penis. J Dermatol Surg Oncol 1980; 6: 45-50.
8. Chalmers RJG, Burton PA, Bennett RF, Goring CC, Smith PJB. Lichen sclerosis et atrophicus. Arch Dermatol 1984; 120: 1025-27.
9. Weigand DA. Microscopic features of lichen sclerosis et atrophicus in acrochordons: A clue to the cause of lichen sclerosis et atrophicus. J Am Acad Dermatol 1993; 28: 751-4.
10. Fallick ML, Faller G, Klauber GT. Balanitis xerotica obliterans in monozygotic twins. Br J Urol 1997; 79: 810.
11. Pasioczny TAH. The treatment of balanitis xerotica obliterans with testosterone propionate ointment. Acta Derm Venereol (Stockh) 1977; 57: 275-7.
12. Hrebinko RL. Circumferential laser vaporization for severe meatal stenosis secondary to balanitis xerotica obliterans. J Urol 1996; 156: 1735-6.
13. Parkash S, Gajendran V. Meatoplasty for gross urethral strictures: a technique of repair and a review of 32 cases. Br J Urol 1986; 136: 436-7.
14. Rudolph R, Wather P. Full-thickness skin grafts from eyelids to penis, plus split-thickness grafts in chronic balanitis xerotica obliterans. Ann Plast Surg 1997; 38: 173-6.