

# Fuchs' Heterochromic Uveitis Associated with Usher Syndrome: Case Report

## Usher Sendromu ile İlişkili Fuchs Heterokromik Üveiti

Nesrin BÜYÜKTORTOP,<sup>a</sup>  
Kemal ÖRNEK,<sup>a</sup>  
Elif İnci ERBAHÇECİ,<sup>a</sup>  
Zafer ONARAN,<sup>a</sup>  
Reyhan OĞUREL<sup>a</sup>

<sup>a</sup>Department of Ophthalmology,  
Kırıkkale University Faculty of Medicine,  
Kırıkkale

Geliş Tarihi/Received: 10.05.2012  
Kabul Tarihi/Accepted: 11.09.2012

Yazışma Adresi/Correspondence:  
Nesrin BÜYÜKTORTOP  
Kırıkkale University Faculty of Medicine,  
Department of Ophthalmology, Kırıkkale,  
TÜRKİYE/TURKEY  
tortopn@yahoo.com

**ABSTRACT** Fuchs' heterochromic uveitis (FHU) and Usher syndrome (US) are both rare disorders and so is their co-existence. There is no clear evidence for the pathophysiology of this association although there are some immunological explanations. In this paper we report a bilateral FHU case in a patient with US in order to draw attention to this rare co-existence for further research on probable autoimmune pathways common between these different clinical entities. So far 18 FHU cases co-existing with retinitis pigmentosa have been described in the literature, 6 of them being US. Our report, presenting the seventh case with co-existing FHU and US contributes the literature by emphasizing this relationship.

**Key Words:** Retinitis pigmentosa; Usher syndromes; uveitis

**ÖZET** Fuchs heterokromik üveiti (FHÜ) ve Usher sendromu (US) nadir görülen bozukluklar oldukları için birliktelikleri de nadirdir. Bazı immünolojik açıklamalar mevcut olmasına rağmen bu birlikteliğin patofizyolojisine dair açık kanıt bulunmamaktadır. Bu yazıda, bu iki farklı klinik durumun olası ortak otoimmün mekanizmaları üzerine daha ileri araştırmalar yapılması için bu nadir birlikteliğe dikkat çekmek amacıyla Usher sendromlu bir hastada bilateral Fuchs heterokromik üveiti olgusu bildirmektediriz. Literatürde bugüne kadar, 6'sı US olmak üzere, retinitis pigmentosa ile birlikte bulunan 18 FHÜ olgusu bildirilmiştir. Yazımız, FHÜ ve US'nin birarada bulunduğu yedinci vakayı sunmakla, bu ilişkiye vurgu yaparak literatüre katkıda bulunmaktadır.

**Anahtar Kelimeler:** Retinitis pigmentosa; Usher sendromları; üveit

**Türkiye Klinikleri J Ophthalmol 2013;22(1):55-9**

**R**etinitis pigmentosa (RP) is a clinically and genetically heterogeneous group of inherited retinal degenerations characterized by diffuse progressive dysfunction of predominantly rod photoreceptors, with subsequent degeneration of cone photoreceptors, and cellular loss and atrophy of the retinal tissue.<sup>1</sup> Visual impairment usually manifest as night blindness (nyctalopia) and progressive visual field loss. RP may be seen in isolation or in association with systemic diseases. Hearing loss is present in 10% of all retinitis pigmentosa cases and the most common cause of combined deafness and blindness is Usher syndrome (US).<sup>1</sup> US is characterized by sensorineural hearing loss and visual loss due to the progressive retinal degeneration termed retinitis pigmentosa. Its prevalence is about 4/100 000.<sup>1</sup> The age of onset, rate of progression, and severity of

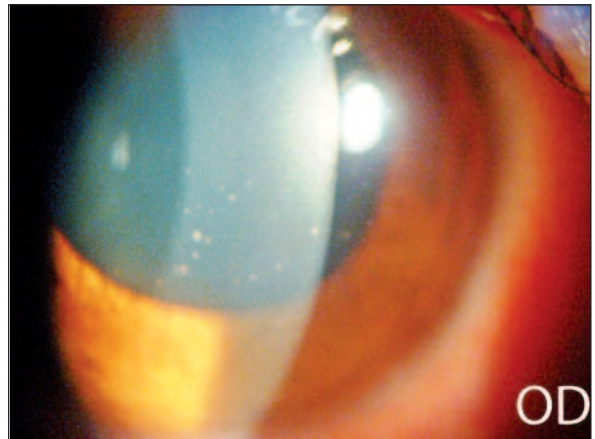
symptoms distinguish three clinical types, all manifesting combined dual sensory impairment of the audiovestibular and visual systems. Type 1 US is characterized by congenital, severe-to-profound deafness, and absent vestibular function. Type 2 shows congenital moderate-to-severe hearing loss, nyctalopia with late childhood onset and normal vestibular response. Type 3 includes progressive hearing loss starting in late childhood, nyctalopia in early adulthood with vestibular responses deteriorating later in life.<sup>1,2</sup>

Fuchs' heterochromic uveitis (FHU) is a chronic, nongranulomatous, relatively mild form of uveitis of unknown origin.<sup>3</sup> In the literature FHU has been reported to be associated with toxoplasmosis, viral diseases, sarcoidosis and rarely with RP.<sup>3,4</sup>

In this paper we report a case of bilateral FHU in a patient with US type 2.

## CASE REPORT

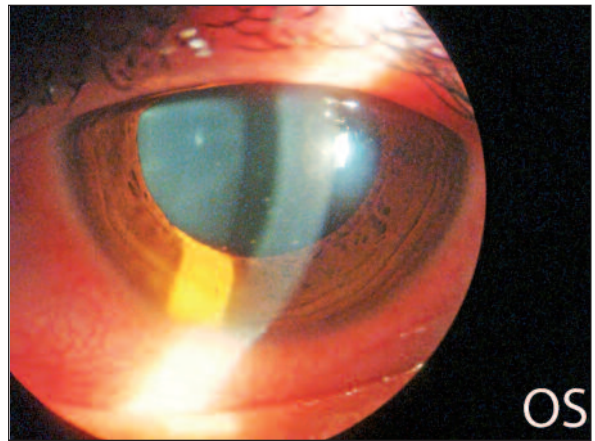
A 17-year-old boy presented to our clinic with gradually decreased visual acuity in both eyes. He had nyctalopia since childhood and hearing loss since birth. Audiometry and tympanometry tests demonstrated bilateral moderate sensorineural hearing loss. He had no vestibular problems, ataxia, musculoskeletal problems, external ophthalmoplegia, ptosis, polydactily or obesity. On ophthalmological examination best corrected visual acuities were 5/10 in the right and 6/10 in the left eye, respectively. Slit lamp biomicroscopy showed small-medium sized, round endothelial keratic precipitates, mild anterior chamber reaction, very mild posterior subcapsular cataract and moderate anterior vitreous condensation in both eyes (Figures 1, 2). Fundus examination revealed bony specules in both eyes (Figures 3, 4). Peripheral retina and ora serrata examination by Goldmann three mirror lens ruled out snowbanking. Gonioscopy showed no vascular abnormality in the angle. There was no anterior or posterior synechia in either eye. There was no heterochromia, but very tiny and scarce atrophic areas on both irises. Intraocular pressures were 9 mmHg in both eyes by Goldmann applanation tonometry. Fundus flu-



**FIGURE 1:** Anterior segment photography of the right eye showing keratic precipitates.

OD: Right eye.

(See for colored form <http://oftalmoloji.turkiyeklinikleri.com/>)

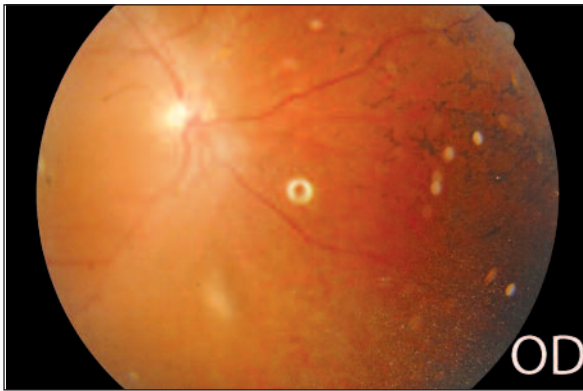

**FIGURE 2:** Anterior segment photography of the left eye showing keratic precipitates.

OS: left eye.

(See for colored form <http://oftalmoloji.turkiyeklinikleri.com/>)

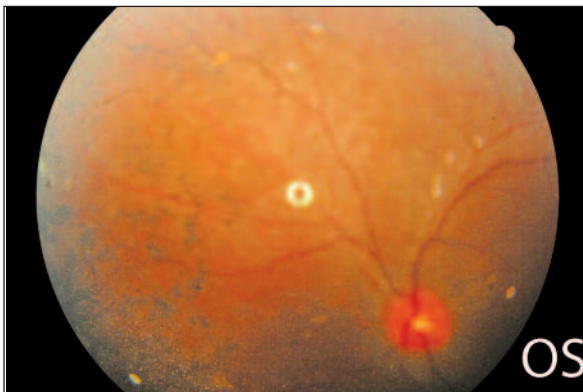orescein angiography and optical coherence tomography did not reveal any macular edema or vasculitis. With the informed consent of the patient a diagnostic work-up, including erythrocyte sedimentation rate, complete blood count, tuberculin skin testing, chest radiography, angiotensin-converting enzyme assay, syphilis, toxoplasma, rubella serologies, and magnetic resonance imaging of the brain and spinal cord were performed, and with providing normal results the work-up ruled out other possible infectious or noninfectious causes of uveitis.



**FIGURE 3:** Fundus photography of the right eye showing bony specules.

OD: Right eye.

(See for colored form <http://oftalmoloji.turkiyeklinikleri.com/>)



**FIGURE 4:** Fundus photography of the left eye showing bony specules.

OS: Left eye.


(See for colored form <http://oftalmoloji.turkiyeklinikleri.com/>)

The electroretinogram showed a reduction and delay in all rod and cone responses bilaterally, besides a diffuse loss in peripheral responses in both eyes in multifocal electroretinogram (Figures 5-8).

On the basis of these findings the diagnoses of bilateral FHU and US type 2 were made. Topical corticosteroid treatment was initiated for mild anterior chamber reaction which then resolved in few weeks. Vitreous condensation also resolved slowly during the 10 month follow-up period. At the last visit best corrected visual acuities were 7/10 in both eyes. Our patient did not require surgery because the cataract formation was very mild and it did not decrease visual acuity enough to restrict daily activities.

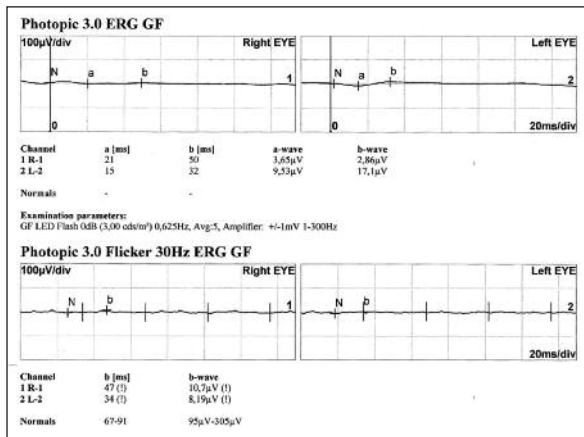
## DISCUSSION

FHU diagnosis is made on clinical features such as diffuse small to medium sized keratic precipitates; chronic low grade anterior chamber reaction; diffuse iris stromal atrophy with or without heterochromia; lack of posterior synechia, cystoid macular edema, retinal vasculitis, snowbanks, chorioretinal infiltrates despite the presence of vitreous cells and debris.<sup>5</sup> In a cross sectional and longitudinal study of FHU including 172 cases from Turkey, medium sized round keratic precipitates and iris nodules were reported to be more common and heterochromia was less frequent, besides subtle iris changes without obvious depigmentation and vitreous opacities in the absence of macular edema were reported to be more useful clues to the diagnosis than heterochromia.<sup>5</sup> It is also reported that diffuse stromal atrophy of the iris could be identified only in patients with unilateral involvement and there was no iris atrophy with or without heterochromia in approximately 12% of cases in that study. Heterochromia was absent in our case probably due to bilaterality and dark iris colours.

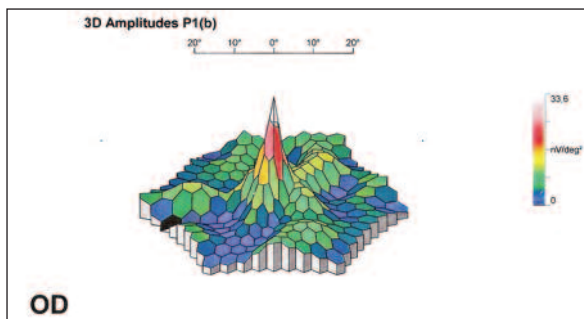


**FIGURE 5:** Scotopic ERG demonstrating reduction and delay in all rod and cone responses bilaterally.

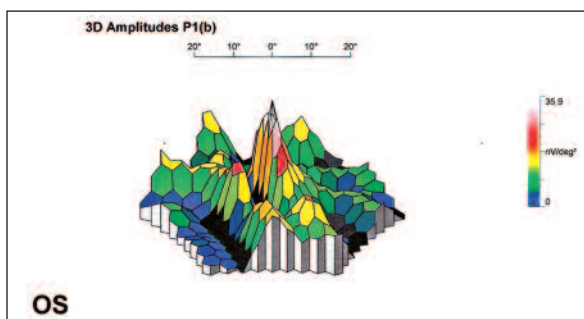
ERG: Electroretinogram.



**FIGURE 6:** Photopic ERG demonstrating reduction and delay in all rod and cone responses bilaterally.  
ERG: Electroretinogram.



**FIGURE 7:** Multifocal ERG demonstrating a normal central response but diffuse loss in peripheral responses in the right eye.  
OD: Right eye; ERG: Electroretinogram.  
(See for colored form <http://oftalmoloji.turkiyeklinikleri.com/>)



**FIGURE 8:** Multifocal ERG demonstrating a normal central response but diffuse loss in peripheral responses in the left eye.  
OS: Left eye; ERG: Electroretinogram.  
(See for colored form <http://oftalmoloji.turkiyeklinikleri.com/>)

bution in the inferior cornea in some cases.<sup>6</sup> Likewise, keratic precipitates were mostly located in the inferior cornea in our case. With small to medium sized keratic precipitates, low grade anterior chamber reaction, subtle iris changes, mild posterior subcapsular cataract, lack of posterior synechiae, and absence of cystoid macular edema, retinal vasculitis or snowbanks despite the presence of anterior vitreous condensation and with the exclusion of other etiologies we concluded that our patient had FU. Lichtinger et al. reported that FHU incidence was statistically significantly higher in RP group than the control group, when the data of two studies from their institute were merged.<sup>4</sup> In their study there was only one case of FHU in a control group of 2600 patients from the primary care ophthalmic clinic whereas 6 patients were diagnosed as FHU in a cohort of 396 RP cases. Moreover the difference between the incidence of FU in patients with US and in other types of RP was statistically significant. Namely, there was only one FU in 173 RP simplex cases whereas 5 FU in 37 US cases. Therefore, besides confirming the association between FU and RP, they claimed that there is a stronger association between FU and US.

Till today 18 FHU cases co-existing with RP have been described in the literature.<sup>4,7</sup> Only 2 of the cases were bilateral. In 6 of those 18 cases, RP types were US.<sup>4,7</sup> Our case, reporting the seventh patient with co-existing FHU and US contributes the literature by emphasizing this relationship. This rare but significant association between FHU and RP, particularly US, may be related to proposed common autoimmune pathways described below. The inflammatory activity in RP and FHU have the similarity in being low grade and chronic. Autoimmune reactions to a rod outer segment protein, namely retinal S-antigen have been accused in the pathogenesis of various forms of uveitis and hereditary retinal degeneration.<sup>4</sup> Particularly, S-antigen reactivity was found in both RP and FHU patients in separate studies.<sup>8,9</sup> This S-antigen reactivity was 15% in RP and 80% in US, conspicuously.<sup>8</sup> La Hey et al. reported that a significantly higher percentage of patients with FHU had a positive cellular autoimmune response to S-antigen

The distribution of keratic precipitates over the entire corneal endothelium is pathognomonic for FU, but also they may have a triangular distri-



than healthy controls and other patients with anterior uveitis.<sup>9</sup> Those immunological studies support the clinical association between FHU and US reported in the literature. Based on those literatures, it can be suggested that peripheral retina should be examined carefully for bony specules in

patients with FHU as well as the anterior chamber for uveitic findings in RP patients. We hope that this case report encourages further molecular studies to fully enlighten the probable common pathophysiological mechanisms underlying these diseases.

## REFERENCES

1. Or M, Subaşı M. [Retinitis pigmentosa and allied diseases]. *Türkiye Klinikleri J Ophthalmol-Special Topics* 2009;2(1):1-11.
2. Saihan Z, Webster AR, Luxon L, Bitner-Glindzic M. Update on Usher syndrome. *Current Opinion in Neurology* 2009;22(1):19-27.
3. Wang RC, Rao NA. Idiopathic and other anterior uveitis syndromes. In: Yanoff M, Duker JS, eds. *Ophthalmology*. 2<sup>nd</sup> ed. St. Lois: Mosby; 2004. p.1210.
4. Lichtinger A, Chowers I, Amer R. Usher syndrome associated with Fuchs' heterochromic uveitis. *Graefes Arch Clin Exp Ophthalmol* 2010;248(10):1481-5.
5. Tugal-Tutkun I, Güney-Tefekli E, Kamaci-Duman F, Corum I. A cross-sectional and longitudinal study of Fuchs uveitis syndrome in Turkish patients. *Am J Ophthalmol* 2009; 148(4):510-5.
6. Livir-Ratlos C. Fuchs' heterochromic iridocyclitis. In: Foster CS, Vitale AT, eds. *Diagnosis and Treatment of Uveitis*. 1<sup>st</sup> ed. Philadelphia: Saunders; 2002.p.693-700.
7. Turan-Vural E, Torun-Acar B, Tükenmez N, Sevim MŞ, Buttanri B, Acar S. Usher syndrome associated with Fuchs' heterochromic uveitis: a case report. *Clin Ophthalmol* 2011;5(1): 557-9.
8. Newsome DA, Nussenblatt RB. Retinal S antigen reactivity in patients with retinitis pigmentosa and Usher's syndrome. *Retina* 1984;4(3): 195-9.
9. La Hey E, Broersma L, van der Gaag R, Baarsma GS, Rothova A, Kijlstra A. Does autoimmunity to S-antigen play a role in Fuchs' heterochromic cyclitis? *Br J Ophthalmol* 1993; 77(7):436-9.