

# Atypical Presentation of a Familial Mediterranean Fever Case: Case Report

## Atipik Prezantasyonlu Ailesel Akdeniz Ateşi Olgusu

Havva ÖZTÜRK,<sup>a</sup>  
Figen TUNCAY,<sup>a</sup>  
Himmet DURMAZ<sup>b</sup>

<sup>a</sup>Department of  
Physical Medicine and Rehabilitation,  
Ahi Evran University Faculty of Medicine,  
Kırşehir

<sup>b</sup>Department of Internal Medicine,  
Hacettepe University Faculty of Medicine,  
Ankara

Geliş Tarihi/Received: 19.01.2017

Kabul Tarihi/Accepted: 14.04.2017

Yazışma Adresi/Correspondence:

Havva ÖZTÜRK  
Ahi Evran University Faculty of Medicine,  
Department of Physical Medicine and  
Rehabilitation, Kırşehir,  
TURKEY/TÜRKİYE  
havvaoturk4006@gmail.com

**ABSTRACT** Familial Mediterranean Fever (FMF) is characterized by recurrent polyserositis attacks and often accompanied by fever. After abdominal pain, the joint involvement is the most common manifestation. Chronic arthritis and sacroiliitis resulting in hip joint injury can be seen in FMF. In this report a case with an unusual presentation of FMF with inflammatory prolonged hip pain is presented by reviewing the current literature.

**Keywords:** Familial mediterranean fever; biological agents; arthritis

**ÖZET** Ailesel Akdeniz ateşi (AAA), sıklıkla ateşin eşlik ettiği, tekrarlayan serözit ataklarıyla karakterizedir. Eklem karın ağrısından sonra en sık tutulan ikinci bölgedir. Kalça ekleminde hasara yol açan kronik artrit veya sakroiliit görülebilir. Bu olgu raporunda inflamatuvar kalça ağrısı ile prezente olan AAA olgusu güncel literatür eşliğinde sunulmuştur.

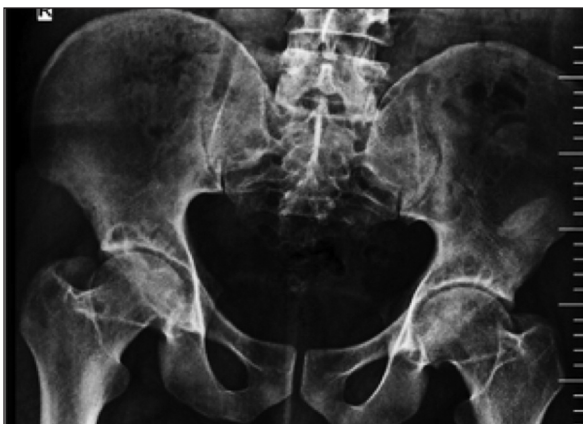**Anahtar Kelimeler:** Ailesel akdeniz ateşi; biyolojik ajanlar; artrit

Familial Mediterranean Fever (FMF) is an autosomal recessive systemic autoinflammatory disease with recurrent serositis episodes often accompanied with fever.<sup>1-4</sup> We postulate to underline a rare clinical form of FMF which manifests itself with prolonged hip pain. Herein, we report a patient with protracted hip arthritis who had an early response to infliximab therapy.

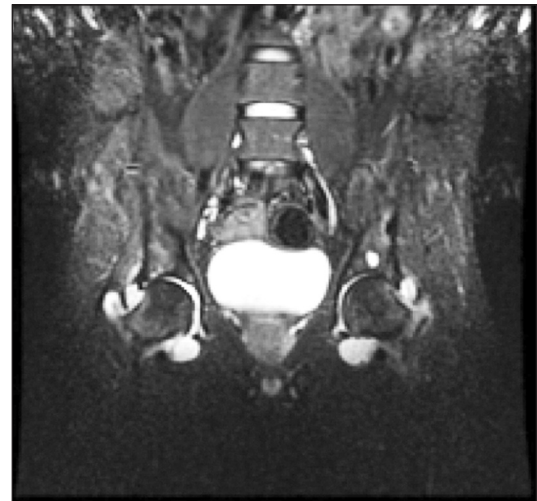
### CASE REPORT

Twenty-seven year old male patient applied to the outpatient clinic for pain in buttocks and both legs. He said that the pain existed for a few months and progressed during that time. During the physical examination the straight leg raise test was 50 degree positive on the right. C-reactive protein (CRP) in the laboratory tests was 1.52 mg/dl (normal range 0.015-0.50 mg/dl). Except from the high level of CRP, there were no positive laboratory findings. The family history for rheumatic diseases was negative. The lumbar, chest radiograph and urinalysis were normal. Anti-inflammatory drug was prescribed and the patient was called for control exami-

nation. At the follow-up he had pain in his left hip. His pain had inflammatory features. Bilateral range of motion in hip joint, especially the internal and external rotation, was limited in physical examination. The sacroiliac joint (SIJ) examination tests were bilateral positive. The hip radiography showed flattening of the bilateral femoral head and acetabular subchondral cysts (Figure 1). CRP levels were 7.9 mg/dl and proteinuria (1+) was present in the urinalysis. After learning more about the history of the patient it was revealed that he had an appendectomy. He didn't describe oral or genital aphthae, uveitis, genital discharge, skin rash, previously occurrence of joint pain and swelling, weight loss, night sweating, chest or abdominal pain, fever, dry eyes. A first-degree consanguineous marriage between his mother and father was present. The bilateral hip magnetic resonance imaging (MRI) was consistent with chronic sequelae of arthritis (Figure 2). The sacroiliac MRI and abdominal ultrasonography (USG) were normal. The fibrinogen levels were 74 mg/dl (normal range 180-350 mg/dl). The HLA-analysis revealed a positive HLA-B51. The V726A was heterozygous in the FMF gene analysis. Pathergy skin test was negative. With the current situation the patient was diagnosed as FMF and colchicine, sulphasalazine and non-steroidal anti-inflammatory drugs (NSAIDs) were initiated. In the follow-up, the CRP value regressed to 2.5 mg/dl. The micro-protein in the 24-hour urine



**FIGURE 1:** Acetabular subchondral cysts and subchondral sclerosis increase are observed in both hip joints, the AP graphy pelvic.



**FIGURE 2:** The hip MRI T2 Coronal Sections. Effusion in both Hip Joint. Millimetric subchondral cysts in the left acetabulum. Sequelae of chronic arthritis.

analysis was 178 mg/day (normal range <150 mg/day). However, he still had pain without NSAIDs. Based upon the inadequate clinical response, infliximab therapy was initiated. After the first use the patient showed a clinical and laboratory improvement. He initially received 3 doses of infliximab and he required subsequent infusions approximately every 8 weeks.

## DISCUSSION

FMF may present in various clinical situations. Diagnosis is based on clinical features. The most common complaints are recurrent abdominal pain and fever episodes.<sup>2</sup> Abdominal pain may be misdiagnosed as acute abdomen. Diagnosis of 30-40% of the patients is skipped and appendectomy is carried out, as it was the case with our patient.<sup>5</sup> Arthritis is often found in FMF. Although arthritis is commonly seen together with attacks, it can sometimes be the first finding of FMF. The typical involvement is monoarthritis in the lower extremity joints, which is not migratory and doesn't cause sequela. Although very rare it can proceed with chronic arthritis or sacroiliitis and cause damage to hip joint.<sup>6</sup> Chronic hip joint involvement is characterized with repetitive or prolonged attacks. Limitation of range of motion in the joint is very common, but the degree of functional impairment is variable. Changes in radiolu-

cent appearance suggesting avascular necrosis in the form of subchondral eggshell have been reported. This appearance was also present in the direct radiography of our patient.<sup>7,8</sup> FMF can also be associated with other diseases causing hip involvement. In the ten case series published by Younes et al. (hip involvement was shown radiologically in all patients), four patients showed isolated FMF, four patients ankylosing spondylitis (AS), one patient possible AS and one patient juvenile idiopathic arthritis (JIA), accompanied by FMF.<sup>9</sup> Cattan et al. reported cases of FMF together with chronic inflammatory bowel disease.<sup>10</sup> We excluded other inflammatory diseases that could occur together with FMF in our patient. The most important therapeutic agent for the disease is colchicine. It brings full remission in 65% and partial remission in 30% of the patients.<sup>11-13</sup> However, there are cases in literature with progressive chronic hip involvement which do not respond to colchicine treatment and warrant biological agents. Daysal et al. described a twenty-one year old woman with chronic hip involvement, not responsive to colchicine and NSAIDs. Other disease modifying anti-rheumatoid drugs (DMARDs) were prescribed but clinical response was not attained. Then the patient was started on intravenous infliximab treatment. Four-five days after

the infliximab treatment, the sedimentation and CRP values of the patient returned to normal. This case supports the role of TNF alpha in pathogenesis. In some reports TNF treatment was found to be ineffective.<sup>14</sup> Since our patient had no response to colchicine, NSAIDs and DMARDs, we started an anti-TNF (infliximab) treatment. Improvement of the clinical condition and the laboratory values was observed after the first dose.

In conclusion, Familial Mediterranean Fever should be kept in mind in patients with chronic hip arthritis. Significant results may be obtained with biological drugs (such as anti-TNF) in the treatment of these patients.

### Conflict of Interest

Authors declared no conflict of interest or financial support.

### Authorship Contributions

**Conception and Design of Research:** Havva Öztürk, Figen Tuncay, Himmet Durmaz; **Performed Experiments:** Havva Öztürk, Figen Tuncay, Himmet Durmaz; **Analyzed Data:** Havva Öztürk, Figen Tuncay, Himmet Durmaz; **Interpreted Results of experiments:** Havva Öztürk, Figen Tuncay, Himmet Durmaz; **Prepared Figures:** Havva Öztürk, Figen Tuncay, Himmet Durmaz; **Drafted Manuscript:** Havva Öztürk, Figen Tuncay, Himmet Durmaz; **Edited and Revised Manuscript:** Havva Öztürk, Figen Tuncay, Himmet Durmaz; **Approved Final Version of Manuscript:** Havva Öztürk, Figen Tuncay, Himmet Durmaz.

## REFERENCES

- Örün E, Yalçinkaya F. [Familial Mediterranean fever and amiloidosis in Turkish medicine]. Official Journal of the Turkish Society of Nephrology 2003;12(1):1-7.
- Tunca M, Akar S, Onen F, Ozdogan H, Kasapcopur O, Yalçinkaya F, et al; Turkish FMF Study Group. Familial Mediterranean fever (FMF) in Turkey; results of a nationwide multicenter study. Medicine (Baltimore) 2005;84(1):1-11.
- Düzova A, Özen S. [Clinical features and diagnosis of familial Mediterranean fever]. Türkiye Klinikleri J Int Med Sci 2006;2(8):12-20.
- Birsin Özçakar Z, Yalçinkaya F. [Familial Mediterranean fever in childhood]. Türkiye Klinikleri J Int Med Sci 2006;2(8):46-50.
- Livneh A, Langevitz P, Zemer D, Padeh S, Migdal A, Sohar E, et al. The changing of familial Mediterranean fever. Semin Arthritis Rheum 1996;26(3):612-27.
- Mor A, Gal R, Livneh A. Abdominal and digestive system associations of familial Mediterranean fever. Am J Gastroenterol 2003;98(12):2594-604.
- Özdoğan H, Arisoy N, Kasapçapur O, Sever L, Çalışkan S, Tuzuner N, et al. Vasculitis in Familial Mediterranean fever. J Rheumatol 1997;24(2):323-7.
- Ergüven M, Üçel R, Cebeci N, Pelit M. [Demographical, clinical and genetical features and responses to treatment of 120 cases with familial Mediterranean fever: single center experience]. Çocuk Sağlığı ve Hastalıkları Dergisi 2006;49(4):283-90.
- Younes M, Kahn MF, Meyer O. Hip involvement in patients with familial Mediterranean fever. A review of ten cases. Joint Bone Spine 2002;69(6):560-5.
- Cattan D, Notarnicola C, Molinari N, Toitou I. Inflammatory bowel disease in non-Ashkenazi Jews with familial Mediterranean fever. Lancet 2000;355(9201):378-9.
- Heller H, Gafni J, Michaeli D, Shahin N, Sohar E, Ehrlich G, et al. The arthritis of familial Mediterranean fever (FMF). Arthritis Rheum 1966;9(1):1-17.
- Ben-Chetrit E, Levy M. Familial Mediterranean fever. Lancet 1998;351(9103):659-64.
- Zemer D, Livneh A, Danon YL, Pras M, Sohar E. Long term colchicine treatment in children with familial Mediterranean fever. Arthritis Rheum 1991;34(8) 973-7.
- Daysal S, Akcil G, Goker B, Haznedaroglu S, Ercan N, Ozturk MA. Infliximab therapy in a patient with familial Mediterranean fever and chronic hip arthritis. Arthritis Rheum 2005;53(1):146-7.