

## CASE REPORT

DOI: 10.5336/caserep.2024-105608

# Niraparib-Associated Pulmonary Embolism in a Patient with BRCA Mutant Ovarian Cancer

<sup>1</sup>Aysun Fatma AKKUŞ<sup>a</sup>, <sup>2</sup>Gökhan ÖZTÜRK<sup>a</sup>, <sup>3</sup>İsmail BAYRAKÇI<sup>a</sup>, <sup>4</sup>Bülent ERDOĞAN<sup>a</sup>,  
<sup>5</sup>Muhammet Bekir HACIOĞLU<sup>a</sup>, <sup>6</sup>Sernaz TOPALOĞLU<sup>a</sup>

<sup>a</sup>Trakya University Faculty of Medicine, Department of Internal Medicine, Department of Medical Oncology, Edirne, Türkiye

**ABSTRACT** Among the histological subtypes of ovarian cancer, high-grade serous ovarian carcinoma is the type most commonly associated with breast cancer 1/2 (BRCA1/2) mutations. The combination regimen of platinum and taxane is the first-line treatment for advanced ovarian cancer. Maintenance therapy with poli-ADP riboz polimeraz inhibitors (PARPi), with or without bevacizumab, is recommended for patients with BRCA1/2-wt/homologous recombination deficiency-positive or BRCA1/2 mutations tumors who achieve a complete or partial response to first-line platinum-paclitaxel chemotherapy following the completion of chemotherapy. The most common side effects associated with the use of PARPi are hematologic toxicities. In our case, we aim to present a rare case of pulmonary thromboembolism associated with approximately 23 months of niraparib use. Pulmonary thromboembolism should be considered in patients with respiratory symptoms when prescribing PARPi.

**Keywords:** PARP inhibitors; pulmonary embolism; ovarian neoplasms

Among the histological subtypes of ovarian cancer, high-grade serous ovarian carcinoma is the type most commonly associated with breast cancer 1/2 (BRCA1/2) mutations.<sup>1</sup> The combination regimen of platinum and taxane is the first-line treatment for advanced ovarian cancer.<sup>2</sup> Maintenance therapy with poli-ADP riboz polimeraz inhibitors (PARPi), with or without bevacizumab, is recommended for patients with BRCA1/2-wt/homologous recombination deficiency-positive or BRCA1/2 mutations tumors who achieve a complete or partial response to first-line platinum-paclitaxel chemotherapy following the completion of chemotherapy.<sup>3</sup> The most common side effects of PARPi are hematological toxicity and gastrointestinal side effects, which are generally manageable. We present a rare case of pulmonary embolism associated with niraparib in a patient with

high-grade serous ovarian carcinoma who has been on niraparib for approximately twenty three months.

## CASE REPORTS

A 63-year-old female patient was diagnosed with triple-negative breast cancer in 2013 and received adjuvant therapy. During follow-up, 8 years after the initial diagnosis, elevated CA 125 levels of 1946 U/mL (normal range: 0-35) and CA 15-3 levels of 300 U/mL (normal range: 0-26) were detected. Further investigations revealed intra-abdominal implants, leading to suboptimal debulking surgery. The patient was diagnosed with high-grade serous ovarian carcinoma. The patient received platinum-based chemotherapy as first-line treatment, achieving a partial response. Maintenance therapy with a PARPi was

**Correspondence:** Aysun Fatma AKKUŞ

Trakya University Faculty of Medicine, Department of Internal Medicine, Department of Medical Oncology, Edirne, Türkiye

**E-mail:** aysunfatmadogan@gmail.com



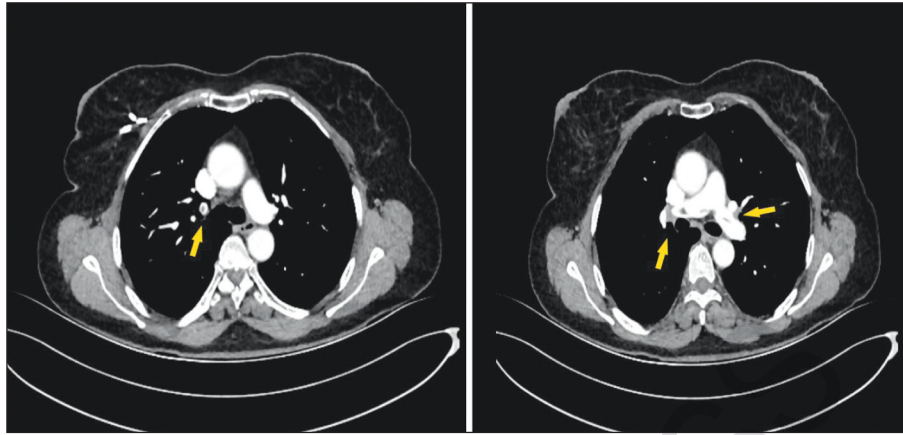
Peer review under responsibility of Türkiye Klinikleri Journal of Case Reports.

**Received:** 16 Sep 2024

**Accepted:** 02 Feb 2025

**Available online:** 21 Mar 2025

2147-9291 / Copyright © 2025 by Türkiye Klinikleri. This is an open access article under the CC BY-NC-ND license (<http://creativecommons.org/licenses/by-nc-nd/4.0/>).



**FIGURE 1:** Filling defect consistent with embolism extending from both main pulmonary arteries to the right upper lobar and segmental branches, as well as the left lower lobar and segmental branches

planned due to the detection of a BRCA2 germline mutation. Two months after completing chemotherapy, treatment with niraparib was initiated at a dose of 200 mg once daily, resulting in a complete response. Twenty three months after starting niraparib, a routine chest computed tomography scan revealed filling defects in both main pulmonary arteries consistent with pulmonary embolism. The patient's D-dimer level was elevated at 1.11 mg/L (0-0.55), and imaging findings were consistent with embolism (Figure 1), leading to a diagnosis of niraparib-associated pulmonary embolism. Doppler ultrasound revealed deep vein thrombosis in the right lower extremity. We paused niraparib treatment for 2 weeks and initiated anticoagulant therapy. During follow-up and treatment, no symptoms of pulmonary embolism were observed.

Informed consent was obtained from the patients for the publication of the case image and accompanying images.

## DISCUSSION

The standard treatment for ovarian cancer includes maximum debulking surgery followed by 6 cycles of platinum-paclitaxel combination chemotherapy. The recurrence rate is high in these patients. The 5-year overall survival rate for patients diagnosed with advanced ovarian cancer is between 26% and 42%.<sup>4</sup> PARPi play a role in the repair of single-strand DNA

breaks and in transcription regulation. PARPi represent a new treatment option for cancers known to have underlying mechanisms of DNA repair deficiencies, such as ovarian cancer.<sup>5</sup> Niraparib, olaparib, and rucaparib are approved for maintenance therapy in platinum-sensitive advanced ovarian cancer patients and significantly prolong progression-free survival.

Among the PARPi options, olaparib is typically administered at 300 mg twice daily (every 12 hours), and niraparib is given once daily at 200-300 mg. Due to the common side effect of thrombocytopenia, the initial dose of niraparib is determined based on platelet count and the patient's weight.

PARPi are associated with cardiovascular adverse events such as thromboembolic events, and pulmonary embolism. The pathogenesis of cardiac toxicity is unknown and is thought to be associated to off-target effects involving the inhibition of non-target proteins.<sup>6</sup> Niraparib is most frequently related to hypertension and cardiovascular toxicity.<sup>7</sup>

Niraparib may interfere with dopamine and norepinephrine metabolism through off-target effects.<sup>7,8</sup> It inhibits the intracellular uptake of dopamine and norepinephrine by blocking the dual-specificity tyrosine phosphorylation-regulated kinase 1A. This leads to increased levels of these neurotransmitters, which can cause hypertension due to their positive inotropic effects on the heart.<sup>7-9</sup>

By Palazzo et al. PARPi-based therapies were related to a higher risk of any grade of pulmonary embolism compared to controls [fixed-effects model, RR=1.69, 95% Confidence interval (CI) 1.14-2.52; p=0.009].<sup>10</sup> In an analysis of nineteen studies including, the incidence of any grade of thromboembolic events was 2.6% in the control group, compared to 4.1% in the PARPi group. In the comparison between PARPi-based therapy and the control group, thromboembolic events were observed at a higher rate in the group receiving PARPi (Peto fixed-effects model, Peto OR=1.49, 95% CI 1.14-1.95; p=0.004).

PARP inhibitor-based therapies are thought to be related to an increased risk of major adverse cardiovascular events, hypertension, thromboembolic events, and pulmonary embolism.<sup>10</sup> Patient-specific risk factors (e.g., prior anthracycline-based chemotherapy or hormone therapy like tamoxifen in breast cancer, or high thromboembolic risk in pancreatic cancer) should be identified, and monitoring and control of these side effects should be taken into account.

In the patient receiving niraparib treatment, who showed an embolic defect on imaging, no underlying factors that could facilitate embolism such as active chemotherapy, recent surgery, infection, or immobilization were present. Therefore, niraparib-related pulmonary embolism was considered in our case. However, pulmonary embolism is not included among the known side effects or rare complications of niraparib. A similar case has been reported in the

literature, while the precise mechanism behind this remains unknown, it is important to consider the possibility of niraparib-associated pulmonary embolism in patients presenting with symptoms like shortness of breath and fatigue while on niraparib therapy.<sup>11</sup>

### Source of Finance

*During this study, no financial or spiritual support was received neither from any pharmaceutical company that has a direct connection with the research subject, nor from a company that provides or produces medical instruments and materials which may negatively affect the evaluation process of this study.*

### Conflict of Interest

*No conflicts of interest between the authors and / or family members of the scientific and medical committee members or members of the potential conflicts of interest, counseling, expertise, working conditions, share holding and similar situations in any firm.*

### Authorship Contributions

**Idea/Concept:** Aysun Fatma Akkuş, Sernaz Topaloğlu, Muhammet Bekir Hacıoğlu; **Design:** Aysun Fatma Akkuş, Bülent Erdoğan, Gökhan Öztürk; **Control/Supervision:** Aysun Fatma Akkuş, Sernaz Topaloğlu, Muhammet Bekir Hacıoğlu, Bülent Erdoğan; **Data Collection and/or Processing:** Aysun Fatma Akkuş, Gökhan Öztürk, İsmail Bayrakçı; **Analysis and/or Interpretation:** Aysun Fatma Akkuş, Muhammet Bekir Hacıoğlu, Gökhan Öztürk; **Literature Review:** Bülent Erdoğan, Sernaz Topaloğlu, Gökhan Öztürk; **Writing the Article:** Aysun Fatma Akkuş, Muhammet Bekir Hacıoğlu, Sernaz Topaloğlu; **Critical Review:** Muhammet Bekir Hacıoğlu, Bülent Erdoğan, Sernaz Topaloğlu; **Materials:** Gökhan Öztürk, İsmail Bayrakçı, Sernaz Topaloğlu.

## REFERENCES

1. Norquist BM, Brady MF, Harrell MI, Walsh T, Lee MK, Gulsuner S, et al. Mutations in homologous recombination genes and outcomes in ovarian carcinoma patients in GOG 218: an NRG oncology/gynecologic oncology group study. *Clin Cancer Res.* 2018;24(4):777-83. PMID: 29191972; PMCID: PMC5815909.
2. Högberg T, Glimelius B, Nygren P; SBU-group. Swedish Council of Technology Assessment in Health Care. A systematic overview of chemotherapy effects in ovarian cancer. *Acta Oncol.* 2001;40(2-3):340-60. PMID: 11441940.
3. Tew WP, Lacchetti C, Ellis A, Maxian K, Banerjee S, Bookman M, et al. PARP inhibitors in the management of ovarian cancer: ASCO guideline. *J Clin Oncol.* 2020;38(30):3468-93. PMID: 32790492; PMCID: PMC8942301.
4. Matulonis U, Herrstedt J, Oza A, Mahner S, Redondo A, Berton D, Mirza, M. Final overall survival and long-term safety in the ENGOT-OV16/NOVA phase III trial of niraparib in patients with recurrent ovarian cancer (LBA 6). *Gynecologic Oncology.* 2023;176:S31-S32. [https://medinfo.gsk.com/5f95dbd7-245e-4e65-9f36-1a99e28e5bba/9ee3958d-cd12-49fc-8a74-4796d7b46860/9ee3958d-cd12-49fc-8a74-4796d7b46860\\_viewable\\_rendition\\_\\_v.pdf](https://medinfo.gsk.com/5f95dbd7-245e-4e65-9f36-1a99e28e5bba/9ee3958d-cd12-49fc-8a74-4796d7b46860/9ee3958d-cd12-49fc-8a74-4796d7b46860_viewable_rendition__v.pdf)
5. Oza AM, Lisyanskaya A, Fedenko A, de Melo AC, Shparyk Y, Rakhmatullina I, et al. Rucaparib versus chemotherapy for treatment of relapsed ovarian cancer with deleterious BRCA1 or BRCA2 mutation (ARIEL4): final results of an international, open-label, randomised, phase 3 trial. *Lancet Oncol.* 2025;26(2):249-64. PMID: 39914419.
6. Tian X, Chen L, Gai D, He S, Jiang X, Zhang N. Adverse event profiles of PARP inhibitors: analysis of spontaneous reports submitted to FAERS. *Front Pharmacol.* 2022;13:851246. PMID: 35401230; PMCID: PMC8990839.
7. Mirza MR, Monk BJ, Herrstedt J, Oza AM, Mahner S, Redondo A, et al; ENGOT-OV16/NOVA Investigators. Niraparib maintenance therapy in platinum-sensitive, recurrent ovarian cancer. *N Engl J Med.* 2016;375(22):2154-64. PMID: 27717299.

- 
8. LaFargue CJ, Dal Molin GZ, Sood AK, Coleman RL. Exploring and comparing adverse events between PARP inhibitors. *Lancet Oncol.* 2019;20(1):e15-e28. PMID: 30614472; PMCID: PMC7292736.
  9. London J, Rouch C, Bui LC, Assayag E, Souchet B, Daubigney F, Medjaoui H, Luquet S, Magnan C, Delabar JM, Dairou J, Janel N. Overexpression of the DYRK1A gene (dual-specificity tyrosine phosphorylation-regulated kinase 1A) induces alterations of the serotonergic and dopaminergic processing in murine brain tissues. *Mol Neurobiol.* 2018;55(5):3822-31. PMID: 28540658.
  10. Palazzo A, Ciccarese C, Iacovelli R, Cannizzaro MC, Stefani A, Salvatore L, et al. Major adverse cardiac events and cardiovascular toxicity with PARP inhibitors-based therapy for solid tumors: a systematic review and safety meta-analysis. *ESMO Open.* 2023;8(2):101154. PMID: 36893518; PMCID: PMC10163166.
  11. Wei Q, Chen DS, Liu YH. Case report: niraparib-related pulmonary embolism during the treatment of BRCA mutant advanced ovarian cancer. *Front Oncol.* 2022;12:853211. PMID: 35359396; PMCID: PMC8960313.

ARTICLE IN PRESS