





## Treatment of Pyogenic Granuloma in A-7-month Old Infant with Timolol

 Mehmet ATAKAN<sup>a</sup>,  
 Tuğba GENÇAĞA ATAKAN<sup>a</sup>,  
 Mahmut Oğuz ULUSOY<sup>b</sup>,  
 Burcu TUĞRUL AYANOĞLU<sup>c</sup>

<sup>a</sup>Clinic of Ophthalmology,  
Sancaktepe Şehit Professor İlhan Varank  
Training and Research Hospital,  
İstanbul, TURKEY

<sup>b</sup>Başkent University Application and  
Research Center,  
Konya, TURKEY

<sup>c</sup>Clinic of Dermatology,  
Atatürk Training and Research Hospital,  
Ankara, TURKEY

Received: 24 Jan 2019

Received in revised form: 30 Jun 2019

Accepted: 02 Jul 2019

Available online: 03 Jul 2019

Correspondence:

Mehmet ATAKAN  
Sancaktepe Şehit Professor İlhan Varank  
Training and Research Hospital,  
Clinic of Ophthalmology,  
İstanbul, TURKEY  
dratakan@gmail.com

**ABSTRACT** Pyogenic granuloma (PG) is a tumor-like growth of the oral mucosa or skin that is considered to be an exaggerated response to minor trauma. It is usually painless and bleeds easily. This is considered to be a non-neoplastic vascular tumor located in different parts of the body (head, neck, face or finger etc.). It can be treated medically or with surgical methods like excision, curettage or laser treatments. Clinically, it is a smooth or lobulated exophytic lesion manifesting as small, red, erythematous papules on a pedunculated or sometimes sessile base that is usually hemorrhagic. Topical medical treatment includes topical imiquimod %5 and recently topical timolol %0.5 gel. Imiquimod may cause dermatitis or hypersensitivity reactions but the efficacy and safety of topical timolol has been recently described in the treatment of infantile hemangioma, a vascular tumor similar to pyogenic granuloma.

**Keywords:** Granuloma pyogenic; timolol

Here we report a 7 month old infant with a pyogenic granuloma on his filtrum (upper lip) treated with topical timolol %0.5 gel for 3 months and the lesion had completely resolved after treatment. No side effects or recurrence was reported at 6 months after treatment. In infants and young patients, timolol may be the first choice of treatment for small pyogenic granulomas especially located in face while considering less scarring with other modalities.

Topical timolol therapy seems to be effective and safe compared to the other modalities especially among young patients. Considerable interest in the use of beta blockers for vascular lesions started when Leaute-Labreze et al reported the efficacy of oral propranolol in the treatment of hemangiomas of infancy.<sup>1</sup> Studies on topical  $\beta$ -blockers, such as timolol, demonstrated a positive effect in the treatment of a subset of hemangiomas. Beta-adrenergic receptors on vascular endothelial cells cause peripheral vasodilation, activate proangiogenic factors such as vascular endothelial growth factor (VEGF) and basic fibroblast growth factor (bFGF), and inhibit endothelial cell apoptosis. Blocking these actions may help to explain the effectiveness of topical timolol in pyogenic granulomas. The variable effect and time to resolution of pyogenic granulomas treated with topical timolol may be explained by the fact that pyogenic granulomas have a weaker expression of three critical beta-adrenergic receptors.

## CASE REPORT

4 month old boy presented with a lesion on his filtrum (Figure 1). The lesion has been existing on filtrum for 2 months and it has been rapidly growing and bleeding easily with recurrent itching. Examination showed a 4 mm round-shaped reddish white papule on left side of the filtrum. Morphological appearance and clinical history was consistent with pyogenic granuloma. Because of the chance of spontaneous resolution of lesion, we initially decided to follow up without any treatment. After 3 months of follow up, no regression was observed in the lesion. Although different treatment methods like shave curettage, excision and reconstructive surgery or excision and cauterization of central vessel may be considered, the possibility of scarring and recurrence and the localization of the lesion has led us to commence topical timolol %0.5 gel therapy (Figure 2). Before we started treatment, medical consent was taken from the legal guardian of the patient and pictures were taken under his approval.

## DISCUSSION

We started timolol %0.5 gel solution twice a day, for 4 months despite the presence of no consensus on dosing, treatment bioavailability, or clinical assessment of lesions. The lesion was nearly completely resolved and left a minimal pigmented area with treatment (Figure 3). There was no recurrence recorded at 6 month after the treatment had discontinued (Figure 4).

Pyogenic granulomas or lobular capillary hemangiomas are one of the most common vascular tumors in childhood. Contrary to its name, pyogenic granuloma is not of granulomatous or infectious origin. It is more accurately referred to as lobular capillary hemangioma due to its characteristic histological appearance. The benign lesion is believed to form from rapidly growing capillary blood vessels, presenting clinically as a red shiny papule that bleeds easily. There are various locations for this lesion, head, neck, face and fingers. The vascular component makes easy to bleed even with gentle touch, and recurrence is also an im-

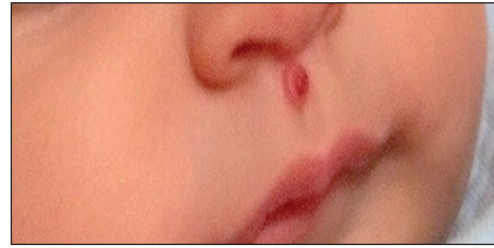


FIGURE 1: Month 4 (first examination).

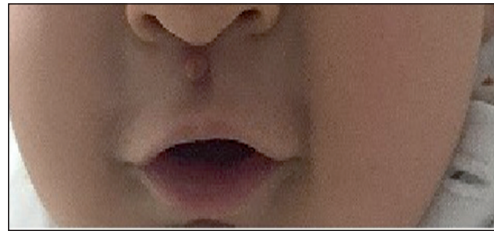


FIGURE 2: Month 7 (beginning of treatment).

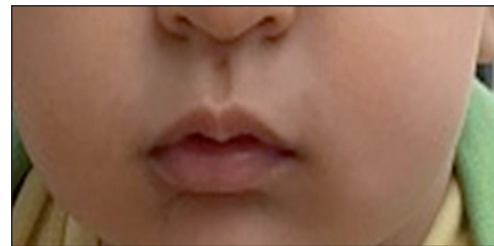

FIGURE 3: Month 11 (end of treatment).

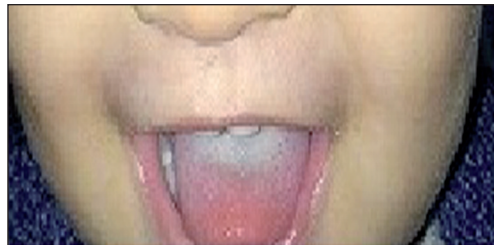


FIGURE 4: Month 17 (the last examination, no recurrence or scar).

portant problem with its high range.<sup>2</sup> Medical and surgical treatment options are available for this lesion. But with surgical choices like curettage, excision, laser, flap surgery scarring and unpleasant outcomes may exist after treatment. Especially when the lesion is on the face, scarring is always the most undesired complication for young patients.

Besides surgery, beta blockers are usually used to treat vascular tumors. Propranolol and timolol are two different options. This treatment

has two goals one is to create vasoconstriction and another is to prevent proinflammatory cytokines like FGF (fibroblast growth factor), VEGF (vascular endothelial growth factor) which promote new vessels. Oral propranolol (non-selective beta blocker) is used for hemangiomas in children.<sup>1</sup> But recently topical timolol has been favoured for treating vascular tumors like pyogenic granuloma.<sup>2</sup>

Timolol %0.5 gel is an appropriate choice for lesions located in face.<sup>3</sup> In literature, two different pyogenic granuloma cases treated with timolol gel were presented. Khorsand K et al. used timolol gel %0.5 for a 5 month-old baby who had pyogenic granuloma on his cheek.<sup>4</sup> They discontinued treatment after one month and didn't notice any recurrence after 8 months.<sup>4</sup> This case was similar to our patient with regard to age and gender but we used timolol gel twice a day for 4 months because the lesion had not resolved before. Similarly, we didn't observe any recurrence or side effects after 6 months.

Another case which was presented with pyogenic granuloma is a 14 year old child with a lesion in his index finger. The patient was treated with timolol gel, twice a day, for 3 weeks and the lesion completely resolved and no recurrence was observed after 7 months.<sup>5</sup>

There is no consensus on the dose regimen or the duration of treatment, but Wine et al. reported that treatment may require more than 6 weeks to observe long term effects of timolol which were related with angiogenic factors. They reported that regression on their patients continued after treatment had stopped. Similarly, we observed regression that continued after discontinuation of treatment.<sup>6</sup>

A multicenter retrospective cohort study of 731 patients treated with topical timolol was conducted by Püttgen et al. They assessed the outcomes from review of digital photographs and reported that timolol seems to be a well-tolerated, safe treatment option with moderate to good effectiveness, demonstrating best response in thin, superficial hemangiomas regardless of pretreatment

size. Timolol can be recommended as an alternative to systemic  $\beta$ -blockers and watchful waiting for many patients.<sup>7</sup>

In all of those cases, the lesions were not histopathologically confirmed as pyogenic granuloma. All diagnoses were based on history and clinical appearance. So this may be seen as a limitation of these studies but considering bleeding and unwanted outcomes of surgical interventions to this lesion, avoiding was probably the best option.

The outcomes of these studies including ours suggest that, in small pyogenic granulomas, particularly located in face, medical therapy with timolol can be considered as the first option for treatment. Although results are satisfying, long term studies conducted with large case series are needed to support our findings.

#### **Source of Finance**

*During this study, no financial or spiritual support was received neither from any pharmaceutical company that has a direct connection with the research subject, nor from a company that provides or produces medical instruments and materials which may negatively affect the evaluation process of this study.*

#### **Conflict of Interest**

*No conflicts of interest between the authors and / or family members of the scientific and medical committee members or members of the potential conflicts of interest, counseling, expertise, working conditions, share holding and similar situations in any firm.*

#### **Authorship Contributions**

**Idea/Concept:** Mehmet Atakan, Tuğba Genççağa Atakan, Mahmut Oğuz Ulusoy, Burcu Tuğrul Ayanoğlu; **Design:** Mehmet Atakan, Tuğba Genççağa Atakan; **Control/Supervision:** Mahmut Oğuz Ulusoy, Mehmet Atakan; **Data Collection and/or Processing:** Tuğba Genççağa Atakan, Burcu Tuğrul Ayanoğlu; **Analysis and/or Interpretation:** Mehmet Atakan, Mahmut Oğuz Ulusoy, Tuğba Genççağa Atakan; **Literature Review:** Mehmet Atakan, Tuğba Genççağa Atakan; **Writing the Article:** Mehmet Atakan, Tuğba Genççağa Atakan, Mahmut Oğuz Ulusoy; **Critical Review:** Burcu Tuğrul Ayanoğlu, Tuğba Genççağa Atakan; **References and Fundings:** Mehmet Atakan, Mahmut Oğuz Ulusoy; **Materials:** Mehmet Atakan, Tuğba Genççağa Atakan, Mahmut Oğuz Ulusoy.

## REFERENCES

1. Léauté-Labrèze C, Dumas de la Roque E, Hubiche T, Boralevi F, Thambo JB, Taïeb A. Propranolol for severe hemangiomas of infancy. *N Engl J Med*. 2008;358(24):2649-51. [[Crossref](#)] [[PubMed](#)]
2. Millsop JW, Trinh N, Winterfield L, Berrios R, Hutchens KA, Tung R. Resolution of recalcitrant pyogenic granuloma with laser, corticosteroid, and timolol therapy. *Dermatol Online J*. 2014;20(3). [[PubMed](#)]
3. Chakkittakandiyil A, Phillips R, Frieden IJ, Siegfried E, Lara-Corrales I, Lam J, et al. Timolol maleate 0.5% or 0.1% gel-forming solution for infantile hemangiomas: a retrospective, multicenter, cohort study. *Pediatr Dermatol*. 2012;29(1):28-31. [[Crossref](#)] [[PubMed](#)]
4. Khorsand K, Maier M, Brandling-Bennett HA. Pyogenic granuloma in a 5-month-old treated with topical timolol. *Pediatr Dermatol*. 2015;32(1):150-1. [[Crossref](#)] [[PubMed](#)]
5. Malik M, Murphy R. A pyogenic granuloma treated with topical timolol. *Br J Dermatol*. 2014;171(6):1537-8. [[Crossref](#)] [[PubMed](#)]
6. Wine Lee L, Goff KL, Lam JM, Low DW, Yan AC, Castelo-Soccio L. Treatment of pediatric pyogenic granulomas using  $\beta$ -adrenergic receptor antagonists. *Pediatr Dermatol*. 2014;31(2):203-7. [[Crossref](#)] [[PubMed](#)]
7. Püttgen K, Lucky A, Adams D, Pope E, McCuaig C, Powell J, et al. Topical timolol maleate treatment of infantile hemangiomas. *Pediatrics*. 2016;138(3). [[Crossref](#)] [[PubMed](#)]