

Foregut-Origin Ciliated Cyst of the Gallbladder

 Tamer AKAY^a

^aClinic of General Surgery,
Bandırma State Hospital,
Balıkesir, TURKEY

Received: 28.05.2018
Received in revised form: 28.09.2018
Accepted: 02.10.2018
Available online: 05.03.2019

Correspondence:
Tamer AKAY
Bandırma State Hospital,
Clinic of General Surgery,
Balıkesir, TURKEY
op.dr.tamerakay@gmail.com

ABSTRACT Foregut-origin ciliated cysts of the gallbladder are very rare, benign, cystic lesions, usually found incidentally under ultrasonography during surgical exploration or autopsy. We present a case that was found incidentally during an ultrasonographic examination in a man aged 69 years with chronic abdominal pain. Gallbladder stones and a benign-appearing cyst were revealed in the examination. We performed laparoscopic cholecystectomy with excision of the gallbladder cyst. The cyst wall consisted of discontinuous smooth muscle layers and a lining of pseudostratified ciliated columnar epithelium. There were no postoperative complications. The patient was discharged two days after the surgery and had no recurrence or lasting effects after 6 months. Foregut-origin ciliated cyst of the gallbladder is a rare, benign lesion; however, excision is recommended because there is a risk of malignant transformation.

Keywords: Cholecystectomy; gallbladder; cysts

Foregut-origin ciliated cysts origin may occur in relation to the tracheobronchial tree to upper digestive tract.¹ Ciliated foregut cysts are rare anomalies due to aberrant embryological development. It is thought to arise from a remnant of the embryologic foregut. The solitary cysts are characterised by ciliated pseudostratified columnar epithelium.^{2,3} Foregut cysts below the diaphragm usually occur in the liver.⁴ Herein, we present a case of foregut- origin ciliated cyst of the gallbladder.

CASE REPORT

A 69-year-old male patient was admitted to our hospital's surgical polyclinic with symptoms of abdominal pain, which he had had for the last 3 years. Tenderness of the right upper quadrant and Murphy's sign were present but rebound tenderness was not present in the physical examination. The results of laboratory examinations indicated normal alanine transaminase (ALT) and aspartate aminotransferase (AST) enzymes. Serologic tumor markers (AFP, CEA and CA19-9) and hepatitis B and C markers were negative. He was sent to the radiology clinic for ultrasonography (USG) of the abdomen, which revealed gallstones and a benign-appearing cystic lesion on the fundus of the gallbladder (Figure 1). A cystic structure adjacent to the gallbladder wall was found on abdominal computed tomography (CT) (Figure 2). The operation has been planned for the patient and admission to the service has been pro-

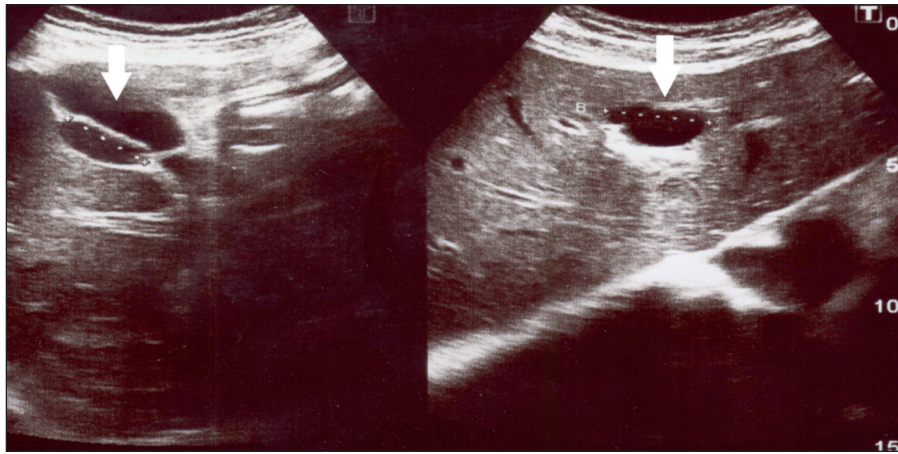


FIGURE 1: Preoperative imaging studies: Abdominal ultrasonography shows a benign-appearing cystic lesion on the fundus of the gallbladder.

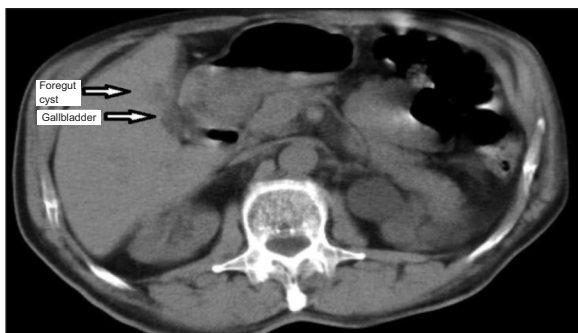


FIGURE 2: Computed tomography revealed a cystic structure adjacent to the gallbladder wall.

vided; and informed consent has been obtained from the patient and the patient has been taken under operation. The potential for malignancy could not be excluded with abdominal USG and CT. Therefore, the gallbladder and cystic lesion excised through the liver with the aid of hook by holding with grasper and ousted from the abdomen as accompanied with the gallbladder; and laparoscopic cholecystectomy and the cyst excision has been carried out successfully. Macroscopic examination of the specimen revealed cholecystectomy material with a wall thickness of 0.2 cm with 6 x 5 cm dimensions when it was opened (Figure 3). There were no specific findings in the mucosa. Inside the bladder there was one black-colored stone with a diameter of 0.5 cm. A localized cystic lesion with 1.5 x 1 x 0.5 cm dimensions was observed on the outer surface of the material. Dirty-colored, soft viscous material was found inside the cyst. The lesion was stained with hematoxylin and eosin and examined under light microscopy. In the pathol-

ogy report, the cyst was located in the serosal area of the gallbladder and was lined with the pseudostratified ciliated cuboidal-columnar epithelium and abundant goblet cells (Figure 4, Figure 5). No squamous metaplasia or dysplasia was present in the cystic epithelium. A dense smooth muscle layer and fibro-elastic connective tissue was identified under the lining epithelium. The findings were consistent with those of ciliated foregut cyst and chronic cholecystitis. There were no postoperative course complications. The patient was discharged

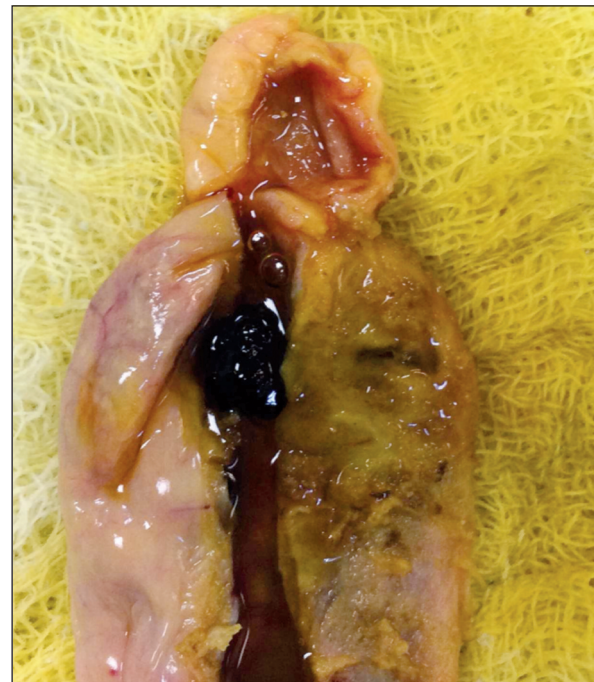

FIGURE 3: Blown-up image of the resected specimen. A mucinous cyst was attached on the fundus of the gallbladder.

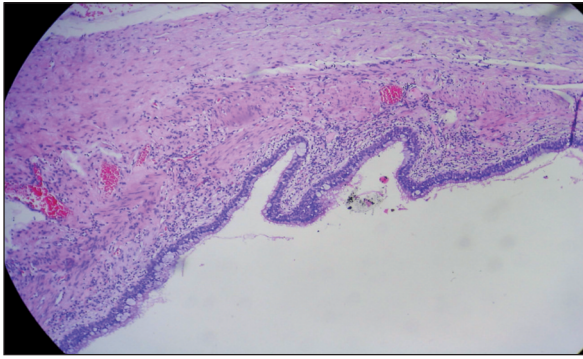


FIGURE 4: Photomicrograph of the resected specimen. Dense smooth muscle layer and fibroelastic connective tissue were identified under the lining epithelium (H&E, $\times 10$).

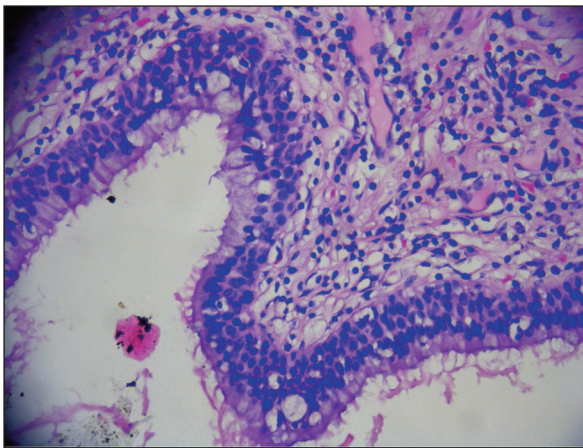


FIGURE 5: Photomicrograph of the resected specimen. The cystic lining cells consist of the pseudostratified ciliated cuboidal-columnar epithelium and numerous goblet cells (H&E, $\times 40$).

two days after the surgery and had no recurrence or lasting effects at the 6-month follow-up.

Informed consent was obtained from the patient for being included in the study.

DISCUSSION

The foregut is the anterior part of the alimentary canal, extending from the mouth to the duodenum at the entrance of the bile duct. Its constituent organs, including the liver, gallbladder, lungs, and pancreas develop as a result of branching of the foregut. Ciliated foregut cysts were first described by Friedreich in 1857, followed by Eberth in 1866. Friedreich believed it to be a congenital condition and proposed that it was an embryologic malformation.

Ciliated foregut cysts are very rare, benign, and usually found above the diaphragm. If they present below the diaphragm, the most common site is the liver (ciliated hepatic foregut cysts). No fewer than 60 cases of ciliated hepatic foregut cysts have been reported, but extrahepatic cysts are extremely rare. Kakitsubata et al. were the first to describe such lesions in the gallbladder, but Nam et al. (2000) were the first to use the term “ciliated cyst of the gallbladder” in a Farrugia et al.’s case report.⁵

To date only a few cases of these ciliated foregut cysts in the gallbladder have been reported in literature. When these studies are reviewed, it is seen that foregut cysts differs with respect to the numerous characteristics. For instance, the size of the cyst was 15 mm. in Nam et al.’s study; 35 mm. in Bulut et al.’s study; and 45 mm. in Farrugia et al.’s study. The size of the cyst is 15 mm. in our study. In addition, it is seen that the location of the cyst also differs. For instance, the cyst is located in corpus in Kakitsubata et al.’s study; in triangle of calot in Beteddini et al.’s study; and in common hepatic duct in Cottreau et al.’s study.⁵ The cyst is located in fundus in our study.

Characteristically, the cystic lining cells consisted of pseudostratified columnar epithelium, and frequently, single-layer ciliated epithelium. When the ciliated epithelium was stained with hematoxylin-eosin, a few or many goblet cells could be observed in the lining epithelium. The subepithelial layer consisted of fibro-elastic tissue or thin smooth muscle layer similar to the muscularis mucosa of the gastrointestinal tract. Eosinophils, lymphocytes or adipocytes have been observed in the fibroelastic tissue.⁶

USG is extremely efficient in the detection of ciliated foregut cysts and hepatobiliary lesions. USG shows these lesions as cystic masses containing high-echoic areas similar to those of malignant tumors.⁷ The lack of echogenicity of calcification or calculus can also provide help in the differential diagnosis. In the opinion of Tuncyurek et al., the features present in USG are adequate for a definitive diagnosis, thereby negating the requirement for other imaging methods.³ Differential diagnosis becomes challenging with CT and magnetic reso-

nance imaging (MRI) if the lesion size is smaller than 1 cm. Nevertheless, Muraoka et al. documented the use of CT in a case report in which a protruding tumor with slight enhancement in the gallbladder was demonstrated. The authors stated that angiography revealed no additional information, but sequential CT-arteriography (CTA) was able to clearly identify that the tumor was a cystic lesion.⁴ Hirono et al. used MRI and magnetic resonance cholangiopancreatography, which showed a mass that had no communication with the lumen of the gallbladder. Accordingly, the authors were able to consider that the cystic lesion might not be malignant preoperatively.¹ Kim et al. presented a well-defined hypoechoic cystic mass in the wall of the gallbladder using an endoscopic ultrasonogram.⁷ Baranger et al. reported a ciliated cyst of the common bile duct.⁸ Beteddini et al. were first to describe these lesions in the triangle of Calot and Farrugia et al. recorded the largest cyst of the gallbladder.⁵

Clinically, unilocular cystic lesions are considered benign rather than malignant lesions, and all reported ciliated foregut cysts of the gallbladder were unilocular. Regardless, excision is needed to resolve the patient's symptoms and to rule out other benign or malignant cystic lesions including biliary cystadenoma, cystadenocarcinoma, cystic gastric heterotopias, cystic duct cyst, and cystic lymphangioma.⁹ Histologic examination and accurate pathologic diagnosis are essential to avoid unnecessary additional treatment such as chemotherapy or radiotherapy for malignant neoplasms. Radiologically, however, these cysts of the gallbladder are generally suggestive of benign cystic lesions.

There are reports of squamous cell carcinoma arising from ciliated foregut cysts; however, there are no such reports regarding ciliated foregut cysts in the gallbladder.¹⁰ In our opinion, if a gallbladder cyst is detected when an operation is planned for gallbladder stones, it would be beneficial to include this in the surgical field in order to determine the diagnosis and appropriate treatment for the gallbladder cyst.

CONCLUSION

While as much as foregut-origin ciliated cyst of the gallbladder is a rare, benign lesion; however, excision is recommended because there is a risk of malignant transformation.

Source of Finance

During this study, no financial or spiritual support was received neither from any pharmaceutical company that has a direct connection with the research subject, nor from a company that provides or produces medical instruments and materials which may negatively affect the evaluation process of this study.

Conflict of Interest

No conflicts of interest between the authors and / or family members of the scientific and medical committee members or members of the potential conflicts of interest, counseling, expertise, working conditions, share holding and similar situations in any firm.

Authorship Contributions

This study is entirely author's own work and no other author contribution.

REFERENCES

- Hirono S, Tanimura H, Yokoyama S, Uchiyama K, Tani M, Onishi H, et al. Clinical features of ciliated foregut cyst of the gallbladder: a rare entity of cystic lesion in the gallbladder. *Dig Dis Sci*. 2002;47(8):1817-20. [[Crossref](#)] [[PubMed](#)]
- Hwang I, Cho J. Ciliated foregut cyst of the gallbladder: a case report and literature review. *Korean J Hepatobiliary Pancreat Surg*. 2016;20(2):85-8. [[Crossref](#)] [[PubMed](#)] [[PMC](#)]
- Tunçyürek Ö, Nart D, Yaman B, Buyukcoban E. A ciliated foregut cyst in a gallbladder: the smallest recorded. *Jpn J Radiol*. 2013;31(6): 412-8. [[Crossref](#)] [[PubMed](#)]
- Muraoka A, Watanabe N, Ikeda Y, Kokudo Y, Tatemoto A, Sone Y, et al. Ciliated foregut cyst of the gallbladder: report of a case. *Surg Today*. 2003;33(9):718-21. [[Crossref](#)] [[PubMed](#)]
- Farrugia A, Blazic I, Andrejevic P. Ciliated foregut cyst of the gall bladder: the largest ever described. *BMJ Case Rep*. 2017. [[Crossref](#)]
- Bulut AŞ, Karayalçın K. Ciliated foregut cyst of the gallbladder: report of a case and review of literature. *Patholog Res Int*. 2010;2010: 193535.
- Kim JH, Jeon YS, Lee JI, Han JY, Lee KH, Cho SG. Ciliated foregut cyst of the gallbladder: A case report with US and CT findings. *J Korean Soc Radiol*. 2010;62(4):373-6. [[Crossref](#)]
- Baranger B, Poichotte A, Bernard P, Palazzo L, Deligny M, André JL. Ciliated cyst located in the common bile duct. *Ann Chir*. 1998;52(1): 98. [[PubMed](#)]
- Yamamoto K, Yamamoto F, Maeda A, Igimi H, Yamamoto M, Yamaguchi R, et al. Tubulopapillary adenoma of the gallbladder accompanied by bile duct tumor thrombus. *World J Gastroenterol*. 2014;20(26):8736-9. [[Crossref](#)] [[PubMed](#)] [[PMC](#)]
- Furlanetto A, Dei Tos AP. Squamous cell carcinoma arising in a ciliated hepatic foregut cyst. *Virchows Arch*. 2002;441(3):296-8. [[Crossref](#)] [[PubMed](#)]