

# Kaposi's Varicelliform Eruption in a Patient with Tinea on Systemic Steroids

## Sistemik Steroid Tedavisi Alan Tinealı Bir Hastada Görülen Kaposi'nin Variselliform Döküntüsü

<sup>ID</sup> Annu PRIYA<sup>a</sup>, <sup>ID</sup> Mohammad ADIL<sup>a</sup>, <sup>ID</sup> Syed Suhail AMIN<sup>a</sup>, <sup>ID</sup> Mohd MOHTASHIM<sup>a</sup>, <sup>ID</sup> Shagufta QADRI<sup>a</sup>,  
<sup>ID</sup> Mahtab ALAM<sup>a</sup>

<sup>a</sup>Jawaharlal Nehru Medical College (JNMC), Aligarh Muslim University (AMU), Aligarh, INDIA

**ABSTRACT** Kaposi's varicelliform eruption is a distinct type of cutaneous eruption usually caused by herpes simplex virus that infects persons with pre-existing dermatoses. We report a case of twenty-one-year-old male who had received parenteral steroids for extensive tinea corporis and cruris from a quack and presented with generalized vesicular eruption, predominantly over the annular plaques of tinea, suggestive of Kaposi's varicelliform eruption. There was history of high-grade fever, malaise and intense itching over the lesions. Diagnosis was made by clinical features, giant cells on Tzanck smear and HSV DNA on PCR. Patient responded adequately to intravenous acyclovir.

**Keywords:** Kaposi's varicelliform eruption; eczema herpeticum; tinea

**ÖZET** Kaposi'nin variselliform döküntüsü, genellikle önceden var olan dermatozları olan kişileri enfekte eden herpes simpleks virüsünün neden olduğu farklı bir deri döküntüsü türüdür. Bir sahte doktordan yaygın tinea corporis ve cruris için parenteral steroid alan ve Kaposi'nin variselliform erüpsiyonunu düşündüren, ağırlıklı olarak tinea'nın halka plakları üzerinde yaygın veziküler erüpsiyon ile gelen yirmi bir yaşında bir erkek olguyu sunuyoruz. Hastada yüksek ateş, halsizlik ve lezyonlarda yoğun kaşıntı öyküsü vardı. Tanı klinik özellikler, Tzanck smearda görülen dev hücreler ve PCR testinde saptanan HSV DNA ile konuldu. Hasta intravenöz asiklovire yeterince yanıt verdi.

**Anahtar Kelimeler:** Kaposi'nin variselliform döküntüsü; herpetik egzema; tinea

Kaposi's varicelliform eruption is a rare distinct cutaneous eruption, usually caused by *herpes simplex virus*, in a patient with pre-existing dermatosis.<sup>1</sup> It most commonly affects atopic skin and was, therefore, earlier referred to as eczema herpeticum, but few case reports describe this disease in patients with several other primary dermatoses. Herein, we describe Kaposi's varicelliform eruption in a patient with extensive tinea.

### CASE REPORT

A 21-year old male patient was admitted to emergency room with history of high grade fever, malaise

and sudden generalized fluid-filled eruptions over the body associated with intense itching for 1 day. He also gave history of annular lesions over the groin and trunk for the last six months for which he had taken treatment from a private dermatologist, who diagnosed it to be a case of tinea corporis et cruris and prescribed itraconazole. The patient stopped treatment on his own after 2 weeks as he found no improvement. Thereafter, he had been taking treatment for these lesions from a quack in the form of intravenous steroids (dexamethasone) on and off for the past 2 months. The patient informed that the newly formed fluid-filled lesions are most severe along these annular lesions.

**Correspondence:** Mohammad ADIL

Jawaharlal Nehru Medical College (JNMC), Aligarh Muslim University (AMU), Aligarh, INDIA

**E-mail:** dr.mohd.adil@gmail.com



Peer review under responsibility of Türkiye Klinikleri Journal of Dermatology.

**Received:** 16 Jun 2019

**Received in revised form:** 14 Jul 2019

**Accepted:** 18 Jul 2019

**Available online:** 24 Dec 2020

2146-9016 / Copyright © 2020 by Türkiye Klinikleri. This is an open access article under the CC BY-NC-ND license (<http://creativecommons.org/licenses/by-nc-nd/4.0/>).

On physical examination, the patient was found to have fever (38.3 °F), tachycardia (heart rate-110/min) and tachypnea (respiratory rate-20/min). Inguinal lymph nodes were found to be enlarged bilaterally. Rest of the general and systemic examination was normal. Cutaneous examination revealed multiple, dome-shaped, umbilicated vesicles containing clear, straw-coloured to hemorrhagic fluid present over the body. These were present discretely over the face, extremities and trunk and were arranged in an annular fashion at places such as the groin, upper medial aspect of thigh and lower abdomen (Figure 1, Figure 2). The mucosae were not involved.

A Tzanck smear was made from one of the vesicles and showed multinucleate giant cells (Figure 3). IgM antibodies to HSV-1 was also detected in the serum. PCR for HSV-1 DNA from the vesicle was positive. On the basis of the clinical findings and investigations, the diagnosis of Kaposi varicelliform eruption (KVE) due to HSV-1 was made. The patient was administered intravenous acyclovir in the dose of 10 mg/kg/day for 14 days along with topical 2% mupirocin ointment and calamine lotion. Prophylactic antibiotics, antifungals (itraconazole) and antihistamine were also started. He improved with the treatment and by the tenth day, all the lesions had dried (Figure 4). The healing took place with scab formation and post-inflammatory hypopigmentation and scars.

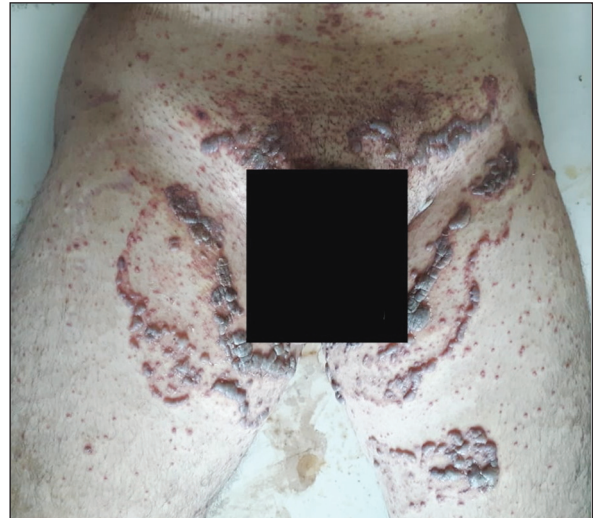


FIGURE 2: Closer view of the groin showing annular arrangement of the vesicles.

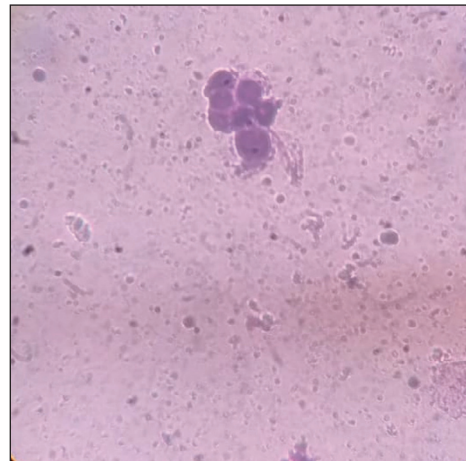


FIGURE 3: Multinucleate giant cell on Tzanck smear.

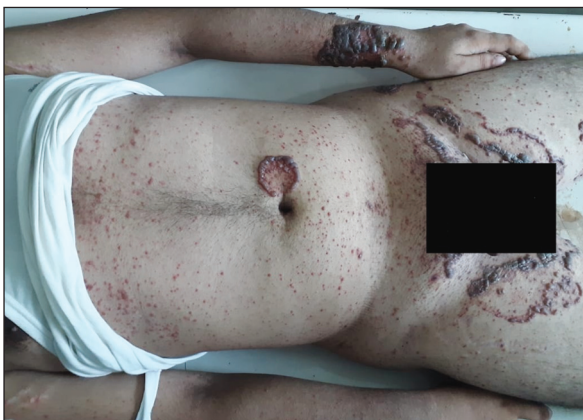

FIGURE 1: Hemorrhagic vesicles present in an annular fashion in the groin, near umbilicus and on left forearm along with discrete arrangement elsewhere on the body.

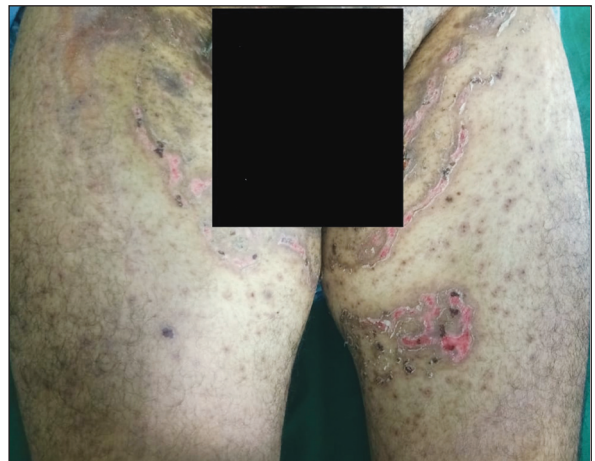


FIGURE 4: Improvement of the lesions after ten days of treatment.

## DISCUSSION

Kaposi's varicelliform eruption was originally described by Moritz Kaposi in the 19<sup>th</sup> century, who thought it to be a fungal infection, whereas Juliysber said the causative organism was bacteria. Later, in the twentieth century, Freun confirmed its viral etiology by showing cytoplasmic inclusions.<sup>2</sup> It is a severe viral infection caused by HSV-1 (mainly), HSV-2, vaccinia virus or Coxsackie virus. KVE has been seen in patients suffering from dermatoses like atopic dermatitis, seborrheic dermatitis, Darier's disease, ichthyosis, pemphigus vulgaris, bullous pemphigoid, mycoses fungoides, Hailey-Hailey disease, psoriasis, pityriasis rubra pilaris, irritant contact dermatitis, scabies, lupus vulgaris, staphylococcal scalded skin syndrome, irritant dermatitis, sunburn, after dermatological procedures like skin auto-grafting, after vaccination with BCG and vaccinia, Grover's disease etc.<sup>3</sup>

The pathogenesis of KVE is not understood completely. But it is well known that patients with skin barrier damage and immune deficiencies are the most susceptible to develop KVE, due to defective humoral and cellular immunity.<sup>4</sup> Systemic corticosteroids are also believed to predispose an individual to KVE by producing systemic immunosuppression. Other topical and systemic immunosuppressive drugs such as tacrolimus have been also associated.<sup>5</sup> Our patient had received systemic corticosteroids. He also had disturbed epidermal barrier due to tinea, thus making him doubly susceptible.

KVE presents as disseminated, monomorphic eruption of vesicles, discrete or in clusters, sometimes umbilicated, which may transform into pustules and erosions. Atypical variants of eczema herpeticum with characteristic disseminated lesions on tense erythematous plaques may occur.<sup>6</sup> Systemic features like fever, malaise and regional lymphadenopathy are often found. The disease if not treated properly on time can lead to multiple organ involvement due to systemic viraemia and hence mortality. Recurrent episodes may also occur.

The diagnosis of KVE is mainly clinical. Tzanck smear is an easy, rapid, economical and diagnostic

test where it shows characteristic epithelial multi-nucleated giant cells and acantholysis.<sup>7</sup> Polymerase chain reaction can be done to detect virus while virus isolation and cultivation from the vesicular fluid remains the definite diagnostic approach. Histopathological biopsy, electron microscopy, immunofluorescence are the other modalities for diagnosis.<sup>2</sup> Differential diagnoses of KVE are contact dermatitis, varicella and impetigo.

Oral or intravenous antivirals like acyclovir (10-15 mg/kg/day) remains the treatment of choice and it has been found that the lesions resolved faster leading to quicker recovery than placebo. Oral valacyclovir can be administered to patients getting treatment on outpatients basis due to having higher bioavailability. The above treatment should be started as early as possible to prevent morbidity and mortality. Foscarnet is the agent of choice in case of acyclovir resistant cases.<sup>8</sup> Some authors prefer to give vidarabine ointment along with oral antiviral therapy. In cases of eczema vaccinatum, vaccinia immunoglobulin should be given.<sup>9</sup> Prophylactic systemic antibiotics should also be started in order to control heavy bacterial colonization.

We could find only one case report of Kaposi's varicelliform eruption in a patient with tinea. Kang et al. in 2004 had described this disease in a patient with tinea cruris.<sup>10</sup> However, the eruption was localized to the site of tinea infection. Our case is unique as lesions of Kaposi's varicelliform eruption not only affected the previous lesions of tinea, but the normal skin as well.

### **Declaration of Patient Consent**

*The authors certify that they have obtained all appropriate patient consent forms. In the form, the patient has given his consent for his images and other clinical information to be reported in the journal. The patient understand that name and initials will not be published and due efforts will be made to conceal identity, but anonymity cannot be guaranteed.*

### **Source of Finance**

*During this study, no financial or spiritual support was received neither from any pharmaceutical company that has a direct connection with the research subject, nor from a com-*

pany that provides or produces medical instruments and materials which may negatively affect the evaluation process of this study.

### Conflict of Interest

No conflicts of interest between the authors and / or family members of the scientific and medical committee members or members of the potential conflicts of interest, counseling, expertise, working conditions, share holding and similar situations in any firm.

### Authorship Contributions

**Idea/Concept:** Mohammad Adil, Syed Suhail Amin; **Design:** Annu Priya, Mohammad Adil, Mahtab Alam; **Control/Supervision:** Mohammad Adil, Mohammad Adil, Mohd Mohtashim; **Data Collection and/or Processing:** Annu Priya, Shagufta Qadri, Mahtab Alam; **Analysis and/or Interpretation:** Mohammad Adil; **Literature Review:** Annu Priya, Mahtab Alam; **Writing the Article:** Annu Priya, Mohammad Adil; **Critical Review:** Mohammad Adil, Mohd Mohtashim, Shagufta Qadri; **References and Fundings:** Mohammad Adil, Syed Suhail; **Materials:** Mohammad Adil, Shagufta Qadri.

## REFERENCES

- Garcia-Morales I, Case-Mérida S, Escudero J. Kaposi's varicelliform eruption in a patient with Darier's disease. *Indian J Dermatol.* 2018;63(5):434-5.[Crossref] [PubMed] [PMC]
- Ferrari B, Taliercio V, Luna P, Abad ME, Larralde M. Kaposi's varicelliform eruption: a case series. *Indian Dermatol Online J.* 2015;6(6):399-402.[Crossref] [PubMed] [PMC]
- Lehman JS, el-Azhary RA. Kaposi varicelliform eruption in patients with autoimmune bullous dermatoses. *Int J Dermatol.* 2016;55(3):e136-40.[Crossref] [PubMed]
- Hong S, Kim EH, Cho SB, Rha SY. Kaposi's varicelliform-like eruption in a patient treated with everolimus for metastatic renal cell carcinoma: report of a rare case. *Case Rep Oncol.* 2014;27;7(2):337-42.[Crossref] [PubMed] [PMC]
- Olson J, Robles DT, Kirby P, Colven R. Kaposi varicelliform eruption (eczema herpeticum). *Dermatol Online J.* 2008;28;14(2):18. [PubMed]
- Wollenberg A, Zoch C, Wetzel S, Plewig G, Przybilla B. Predisposing factors and clinical features of eczema herpeticum: a retrospective analysis of 100 cases. *J Am Acad Dermatol.* 2003;49(2):198-205.[Crossref] [PubMed]
- de Aquino Paulo Filho T, deFreitas YK, da Nóbrega MT, Lima CB, Carriço BL, Silva MA, et al. Hailey-Hailey disease associated with herpetic eczema-the value of the Tzanck smear test. *Dermatol Pract Concept.* 2014;4(4):29-31.[Crossref] [PubMed] [PMC]
- Studdiford JS, Valko GP, Belin LJ, Stonehouse AR. Eczema herpeticum: making the diagnosis in the emergency department. *J Emerg Med.* 2011;40(2):167-9.[Crossref] [PubMed]
- Frisch S, Siegfried EC. The clinical spectrum and therapeutic challenge of eczema herpeticum. *Pediatr Dermatol.* 2011;28(1):46-52.[Crossref] [PubMed]
- Kang SH, Yi JH, Choi HS, Yun SK. Eczema herpeticum localized to area of tinea cruris. *J Dermatol.* 2004;31(1):60-2.[Crossref] [PubMed]