

# N-Type Tracheo-Esophageal Fistula in a Newborn: Case Report

## Yenidoğan Döneminde Tanısı Konmuş N-Tipi Trakeoözofageal Fistül

Levent ELEMEN, MD,<sup>a</sup>  
Gökçe GÜNBEY, MD,<sup>b</sup>  
Alper SOYSAL, MD,<sup>b</sup>  
Erdem TONGUÇ, MD,<sup>c</sup>  
Metin KARABÖCÜOĞLU, MD,<sup>b</sup>  
Ergun ERDOĞAN, MD<sup>a</sup>

Clinics of  
<sup>a</sup>Pediatric Surgery,  
<sup>b</sup>Pediatrics,  
<sup>c</sup>Radiology,  
İstanbul German Hospital, İstanbul

Geliş Tarihi/Received: 23.07.2008  
Kabul Tarihi/Accepted: 19.09.2008

*This study was presented as a poster in  
XV. National Neonatology Congress,  
4-7 April 2007, Antalya.*

Yazışma Adresi/Correspondence:  
Levent ELEMEN, MD  
İstanbul German Hospital,  
Clinic of Pediatric Surgery, İstanbul,  
TÜRKİYE/TURKEY  
elemenlevent@hotmail.com

**ABSTRACT** H-type tracheo-esophageal fistula (TEF) is a rare congenital malformation with the incidence of about 1 per 100.000 births. H-type TEF has been associated with the triad of paroxysms of coughing and cyanosis after feeding, gaseous distension of the gastrointestinal tract and recurrent respiratory system disease. The rarity of the condition and presence of non-specific symptoms may postpone the detection of TEF in newborns. Fistula identification can be elusive and difficult thus delaying the prompt diagnosis to early childhood or even to adulthood. Performance of an esophagogram and bronchoscopy are eventually diagnostic. Operative management is easy which involves isolation, division and excision of the fistula, and subsequent repair of the trachea and esophagus through a right lower cervical incision. Early surgical correction is required to prevent respiratory complications. We report a case of TEF in a six days old female neonate. Diagnostic tools, differential diagnosis, and surgical correction strategies are discussed.

**Key Words:** Tracheoesophageal fistula; infant, newborn

**ÖZET** İzole H-tipi trakeoözofageal fistül (TÖF) sıklığı yaklaşık olarak 100.000 canlı doğumda 1 görülen nadir bir doğumsal anomalidir. Beslenme sonrası morarma ve öksürük, gastrointestinal sistemin gaz distansiyonu ve yineleyen solunum yolları enfeksiyonları eşlik eden bulgulardır. Yenidoğan döneminde bulguların TÖF'e özgün olmaması nedeni ile tanı genellikle çocukluk, hatta erişkin döneme kadar gecikebilmektedir. Özofagografi ve bronkoskopi TÖF olgularında kesin tanıyı sağlayan araçlardır. Tedavi cerrahidir ve sağ servikal insizyondan TÖF'ün bulunması, ayrılması, bağlanması ve trakea ve özofagusun onarılmasını içermektedir. Solunum sistemi komplikasyonlarının önlenmesi için erken cerrahi müdahale gereklidir. Bu çalışmada, altı günlük iken izole H-N tipi TÖF tanısı almış bir olgu tanısall yöntemler, ayırıcı tanı ve tedavi açısından tartışılmıştır.

**Anahtar Kelimeler:** Trakeoözofageal fistül; yenidoğan

**Türkiye Klinikleri J Pediatr 2010;19(1):94-7**

H-type tracheo-esophageal fistula (TEF) without associated esophageal atresia (EA) is a rare condition posing diagnostic and management problems. It occurs with an incidence of 4% of all congenital tracheo-esophageal abnormalities.<sup>1-4</sup> N-type TEF is more frequent than H-type, owing to the oblique angle of the fistula from the trachea (carina or main bronchi) to the esophagus, anatomically at the level of the neck root (C7-T1).<sup>3,5</sup> Pressure changes between both structures can cause entry of air into the esophagus, or entry of esophageal content into the trachea.<sup>5,6</sup>

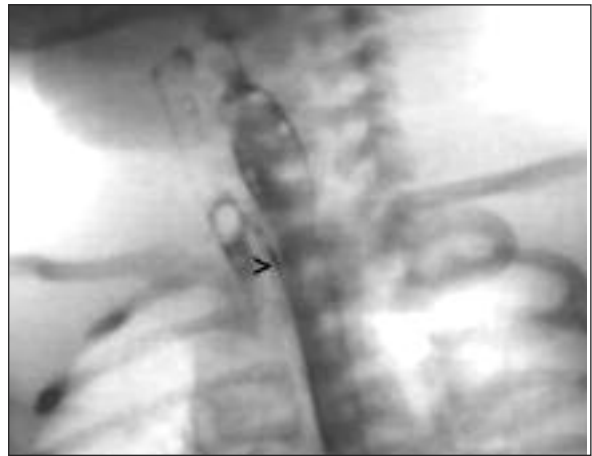
Apparently, TEF with or without EA should be included in the differential diagnosis of surgical causes of respiratory distress in neonates.<sup>7,8</sup> The

clinical diagnosis of an H-N-type TEF has been associated with the triad of paroxysms of coughing or cyanosis with feeding, gaseous distension of the gastrointestinal tract and recurrent pneumonia or bronchitis.<sup>5</sup> Clinical observation together with performance of a tube esophagogram and bronchoscopy are eventually diagnostic. In spite of many other diagnostic techniques advocated such as scintigraphy, direct sagittal CT scan and virtual bronchoscopy fistula identification can be elusive and difficult thus delaying the prompt diagnosis to early childhood or even to adulthood.<sup>1,9-12</sup> Herein, we report a case of N-type TEF with a brief description of its surgical history.

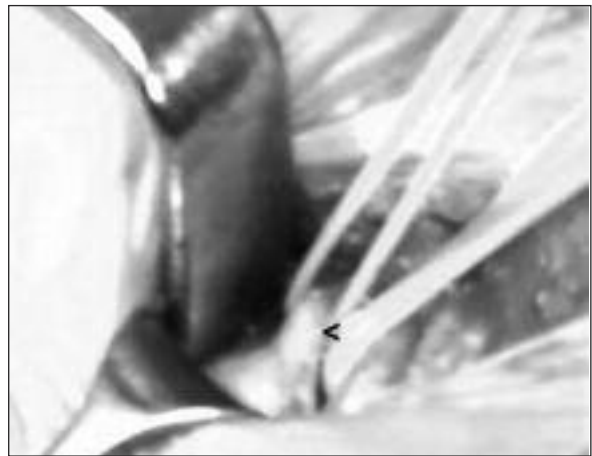## CASE REPORT

A female infant who was born at 35 weeks of gestational age with a birth weight of 2835 gr experienced severe respiratory distress and cyanosis on the post-natal 12<sup>th</sup> hour following oral feedings. Her chest X-ray revealed para-cardiac pneumonic infiltrations. Since blood parameters as CRP, leukocyte count, leukocyte formula were highly suggestive for an infection antibiotherapy consisting of ampicillin (100 mgr/kg body weight/day, twice a day) and netilmycin (4 mgr/kg body weight/day, once a day) was started with the presumptive diagnosis of neonatal pneumonia. On the post-natal 4<sup>th</sup> day, as her symptoms worsened under antibiotherapy cine-esophagography with water soluble media was performed. Although no pathology was revealed in the swallowing phase of the study severe gastro-esophageal reflux and an N-type TEF were detected in the Trendelenburg position (Figure 1). On the post-natal 6<sup>th</sup> day the patient was taken to operation. Fistula tract opening was located by rigid bronchoscopy and a 4 FR guiding wire was introduced in. Then esophagoscopy was performed which detected the guiding wire in the esophagus thus confirming the diagnosis of TEF. N-type TEF was isolated, divided and excised through a right lower cervical incision (Figure 2). Both tracheal and esophageal walls were repaired with non-absorbable interrupted sutures (5/0 Prolene, Ethicon Ltd, Edinburgh, UK.).

Convalescence was uneventful and the patient was discharged on the post-operative 3<sup>rd</sup> day. Me-



**FIGURE 1:** N-type TEF were detected in the cine-esophagography. (>) indicates the fistula.



**FIGURE 2:** N-type TEF was isolated, and divided through a right lower cervical incision. (<) indicates the fistula.

dical therapy for gastro-esophageal reflux was started immediately after and carried on. On the post-operative 1<sup>st</sup> year cine-esophagography and bronchoscopy were repeated which revealed absence of gastro-esophageal reflux with a normal anatomy of esophagus and stomach. Medical therapy for gastro-esophageal reflux was terminated and she is still doing well without complications for a follow-up period of three years.

## DISCUSSION

Tracheo-esophageal malformations were first described by Durston in 1670. The first successful operations for OA/TEF were performed by Leven in 1941 and Haight in 1943. Despite the fact that 40%

of patients with associated tracheo-esophageal malformations are premature newborns recent progresses in neonatal surgery, anesthesia and neonatal care units minimize the negative effect of prematurity on survival.<sup>1,2,10,13,14</sup>

Several theories have attempted to explain the etiology of TEF, but it is currently believed that the development of an abnormal epithelial-lined connection between the respiratory and digestive tubes results in the creation of a TEF.<sup>15</sup> The median pharyngeal groove develops in the ventral aspect of foregut at day 22 of gestation. This tissue develops into the respiratory and digestive tubes. If proliferation of mesenchyme between the respiratory and digestive tubes fails the situation leads to patency between the tubes, thus producing a TEF. Although most of the tracheo-esophageal anomalies are frequently associated with other congenital anomalies, congenital malformations are least common in cases of isolated TEF.<sup>3</sup>

Children with TEF are invariably symptomatic from birth, although the symptoms may be intermittent and may vary in severity. A high index of suspicion is required because the symptoms are not specifically attributed to the disease.<sup>5,16</sup> In isolated H-N-type TEF cases prompt diagnosis may be delayed to early childhood or even to adulthood. A recent study reported the median age on diagnosis as eight months.<sup>15</sup> In another series the median delay from the time of first presentation to diagnosis was found 14 days (7-58 days) and median age at surgery was 15 days (8-60 days).<sup>9</sup> In the presented patient early onset of symptoms those lead to early work-up and diagnosis was evidently due to severe gastro-esophageal reflux. Thus, our case seems to be one of the earliest diagnosed and operated patients.

Tube esophagogram is the mainstay of the diagnosis. The obliquity of the fistula causes failure of its visualization in routine swallow studies. A nasogastric tube is passed into the stomach and slowly withdrawn into the mid-esophagus and non-ionic water soluble contrast media is injected. The aim is local distention of esophagus with contrast in the

region of fistula, which will encourage the passage of contrast through TEF to airway.<sup>6</sup> Opposing Tarcan et al. who stated that gastro-esophageal reflux might postpone the detection of TEF in newborns, in the present case gastro-esophageal reflux into the TEF rendered the diagnosis by facilitating its visualization.<sup>17</sup>

We performed rigid bronchoscopy and endoscopy to confirm the diagnosis. Rigid bronchoscopy and esophagoscopy are reported to be more valuable than esophagography in isolated TEF cases by detecting the exact place of the fistula with its dimensions.<sup>4,14,18,19</sup> Therefore, surgery can be planned accordingly, as in our case.<sup>20,21</sup>

Isolation, division and excision of the fistula, and repair of the trachea and esophagus through a right lower cervical incision has become the standard approach in TEF cases.<sup>6,22</sup> This kind of repair reduces the morbidity and mortality.<sup>10,18,23,24</sup> Recently endoscopic repairs by means of electrocautery, tissue glues or sclerosing materials have been advocated. Besides those, thoracoscopic ligation of TEF was also described.<sup>25-28</sup> However, these methods do not comprise complete division and excision of the fistula and are not completely free of risk of recurrence. Ligation of the fistula rather than complete division and excision increases the incidence of recurrent TEF.<sup>15</sup>

As a conclusion, H-N-type TEF should be kept in mind in cases of paroxysms of coughing or cyanosis with feeding, gaseous distension of the gastrointestinal tract and recurrent pneumonia or bronchitis. Diagnostic work-up, which consists of real time cine-esophagography, rigid bronchoscopy and esophagoscopy should be started immediately if there is strong assumption of an H-N-type TEF. In presence of gastro-esophageal reflux Trandelenburg positioning of the patient during cine-esophagography may aid the detection. Operation should be performed through a lower cervical incision. Division and total removal of TEF and concomitant repair of trachea and esophagus is mandatory rather than simple ligation of the fistula.

## REFERENCES

1. Kabesh A. Esophageal atresia and tracheoesophageal fistulae. *The fetus and newborn. ASJOG* 2004;1(2):81-3.
2. Clark DC. Esophageal atresia and tracheoesophageal fistula. *Am Fam Physician* 1999; 59(4):910-6, 919-20.
3. Haron CM, Coran AG. Congenital anomalies of the esophagus. In: Grosfeld JL, O'Neill JA, Coran AG, Fonkalsrud EW. *Pediatric Surgery*. 6th ed. Vol. 2. St Louis, MO, Mosby Year-Book; 2006.p.1051-81.
4. Günel E, Dilsiz A, Abasıyanık A, Kaymakçı A, Gündoğan AH. [Esophageal Atresia: A 5-year Experience]. *Türkiye Klinikleri Pediatri* 1997; 6(2):45-7.
5. Harjai MM, Holla RG, Kale R, Sharma YK. H-type tracheo-oesophageal fistula. *Arch Dis Child Fetal Neonatal Ed* 2007;92(1):F40.
6. Crabbe DC. Isolated tracheo-oesophageal fistula. *Paediatr Respir Rev* 2003;4(1):74-8.
7. Sönmez K. [Neonatal surgical emergencies of respiratory system Türkiye Klinikleri J Surg Med Sci 2007;3(15):7-13.
8. Kurt A, Kasar T, Çıtak Kurt N, Akarsu S, Yılmaz E, Aygün AD. [The etiological causes of respiratory distress in hospitalized newborns]. *Türkiye Klinikleri J Pediatr* 2007;16(3):171-7.
9. Ng J, Antao B, Bartram J, Raghavan A, Shaws R. Diagnostic difficulties in the management of H-type tracheoesophageal fistula. *Acta Radiol* 2006;47(8):801-5.
10. Killen DA, Greenlee HB. Transcervical repair of h-type congenital tracheo-esophageal fistula: review of the literature. *Ann Surg* 1965; 162:145-50.
11. De Schutter I, Vermeulen F, De Wachter E, Ernst C, Malfroot A. Isolated tracheoesophageal fistula in a 10-year-old girl. *Eur J Pediatr* 2007;166(9):911-4.
12. Tsai JM, Yu WK, Lee CH. H-type tracheoesophageal fistula: report of one case. *Acta Paediatr Taiwan* 2002;43(2):100-1.
13. Manning PB, Morgan RA, Coran AG, Wesley JR, Polley TZ Jr, Behrendt DM, et al. Fifty years' experience with esophageal atresia and tracheoesophageal fistula. Beginning with Cameron Haight's first operation in 1935. *Ann Surg* 1986;204(4):446-53.
14. O'Neill JA Jr, Holcomb GW, Neblett WW 3rd. Recent experience with esophageal atresia. *Ann Surg* 1982;195:739-45.
15. Kovesi T, Rubin S. Long-term complications of congenital esophageal atresia and/or tracheoesophageal fistula. *Chest* 2004;126(3): 915-25.
16. Brookes JT, Smith MC, Smith RJ, Bauman NM, Manaligod JM, Sandler AD. H-type congenital tracheoesophageal fistula: University Of Iowa experience 1985 to 2005. *Ann Otol Rhinol Laryngol* 2007;116(5):363-8.
17. Tarcan A, Gürakan B, Arda S, Boybat F. Congenital H-type fistula: delayed diagnosis in a preterm infant. *J Matern Fetal Neonatal Med* 2003;13(4):279-80.
18. Genty E, Attal P, Nicollas R, Roger G, Triglia JM, Garabedian EN. Congenital tracheoesophageal fistula without esophageal atresia. *Int J Pediatr Otorhinolaryngol* 1999;48(3):231-8.
19. Karnak I, Senocak ME, Hiçsönmez A, Büyükpamukçu N. The diagnosis and treatment of H-type tracheoesophageal fistula. *J Pediatr Surg* 1997;32(12):1670-4.
20. Goyal A, Potter F, Losty PD. Transillumination of H-type tracheoesophageal fistula using flexible miniature bronchoscopy: an innovative technique for operative localization. *J Pediatr Surg* 2005;40(6):e33-4.
21. Blanco-Rodríguez G, Penchyna-Grub J, Trujillo-Ponce A, Nava-Ocampo AA. Preoperative catheterization of H-type tracheoesophageal fistula to facilitate its localization and surgical correction. *Eur J Pediatr Surg* 2006; 16(1):14-7.
22. Suzuki T, Narisawa T, Tanaka H, Hirai Y, Sanada Y, Chiba M. Closure of a cervical H-type tracheoesophageal fistula. *Thorac Cardiovasc Surg* 2004;52(1):57-9.
23. Ko BA, Frederic R, DiTirro PA, Glatleider PA, Applebaum H. Simplified access for division of the low cervical/high thoracic H-type tracheoesophageal fistula. *J Pediatr Surg* 2000; 35(11):1621-2.
24. Foker JE, Linden BC, Boyle EM Jr, Marquardt C. Development of a true primary repair for the full spectrum of esophageal atresia. *Ann Surg* 1997;226(4):533-41
25. Rothenberg SS. Thoracoscopic repair of tracheoesophageal fistula in newborns. *J Pediatr Surg* 2002;37(6):869-72.
26. Tzifa KT, Maxwell EL, Chait P, James AL, Forte V, Ein SH, et al. Endoscopic treatment of congenital H-Type and recurrent tracheoesophageal fistula with electrocautery and histocryl glue. *Int J Pediatr Otorhinolaryngol* 2006;70(5):925-30.
27. Garand SA, Kareti LR, Dumont TM, Seip C. Thoracoscopic repair of tracheoesophageal fistula in a septuagenarian. *Ann Thorac Surg* 2006;81(5):1899-901.
28. Bhatnagar V, Lal R, Srinivas M, Agarwala S, Mitra DK. Endoscopic treatment of tracheoesophageal fistula using electrocautery and the Nd:YAG laser. *J Pediatr Surg* 1999;34(3): 464-7.