

Coexistence of Congenital Chylous Ascites and Congenital Hypothyroidism: Case Report

Konjenital Şilöz Asit ve Konjenital Hipotiroidizm Birlikteliği

Hüseyin ALTUNHAN,^a
Ali ANNAGÜR,^a
Sabahattin ERTUĞRUL,^a
Hasan Ali YÜKSEKKAYA,^b
Rahmi ÖRS^a

Departments of
^aNeonatology,
^bPediatric Gastroenterology,
Selçuk University
Meram Faculty of Medicine, Konya

Geliş Tarihi/Received: 12.04.2011
Kabul Tarihi/Accepted: 10.10.2011

Yazışma Adresi/Correspondence:
Ali ANNAGÜR
Selçuk University
Meram Faculty of Medicine,
Department of Pediatrics, Konya
TÜRKİYE/TURKEY
aliannagur@yahoo.com

ABSTRACT Chylous ascites is a rare clinical entity occurring as the result of the extravasation of the chyle into the peritoneal cavity. A 20-day newborn admitted to our clinic with high level of thyroid stimulating hormone (TSH) and abdominal distension was diagnosed with chylous ascites and congenital hypothyroidism after paracentesis. Thyroid hormone supplementation, a diet containing middle-chain triglycerides and octreotide were started. To our knowledge, the patient who recovered completely with the treatment is the first case in the literature with chylous ascites accompanied by congenital hypothyroidism. Thus, in newborns with chylous ascites, congenital hypothyroidism should be considered and the diagnosis should be confirmed with paracentesis. This approach may be beneficial for early diagnosis and treatment. Chylous ascites can be treated successfully with a diet containing middle-chain triglycerides and octreotide.

Key Words: Chylous ascites; congenital hypothyroidism; octreotide; infant, newborn

ÖZET Şilöz asit, şilusun periton boşluğuna sızması sonucunda meydana gelen nadir bir klinik antitedir. Kliniğimize tiroit stimüle edici hormon (TSH) artışı ve karın şişliği ile başvuran yirmi günlük bir yenidoğana parasetez sonucunda şilöz asit ve konjenital hipotiroidizm tanısı koyuldu. Tiroid hormon tedavisi, orta zincirli yağ asitlerini içeren bir diyet ve oktreotid başlandı. Tedavi ile düzelen hastanın, literatürde konjenital hipotiroidizmin eşlik ettiği ilk şilöz asit olgusu olduğunu düşünüyoruz. Bu nedenle, şilöz asiti olan yenidoğanlarda konjenital hipotiroidizm akılda tutulmalıdır ve tanı parasetezle doğrulanmalıdır. Bu yaklaşım, erken tanı ve tedavi açısından yararlıdır. Şilöz asit orta zincirli yağ asitlerini içeren bir diyet ve oktreotidle başarılı şekilde tedavi edilebilir.

Anahtar Kelimeler: Şilöz asitler; konjenital hipotiroidizm; oktreotid; bebek, yenidoğan

Türkiye Klinikleri J Med Sci 2012;32(5):1486-9

Chylous ascites (CA) is a rare clinical entity due to the extravasation of the chyle into the peritoneal cavity. The most common cause of CA diagnosed in newborns is congenital malformation of lymphatic ducts.^{1,2} The efficiency of octreotide together with diet has been proven in CA treatment.¹⁻³ Diagnosis of congenital hypothyroidism is generally made with newborn screenings.⁴ Congenital hypothyroidism can manifest with ascites. Sometimes extrathyroid anomalies may accompany hypothyroidism.^{5,6} However, to our knowledge, coexistence of congenital hypothyroidism and CA has not been mentioned before.

The lymphatic channels from the liver and intestine drain into the cisterna chyli, and its obstruction may cause escape of its fatty content into the peritoneal cavity, resulting in CA.⁷ The majority of pediatric CA cases (45-70%) are congenital or idiopathic lymphatic abnormalities.^{1,2,8,9} Besides, intussusception, intestinal malrotation, incarcerated hernia, obstructive lesions, traumas, peritoneal dialysis, liver cirrhosis, malignancy, surgical injuries, tuberculosis and other inflammatory peritoneal infections may be considered.^{1,2,8-12} The definitive diagnosis of CA depends on paracentesis.^{2,8} The most important feature of the fluid drawn by paracentesis is that it is rich in lymphocytes, protein and chylomicrons. The physical appearance and biochemical content of ascites can change according to diet, nature of the lymphatic loss and cell content.^{2,8-10}

In this study, we discussed the companionship of congenital hypothyroidism and CA in a newborn and its successful treatment with diet, medium-chain triglycerides (MCT) and octreotide in the light of the literature.

CASE REPORT

A 20-days old newborn female baby with abdominal distension was diagnosed with congenital hypothyroidism and was referred to our hospital. She was born at term with caesarean section; her birth weight was 3.6 kg. There was no history of regular follow up during prenatal period. The baby had no complaint after delivery, until the tenth day when abdominal distension developed. She was administered L-thyroxine in an outpatient clinic of another hospital due to high levels of Thyroid-stimulating hormone (TSH) (>100 mIU/ml) at ten days after birth. The patient was referred to our unit because of increasing abdominal distention during this treatment. The physical examination revealed a distended abdomen (Figure 1) with an abdominal circumference of 42 cm. The skin was dry, front fontanel was 3x3 cm. Other system examinations were normal. Ultrasonography (USG) examination revealed disseminated ascites, and no pleural effusion was present. Ecocardiography was normal. The test results were; TSH: 50 mIU/mL (N: 0.34-

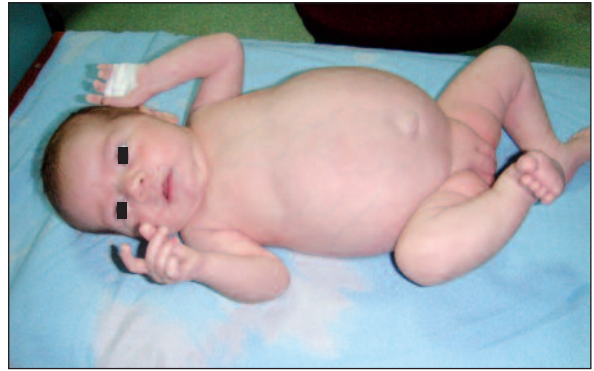

FIGURE 1: Distended abdomen in chylous ascites.
(See for colored form <http://tipbilimleri.turkiyeklinikleri.com/>)

5.6), free thyroxine (fT₄): 1.2 ng/dL (N: 0.61-1.12), thyroid peroxidase (formerly microsomal) antibodies (TPOAb): <5.00 IU/mL (N: 0-9), thyroglobulin antibodies (TGAb): <10.00 IU/mL (N: 0-4), and Thyroglobulin: 137 ng/ml (N: 1.4-78). In thyroid USG, the right thyroid lobe was 7x7 mm, and the left one was 7x5 mm. Routine hematologic and biochemical parameters were normal. To make the differential diagnosis paracentesis was performed and a milk-like fluid was obtained. The biochemical values of the sample (Figure 2) were as follows: total protein: 11.5 g/dL, albumin: 9 g/dL, triglyceride: 3695 mg/dL (N: 30-100), glucose: 101 mg/dL, lactate dehydrogenase (LDH): 519 U/L, amylase: 15 U/L and white blood cell count (WBC): 700 cells/mm³ (90% lymphocyte). There was no atypical cell in cytologic examination, and the microbiological culture was negative. The patient was




FIGURE 2: Paracentesis fluid in chylous ascites has a milky appearance.
(See for colored form <http://tipbilimleri.turkiyeklinikleri.com/>)

diagnosed with congenital CA and congenital hypothyroidism with those findings. Toxoplasmosis, other, rubella virus, cytomegalovirus, herpes simplex virus (TORCH) analysis and metabolic screening were negative. Chromosome analysis was 46XX, and was normal structurally. Abdominal computed tomography (CT) revealed no abnormality except ascites. Thyroid hormone supplementation (L-thyroxine, 10 µg/kg/day) for hypothyroidism and octreotide 2 µg/kg/h for CA was initiated. However, the abdominal circumference did not decrease. Breastfeeding was stopped and she was given 50% MCT formula feeding (Pep-tijunior; Nutricia advanced medical nutrition, cuijk, Holland). However, since recovery was not achieved octreotide dose was increased up to 4 µg/kg/hr and a fat-free formula containing 50% MCT (Basic P) was started. Following this treatment, the abdominal distension and abdominal circumference decreased. After 4 weeks of treatment, the abdominal circumference decreased to 34.5cm. Ultrasonographic evaluation showed that the ascites had regressed to minimal. The patient was discharged with fat-free formula containing 50% MCT, octreotide (5 µg/kg/day, subcutaneous) and thyroid hormone supplementation. Thirty-six days after the discharge the patient was re-hospitalized due to disseminated ascites. The family revealed that the patient had not received octreotide for the last 18 days. Abdominal circumference was 42.5 cm. Octreotide was reinitiated. The patient was discharged two weeks later with no ascites and was recommended to take octreotide and to diet. During the follow up within the first 6 months, no ascites developed. There was no abnormality in growth and development.

DISCUSSION

Here, we described a complicated treatment course of a patient with CA. The efficiency of octreotide together with diet has been proven in CA treatment.¹⁻³ Diet is one of the most important steps in the treatment of chylous ascites. Normally, while long-chain triglycerides (LCT) are directly absorbed into the lymphatic system, MCT bypasses the lymphatic system and is absorbed into the por-

tal system directly from the intestines. If the amount of LCT in the diet is decreased and the amount of MCT is increased, lymphatic flow decreases and time is gained to heal the underlying pathology naturally.^{1-3,8,9} However, with the concern that prolonged use of low-LCT diet can affect neurological development negatively, it is suggested that this diet should be restricted to 3-4 months.^{2,8,9,13} Another treatment alternative in heavy or diet resistant CA cases is total parenteral nutrition (TPN). With TPN, less chylous fluid accumulates in the peritoneal area and the maturation of lymphatic system can be completed in time.

Most of the congenital CA cases improve spontaneously or with medical treatment. However, in cases that do not respond to conservative treatment, surgical methods may help. Surgical treatment includes the resection of the localized anomaly or the ligation of the lymphatic leakage. In some cases, multiple ligations or peritoneal-venous shunts may be required.^{2,3,8}

Octreotide, which is a synthetic analogue of somatostatin is a pharmacologic agent with proven efficiency for the treatment of CA.^{1-3,9,14} Although its mechanism of action is not clear, it has been shown that it inhibits lymphatic secretion through somatostatin receptors in the gut and decreases intestinal blood flow. Octreotide can be administered by continuous intravenous infusion or subcutaneously. In the treatment of chylous ascites, the use of octreotide together with TPN and diets containing MCT seems to be the most effective medical option.^{2,3}

In our case, octreotide (2µg/kg/h) was the initial treatment option. As a satisfactory response could not be achieved, 50% MCT containing formula (peptijunior) was added to the regimen. As the amount of ascites remained the same, the dose of the octreotide was increased to 4µg/kg/h and 50% MCT containing fat-free formula was initiated (Basic-P). With this treatment, the abdominal circumference decreased and the ascites regressed within 4 weeks. The thyroid function tests did not change during octreotide treatment. Subcutaneous treatment followed this. Since the response was sat-

isfactory, TPN was not initiated. No complication was observed related to the treatment. When the patient was hospitalized for the second time, the history revealed that the patient had not used octreotide at home. The patient underwent the same treatment and recovered quickly.

Congenital hypothyroidism is a disease with a frequency of 1/3000-4000.⁴ Most of the early diagnosed cases are through routine screenings. Congenital hypothyroidism rarely presents with ascites. Sometimes other congenital abnormalities accompany this.^{5,6} Congenital hypothyroidism and congenital chylothorax association has been shown in the literature.⁶ However, congenital hypothyroidism accompanying congenital CA has not been reported. Thyroid hormones play an important role in the regulation of the lymphatic system. In congenital hypothyroidism it is accepted that an impairment of lymphatic flow or primary malformation in lymphatic veins causes chylothorax.^{5,6} Kesel et al. suggested that the etiology of chylothorax in congenital hypothyroidism was decreased adrenergic

system activity.⁶ We suggest that in our case, primary malformation of the lymphatic veins is responsible for the CA. In our case, we started with thyroid hormone supplementation, but with the use of MCT and octreotide we observed significant improvement in the ascites of the patient. The recurrence of CA after octreotide treatment was stopped while the patient continued taking thyroid hormones, suggests that the use of thyroid hormone supplementation alone does not lead to recovery.

In conclusion, congenital CA is a rare disease. Since thyroid hormones play an important role in the regulation of the lymphatic system, congenital CA can be together with congenital hypothyroidism. To our knowledge, our case is the first in the literature with congenital CA accompanied with congenital hypothyroidism. Thus, early paracentesis in newborns with ascites is essential for early diagnosis. Analysis of thyroid hormones allows initiation of hormone treatment if required. MCT containing diet and octreotide therapy in congenital CA treatment is effective and successful.

REFERENCES

1. Soyulu A, Alaygut D, Yeşilirmak D, Kasap B, Türkmen M, Duman N, et al. Resolution of chyloperitoneum in a preterm with octreotide, diet and cessation of dialysis. *Pediatr Nephrol* 2010;25(2):363-6.
2. Karagol BS, Zenciroglu A, Gokce S, Kundak AA, Ipek MS. Therapeutic management of neonatal chylous ascites: report of a case and review of the literature. *Acta Paediatr* 2010; 99(9):1307-10.
3. Bhatia C, Pratap U, Slavik Z. Octreotide therapy: a new horizon in treatment of iatrogenic chyloperitoneum. *Arch Dis Child* 2001;85(3): 234-5.
4. American Academy of Pediatrics, Rose SR; Section on Endocrinology and Committee on Genetics, American Thyroid Association, Brown RS; Public Health Committee, Lawson Wilkins Pediatric Endocrine Society, Foley T, Kaplowitz PB, Kaye CI, Sundararajan S, Varma SK. Update of newborn screening and therapy for congenital hypothyroidism. *Pediatrics* 2006;117(6):2290-303.
5. Toromanovic A, Tahirovic H. Congenital hypothyroidism associated with neonatal tooth, Pierre-Robin syndrome and congenital heart defects. *J Pediatr Endocrinol Metab* 2009; 22(10):881-2.
6. Kessel I, Makhoul IR, Sujov P. Congenital hypothyroidism and nonimmune hydrops fetalis: associated? *Pediatrics* 1999;103(1):E9.
7. Lee PH, Lin CL, Lai PC, Yang CW. Octreotide therapy for chylous ascites in a chronic dialysis patient. *Nephrology (Carlton)* 2005;10(4): 344-7.
8. Chye JK, Lim CT, Van der Heuvel M. Neonatal chylous ascites-report of three case and review of the literature. *Pediatr Surg Int* 1997; 12(4):296-8.
9. Türkkahraman D, Artan R, Gelen T, Karayalçın B. [Chylous ascites in infancy: report of two cases]. *Turkish Pediatric Journal* 2004;47(4): 269-72.
10. Guzoğlu N, Erdeve O, Yılmaz Y, Dilmen U. Intra-peritoneal extravasation from umbilical venous catheter in differential diagnosis of neonatal chylous ascites. *Acta Paediatr* 2010;99(9):1284.
11. Olivar Roldán J, Fernández Martínez A, Martínez Sancho E, Díaz Gómez J, Martín Borge V, Gómez Candela C. [Postsurgical chylous ascites: case report and literature review]. *Nutr Hosp* 2009;24(6):748-50.
12. Zarroug AE, Srinivasan SK, Wulkan ML. Incidental chylous fluid during hernia repair may be a harbinger of malrotation. *J Pediatr Surg* 2010;45(1):E17-8.
13. D'Agostino S, Costa L, Fabbro MA, Spina P, Musi L. [Neonatal chylous ascites: a case report and review of the literature]. *Pediatr Med Chir* 1998;20(4):285-6.
14. Kuroiwa G, Takayama T, Sato Y, Takahashi Y, Fujita T, Nobuoka A, et al. Primary intestinal lymphangiectasia successfully treated with octreotide. *J Gastroenterol* 2001;36(2):129-32.