

# Whipple's Disease: Case Report and Review of the Literature

## Whipple Hastalığı: Olgu Sunumu ve Literatürün Gözden Geçirilmesi

Bülent YAŞAR, MD,<sup>a</sup>  
Pembegül GÜNEŞ, MD,<sup>b</sup>  
Oya ÖVÜNÇ KURDAŞ, MD<sup>a</sup>

Departments of  
<sup>a</sup>Gastroenterohepatology,  
<sup>b</sup>Pathology,  
Haydarpaşa Numune Training and  
Research Hospital, İstanbul

Geliş Tarihi/Received: 11.09.2009  
Kabul Tarihi/Accepted: 23.10.2009

*'Whipple's disease: Review of the literature and report of a case' was presented in 25<sup>th</sup> National Gastroenterology Week in Adana as a poster presentation.*

Yazışma Adresi/Correspondence:  
Bülent Yaşar, MD  
Haydarpaşa Numune Training and  
Research Hospital,  
Department of Gastroenterohepatology,  
İstanbul,  
TÜRKİYE/TURKEY  
drbyasar@yahoo.com

**ABSTRACT** Whipple disease is a rare, multisystemic, relapsing, bacterial disease, which can be fatal if undiagnosed or untreated. It occurs in white, middle-aged men in 80% of the cases. It has a variety of clinical manifestations and should be considered in a patient with weight loss, diarrhea, abdominal pain and arthralgias in clinical practice. The disease is commonly diagnosed by histological examination of small bowel biopsies, after staining with periodic acid-schiff. Because of the rarity of the disease, its diagnosis is not often considered. In the present report, we present a case of Whipple's disease. Our aim is to remind the Whipple disease in patients with abdominal pain, weight loss and diarrhea. We also review the current literature on this topic

**Key Words:** Whipple disease; abdominal pain; arthralgia; periodic acid-schiff reaction

**ÖZET** Whipple hastalığı, seyrek görülen, sistemik, tekrarlayıcı, tanı konulmadığı ve tedavi edilmediğinde fatal seyreden bakteriyel bir hastalıktır. Olguların %80'i beyaz, orta yaşlı erkeklerdir. Farklı klinik bulguları olmakla birlikte kilo kaybı, ishal, abdominal ağrı ve artralji semptomları olan hastalarda akla gelmelidir. Tanı sıklıkla ince barsak biyopsilerinin, periyodik asit-schiff ile boyandıktan sonra incelenmesi ile konur. Hastalık seyrek görüldüğü için tanı akla gelmeyebilir. Burada, bir Whipple hastalığı olgusunu sunduk. Amacımız, karın ağrısı, kilo kaybı ve ishal semptomları ile başvuran hastalarda, Whipple hastalığının hatırlanmasına yardımcı olmaktır. Aynı zamanda bu başlıkla ilgili güncel literatürü de gözden geçirdik.

**Anahtar Kelimeler:** Whipple hastalığı; karın ağrısı; artralji; periyodik asit-schiff reaksiyonu

**Türkiye Klinikleri J Gastroenterohepatol 2010;17(2):107-10**

Whipple disease is chronic, multisystemic, granulomatous disease caused by a gram positive bacillus *Tropheryma whipplei*.<sup>1</sup> The most common symptoms include weight loss, diarrhea, abdominal pain and arthralgia, and less frequent symptoms are fever, lymphadenopathy, skin hyperpigmentation and cardiovascular and neurological abnormalities.<sup>2</sup> The diagnosis is based on the detection of characteristic periodic acid-Schiff (PAS) material containing macrophages in the lamina propria of duodenum.<sup>3</sup> We present a patient who admitted to hospital with a rapid onset of diarrhea, vomiting, fatigue and weight loss, who was subsequently diagnosed as Whipple disease. We described his diagnosis, management and review of the literature about this condition.

## CASE REPORT

A 63-year-old male patient was admitted to the gastroenterology department, with complaining of fatigue, abdominal pain, vomiting, watery diarrhea and weight loss of 12 kg during the previous three months. Physical examination was normal except for 2/6 systolic suffle on the apex of the heart. The complete blood count revealed leukocytosis (13.300/mm<sup>3</sup>; 77% neutrophils, 15% lymphocyte), normal hemoglobin, hematocrit and platelets (15 g/dL, 40%, 235.000/mm<sup>3</sup>, respectively). Other abnormal laboratory findings were: C reactive protein 2.04 mg/dL (normal <0.8 mg/dL), iron 18 µg/dL, total iron binding capacity 168 µg/dL, albumin 3.2 g/dL, lactate dehydrogenase (LDH) 287 U/L. Human immunodeficiency virus serology was negative. Abdominal ultrasound showed no abnormalities. An abdominal computerized tomography scan revealed enlarged mesenteric, peripancreatic and paraaortic lymph nodes. Gastrosocopy and colonoscopy revealed gastritis, generalized whitish appearance of the duodenal mucosa and linear small ulcers in the terminal ileum. Both duodenum and terminal ileum histology revealed extensive infiltration of the lamina propria with PAS stain positive macrophages, consistent with the diagnosis of Whipple's disease (Figure 1, 2). Neurologic examination was normal. Therapy with benzylpenicillin 1,2 g/d and streptomycin 1 g/d was initiated for 14 days and followed by trimethoprim-sulfamethoxazole (160-800 mg) as the maintenance therapy. Within a week, his diarrhea discontinued and abdominal pain resolved. He completely recovered within a month. He gained nearly 20 kg in 6 months during maintenance therapy. Control tissue biopsies were obtained after the end of 6 months of therapy and in which infiltration of the lamina propria with PAS stain positive macrophages was still revealed. Laboratory findings had returned to the normal ranges. Written informed consent was obtained from the patient for the publication of study.

## DISCUSSION

Whipple disease is a rare, relapsing condition caused by the systemic infection of actinomycete

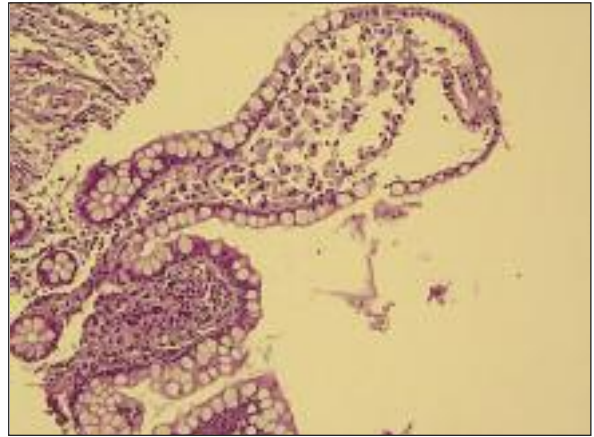


FIGURE 1: Macrophage infiltration in the lamina propria. (Hematoxylin-Eosin stain x 100).

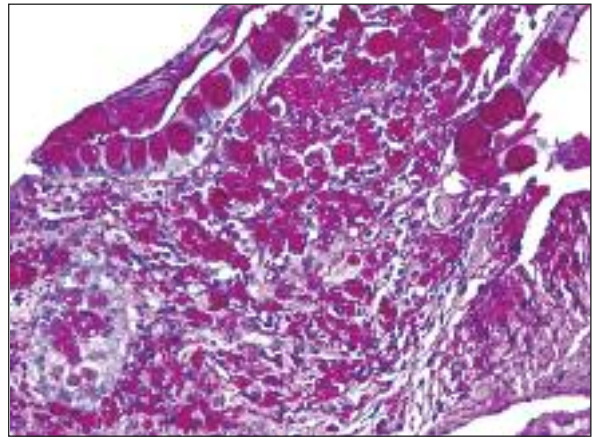


FIGURE 2: Macrophage cytoplasm contains large amounts of particles that are PAS-positive and diastase resistant staining. (Periodic acid Schiff stain x 400).

*T. whipplei*. Only 696 cases had been reported until 1987, approximately annual incidence is less than 1 per 100.000 population. Disease preferentially affects middle-aged white men.<sup>4</sup>

The pathogenesis of Whipple disease still remains controversial. Invasion or uptake of the bacillus is widespread throughout the body, including the intestinal epithelium, macrophages, capillary and lymphatic endothelium, colon, liver, brain, heart, lung, synovium, kidney, bone marrow and skin.<sup>5</sup> All of these sites show a remarkable lack of inflammatory response to the bacillus. It has been shown that Whipple disease is associated with in vivo defective cell-mediated immune function not only during active disease but also in remission.

Thus in vivo evidence of immune dysfunction is accompanied by various in vitro evidence, including the occurrence of a reduced CD4/CD8 ratio and various macrophage abnormalities. The latter include the fact that macrophages of the patient display an impairment of phagocyte function as well as a decrease in expression of CD11b, a molecule involved in regulating phagocytosis and intracellular degradation. More recently it has been shown that Whipple disease patients have macrophages with a decreased capacity to secrete IL-12, a cytokine which has a central role in cell-mediated immunity and in regulating the differentiation of interferon-gamma producing T-helper type 1 cells.<sup>3</sup>

Patients typically present with migratory arthralgias of the large joints or less often a chronic, migratory nondeforming oligoarthritis which may precede the onset of typical gastrointestinal symptoms by an average of 8 years.<sup>3</sup>

The main gastrointestinal manifestations of the disease are diarrhea, weight loss, abdominal pain, steatorrhea, and malabsorption, which may progress to a severe wasting syndrome and abdominal lymphadenopathy.<sup>6</sup> Some patients develop severe ascites and peripheral edema. The most serious manifestation of the disease is central nervous system (CNS) involvement. Cognitive dysfunction is the most common abnormality. Oculomasticatory myorhythmia and oculo-facial-skeletal myorhythmia are considered pathognomonic for Whipple disease.<sup>7</sup> The other CNS symptoms are upper motor neuron disorder, myoclonic signs, psychiatric signs, apathy, confusion, memory impairment, unconsciousness, dementia, supranuclear ophthalmoplegia. Hypoalbuminemia, fever, skin pigmentation, arthralgia and anemia are the other common symptoms.

*T. whipplei* can be detected in saliva and marginal and subgingival plaque, intestinal biopsy specimens, and stool samples of the healthy individuals.<sup>8</sup> The existence of asymptomatic carriers of *T. whipplei* indicates that Whipple disease do not develop in every individual following exposure to this soil microorganism, supporting the theory that an underlying genetic predisposition leads to development of the disease.

The differential diagnosis includes multisystemic infections, and granulomatous disorders. It must be distinguished from a wide range of chronic inflammatory and infectious conditions, including sarcoidosis, mycobacterial disease, fungal infections, brucellosis, protozoal diseases, inflammatory bowel disease, and Wegener's granulomatosis<sup>1</sup>. The clinical presentation also may mimic amyloidosis, advanced HIV infection, arthritis, and chronic meningitis.

Upper gastrointestinal endoscopy with biopsies of the small intestine is the test of choice in making the diagnose of the Whipple disease.<sup>9</sup> Duodenal mucosa may appear pale, yellow, and clumsy macroscopically. Duodenal biopsies are histologically characterised by foamy macrophages in the lamina propria (Figure 1). The macrophage cytoplasm contains large amounts of particles that are PAS-positive and diastase resistant but negative for Ziehl Nielsen staining (Figure 2). The identification of the 16S r RNA of *T. whipplei* has led to the use of 16S r DNA primers for detection of this organism by using polymerase chain reaction (PCR).<sup>10</sup> However, as mentioned above, healthy carriers can have positive PCR results even if they do not have disease. Thus, this method is not suitable for screening and should only be used for patients with clinical suspicion for Whipple disease. An immunofluorescence serologic test has been developed. This test has shown that IgM antibodies seem to be more specific than IgG; however, serology is not the current diagnostic tool that can be applied routinely.<sup>11</sup> Electron microscopy and cultivation of *T. whipplei* is limited to specialised research laboratories.<sup>12</sup>

Recommended first-line therapy includes 2 weeks of either an intravenous third generation cephalosporin (ceftriaxone, 2-4 g/d, 2 weeks) or intravenous penicillin (benzyl penicilin, 1.2 mU/d, 2 weeks). In case of allergy the initial therapy is intramuscular streptomycin (1 g/d, 2 weeks) followed by an oral trimethoprim-sulphamethoxazole (960 mg twice a day) for at least one year. If an allergic reaction occurs to oral trimethoprim-sulphamethoxazole, maintenance therapy is 100 mg oral doxycycline twice daily plus 200 mg oral hydroxychloroquine twice daily >1 year.

In cases with CNS involvement therapy is 100 mg doxycycline twice daily plus 200 mg hydroxychloroquine three times daily plus co-trimoxazole five DS tablets or 4-8 tablets (500 mg) sulfadiazine orally for at least one year or until disappearance of bacterial DNA and immunohistochemistry on duodenal biopsies.<sup>13</sup> The potential for neurologic involvement makes it important to use since it can easily cross the blood-brain barrier.

For Whipple disease patients with severe CNS manifestations, i.e. cerebral lesions and in patients with long-lasting high fever after the initiation of antibiotic therapy, additional therapy with steroids is beneficial and sometimes lifesaving.

As mentioned previously, patients with Whipple disease have characteristic immunological defects associated with reduced Th1 response. Thus, relapsing disease may occur in some patients despite adequate antibiotic treatment. In such cases, an additional supportive therapy with Th1 cytokines, such as interferon gamma could be useful.<sup>14</sup>

The most important criteria for successful tre-

atment is the improvement of clinical symptoms, which should occur within 7 to 21 days. Investigators suggest that the follow-up visits must be done at 6th months, 12th months and thereafter annually following initiation of therapy. Surveillance endoscopy and small bowel biopsy are not necessary and may be misleading since PAS staining material may persist long after clinical resolution of the disease, as we seen in our case; this probably represents dead organisms rather than a propensity to relapse. PCR techniques seem to be superior for the evaluation of successful therapy.<sup>15</sup>

Relapses have been reported in as many as 17 to 35 percent of patients. It is assumed that relapses reflect incomplete eradication of the organism with initial therapy.

In conclusion, Whipple disease has a variety of clinical findings. For clinical practice, it should be kept in mind in any patients presenting with abdominal pain, diarrhea, weight loss and arthralgias. If the diagnosis is considered, disease can be readily diagnosed and treated.

## REFERENCES

- James DG, Lipman MC. Whipple's disease: a granulomatous masquerader. *Clin Chest Med* 2002;23(2):513-9, xi-xii.
- Başak M, Gül S, Güney Y, Çankır Z, Coşansel C, Yazgan Y, et al. [A case of Whipple's disease presenting with the rupture of chorda tendinea]. *Türkiye Klinikleri J Gastroenterohepatol* 1997;8(1):5-9.
- Mahnel R, Kalt A, Ring S, Stallmach A, Strober W, Marth T. Immunosuppressive therapy in Whipple's disease patients is associated with the appearance of gastrointestinal manifestations. *Am J Gastroenterol* 2005; 100(5):1167-73.
- Schneider T, Moos V, Loddenkemper C, Marth T, Fenollar F, Raoult D. Whipple's disease: new aspects of pathogenesis and treatment. *Lancet Infect Dis* 2008;8(3):179-90.
- Schijf LJ, Becx MC, de Bruin PC, van der Vegt SG. Whipple's disease: easily diagnosed, if considered. *Neth J Med* 2008;66(9):392-5.
- Freeman HJ. Tropheryma whipplei infection. *World J Gastroenterol* 2009;15(17):2078-80.
- Durand DV, Lecomte C, Cathébras P, Rousset H, Godeau P. Whipple disease. Clinical review of 52 cases. The SNFMI Research Group on Whipple Disease. *Société Nationale Française de Médecine Interne. Medicine (Baltimore)* 1997;76(3):170-84.
- Ehrbar HU, Bauerfeind P, Dutly F, Koelz HR, Altwegg M. PCR-positive tests for Tropheryma whippelii in patients without Whipple's disease. *Lancet* 1999;353(9171):2214.
- Louis ED, Lynch T, Kaufmann P, Fahn S, Odel J. Diagnostic guidelines in central nervous system Whipple's disease. *Ann Neurol* 1996;40(4):561-8.
- Ramzan NN, Loftus E Jr, Burgart LJ, Rooney M, Batts KP, Wiesner RH, et al. Diagnosis and monitoring of Whipple disease by polymerase chain reaction. *Ann Intern Med* 1997;126(7): 520-7.
- Raoult D, La Scola B, Lecocq P, Lepidi H, Fournier PE. Culture and immunological detection of Tropheryma whippelii from the duodenum of a patient with Whipple disease. *JAMA* 2001;285(8):1039-43.
- Raoult D, Birg ML, La Scola B, Fournier PE, Enea M, Lepidi H, et al. Cultivation of the bacillus of Whipple's disease. *N Engl J Med* 2000;342(9):620-5.
- Schnider PJ, Reisinger EC, Berger T, Krejs GJ, Auff E. Treatment guidelines in central nervous system Whipple's disease. *Ann Neurol* 1997;41(4):561-2.
- Schneider T, Stallmach A, von Herbay A, Marth T, Strober W, Zeitl M. Treatment of refractory Whipple disease with interferon-gamma. *Ann Intern Med* 1998;129(11):875-7.
- von Herbay A, Ditton HJ, Maiwald M. Diagnostic application of a polymerase chain reaction assay for the Whipple's disease bacterium to intestinal biopsies. *Gastroenterology* 1996;110(6):1735-43.