

# Rehabilitation of Bilateral Maxillectomy with an Obturator Prosthesis: Case Report

## Çift Taraflı Maksiller Rezeksiyonun Obturatör Protez ile Rehabilitasyonu

Yeliz ARSLAN,<sup>a</sup>  
Betül KÖKDOĞAN BOYACI,<sup>a</sup>  
Hüseyin YAZICIOĞLU,<sup>a</sup>  
Merve BANKOĞLU GÜNGÖR<sup>a</sup>

<sup>a</sup>Department of Clinical Sciences,  
Division of Prosthodontics,  
Gazi University Faculty of Dentistry,  
Ankara

Geliş Tarihi/Received: 09.11.2014  
Kabul Tarihi/Accepted: 08.01.2015

*This study was presented as a poster at  
38<sup>th</sup> Annual Conference of the European  
Prosthodontic Association,  
25-27 September 2014, Istanbul, Turkey*

Yazışma Adresi/Correspondence:  
Yeliz ARSLAN  
Gazi University Faculty of Dentistry,  
Department of Clinical Sciences,  
Division of Prosthodontics, Ankara,  
TÜRKİYE/TURKEY  
dt.ylzarlan@yahoo.com

**ABSTRACT** Maxillary jaw resections can lead to significant facial deformity, impaired oral functions such as speech, swallowing, saliva retention, and psychological problems. The reconstruction of such bilateral maxillary defects with obturator prosthesis has become valuable means for the rehabilitation of these patients. These prostheses improve the ability of chewing function and phonation. The purpose of this clinical report is to present a bilateral complete maxillectomy patient rehabilitated with obturator prosthesis. A 47 year-old total maxillectomy patient was referred to prosthetic department. In intraoral examination it was observed that maxilla including hard palate was resected and bilateral concha nasalis inferiors were in a relationship with oral cavity. The patient was treated with an obturator prosthesis and a removable prosthesis for mandible. It was concluded that correctly designed obturator prosthesis helps to restore esthetic appearance, phonetics and function.

**Key Words:** Maxillofacial prosthesis; palatal obturators

**ÖZET** Maksiller çene rezeksiyonları önemli derecede yüz deformitelerine, konuşma, yutkunma ve tükürük akışı gibi oral fonksiyonların bozulmasına ve psikolojik problemlere sebep olabilmektedir. Çift taraflı maksiller defekte sahip hastaların tedavisinde obturator protezlerin kullanımı günümüzde önemli bir yöntem haline gelmiştir. Bu tip protezler çiğneme ve konuşma yeteneğini arttırmaktadırlar. Bu vaka sunumunda, kliniğimize başvuran 47 yaşındaki çift taraflı maksillektomi hastasının obturatör protez ile rehabilitasyonu anlatılmaktadır. Hastanın ağız içi muayenesinde sert damağı da içine alan bir üst çene rezeksiyonu ve nazal kavite ile oral kavitenin birbiriyle ilişkide olduğu gözlenmiştir. Hastanın üst çenesi bukkal uzantılı obturatör protez ile, alt çenesi ise hareketli bölümlü protez ile tedavi edilmiştir. Doğru bir şekilde dizayn edilmiş obturatör protezlerin estetik görünümün, konuşmanın ve fonksiyonun restore edilmesine yardımcı olduğu bildirilmiştir.

**Anahtar Kelimeler:** Maksillofasyal protezi; damak obturatorlar

**Türkiye Klinikleri J Dental Sci Cases 2015;1(3):146-51**

**M**axillectomy patients suffering from oral carcinoma including hard palate have a low incidence.<sup>1</sup> Only 9% of all oral cavity carcinomas are localized in the hard palate.<sup>1</sup> However, squamous cell carcinomas are not rare lesions. Fierz et al. stated that 76% of all tumors were squamous cell carcinoma.<sup>2</sup>

The first step of treatment of these lesions is surgical resection. The resection can lead to substantial facial defect, afflicted oral functions such as

doi: 10.5336/dentalcase.2014-42358

Copyright © 2015 by Türkiye Klinikleri

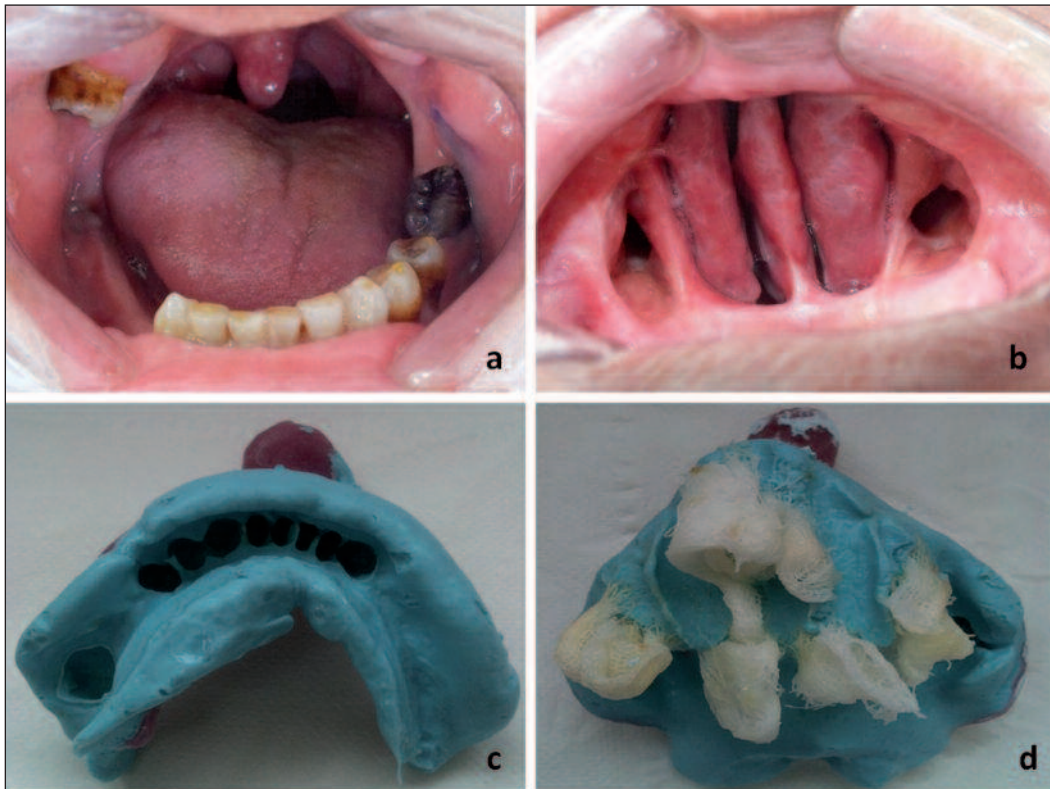
speech, swallowing, saliva retention, and certain psychological problems.<sup>3</sup> Moreover, loss of teeth, alveolar and basal jawbone can arouse substantial defect of mastication. Before or after the maxillary surgery, the patient may need to undergo radiotherapy and/or chemotherapy.<sup>4</sup> After the radiotherapy and/or chemotherapy treatment in short-term and long term alterations may occur. The acute changes are erythema, desquamation, hyposalivation, radiation caries.<sup>5-7</sup> At later stages, gingival and periodontal changes, including inadequate attachment at the radiation areas and gingival enlargement, may be observed.<sup>8</sup>

After the tumor is successfully resected, the surgical site may be closed using surgical reconstruction with free flaps or obturator prosthesis, upon the patient's general conditions and the extent of the defects anatomy.<sup>4</sup> After cancer rehabilitation, if free flap surgery is not possible, a prosthetic treatment is generally essential to separate the oral cavity from the nasal fossa, reconstruct oral functions like speech and deglutition and restore facial aesthetics.<sup>4</sup> Firstly, a temporary surgical obturator needs to be fabricated. This obturator is inserted immediately and it is used for 4-6 weeks. After this step, an interim therapy obturator is fabricated for two to three months and almost after 1 year the patient is treated with the definitive obturator. The purpose of this case report is to present rehabilitation of bilateral complete maxillectomy patient suffered from squamous cell carcinoma using obturator prosthesis.

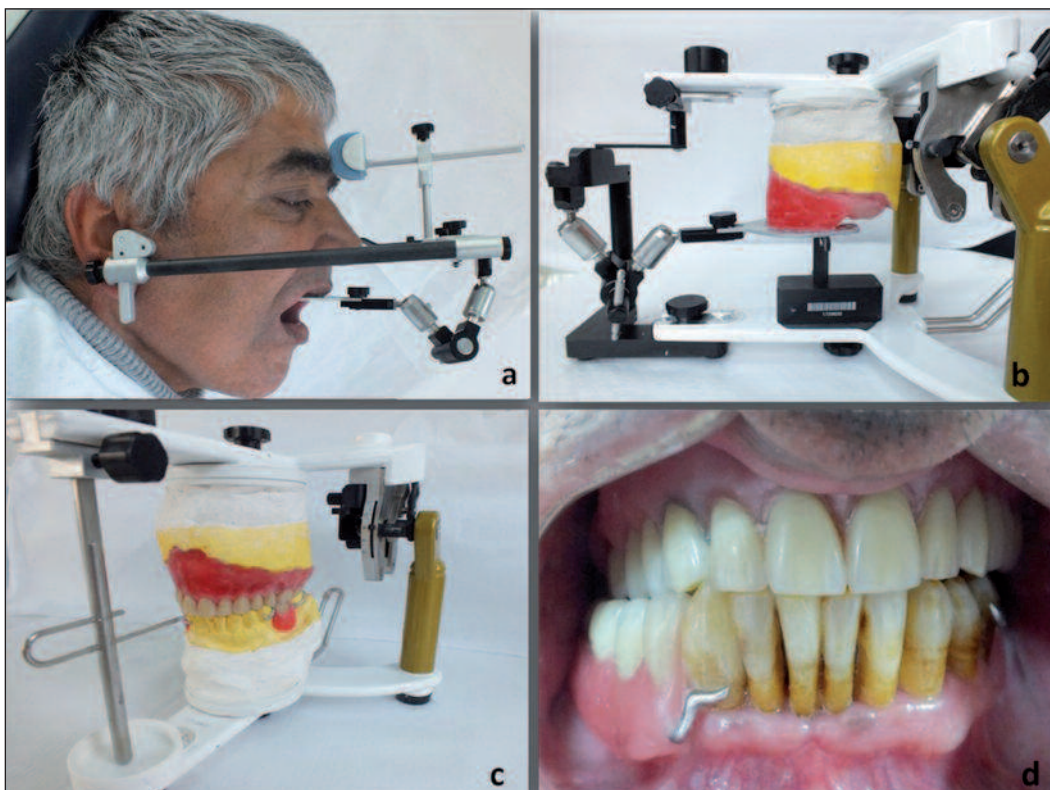
## CASE REPORT

A 47 year-old man was referred to Gazi University, Faculty of Dentistry, Department of Prosthodontics. The patient reported a medical history of squamous cell carcinoma of the maxillary arch which was surgically resected. In the intra oral assessment; it was examined that there were eight teeth (mandibular incisors and canines, left first and second bicuspid and left second molar) in mandible and one tooth (maxillary right second molar) was in maxilla (Figure 1a). The clinical examination revealed that the patient's inferior and

anterior portion of the right and the left maxilla were resected. The hard palate was completely resected and the soft palate was intact (Figure 1b). No restriction was found in the movement range of the soft palate. Before the prosthetic procedures, prosthesis type had been evaluated. The aim of the prosthodontic treatment plan was to reconstruct the defect and restore oral function as soon as possible while completing the definitive obturator prosthesis. Before the prosthodontic rehabilitation process, vitalities of the teeth were checked and it was seen that all of the teeth were vital. In this clinical report the treatment plan was conventional partial removable prosthesis for maxillae and metal framework retained removable partial denture for mandible. Patient was volunteered for the treatment and he signed constant form. Undercut areas were filled with sponge before taking the impression. Maxillary and mandibular anatomic impressions were taken by using a metal stock tray and irreversible hydrocolloid (Jeltrate Type II; Dentsply, Milford, Del) impression material and a primary cast was retrieved out of it. Then individual trays were made on the casts and impressions were made using irreversible hydrocolloid (Jeltrate Type II; Dentsply, Milford, Del) (Figures 1 c, d). The extension of the maxillary obturator prosthesis was outlined on the maxillary cast. The undercuts on the sides of the defect were blocked with wax and also the internal part of the cavity was painted with a thin layer of wax before making the acrylic record bases. Then a metal base framework was made for mandible. The next step was determining the horizontal and vertical maxillo-mandibular relationships. The face bow was positioned by placing the bite-fork in the patient's mouth (Figure 2a). Three-dimensional position of the maxilla was recorded on the semi-adjustable articulator (Stratos 200; Ivoclar Vivadent, Bürs, Austria) (Figure 2b). A jaw relation was recorded. The maxillomandibular relationship was obtained by laterally manipulating the mandible. Then mandibular arch recordings were transferred to semiadjustable articulator. After this step, waxed up dentures were tested and checked in terms of the criteria retention, stability and comfort in the



**FIGURE 1:** a) Intraoral view. b) Maxillary defect area. c) Individual tray and mandibular second impression d) Individual tray and maxillar second impression.



**FIGURE 2:** a) Facebow is positioned by placing the bite-fork in the patient's mouth. b) Three dimensional position of the maxilla on the semiadjustable articulator. c) Occlusal contacts checking for centric relation position on dental casts. d) Occlusal contacts checking for centric relation position on mouth.



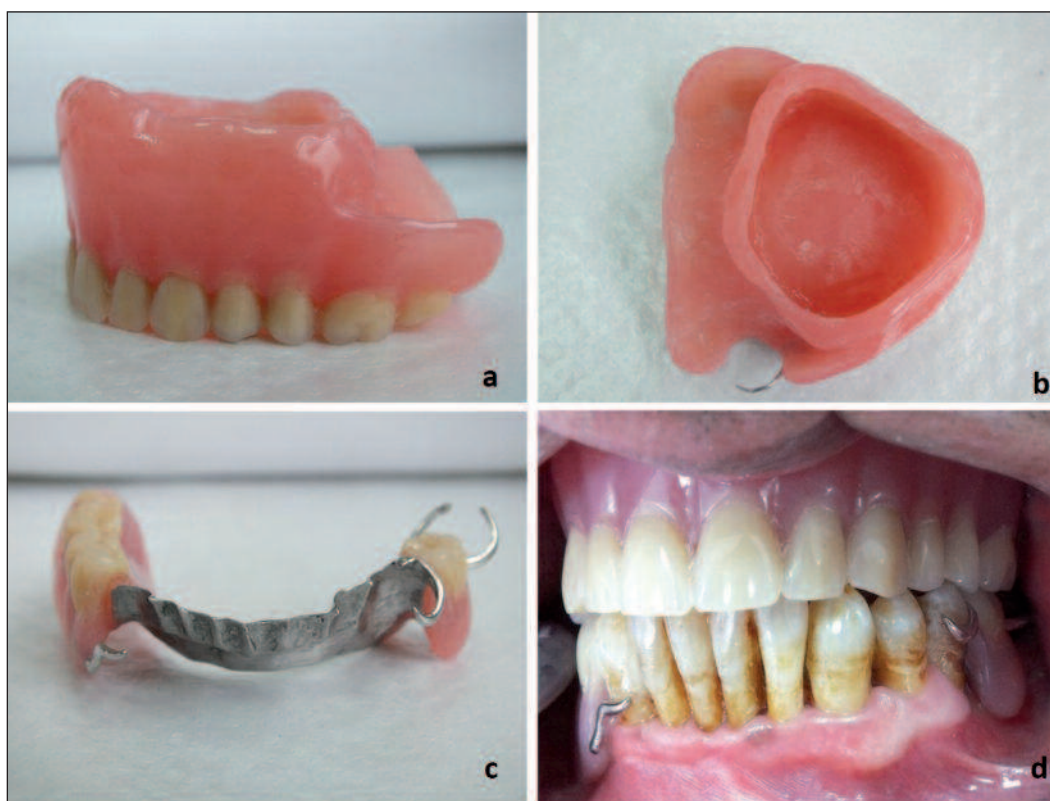
mouth. The patient's left Bennett angle was 21 degrees and right Bennett angle was 13 degrees. Anteroposterior inclination was 30 degrees. Afterwards, the most important step was to check the agreement of occlusal contacts in centric relation position between the dental casts and the mouth (Figures 2 c, d). The patient's occlusion was set to bilateral balanced occlusion in order to increase the stability of removable prostheses. For this purpose, the teeth presenting contacts in this position were initially checked with the aid of acetate sheets and identified with articulating paper. These procedures were then repeated in the mouth. The denture movements were rechecked during phonation, and corrections were made accordingly. Both the maxillary and the mandibular dentures were finished, polished and kept aside (Figures 3 a-d).

Patient satisfaction was evaluated with respect to the aesthetic aspect of facial contour after the re-

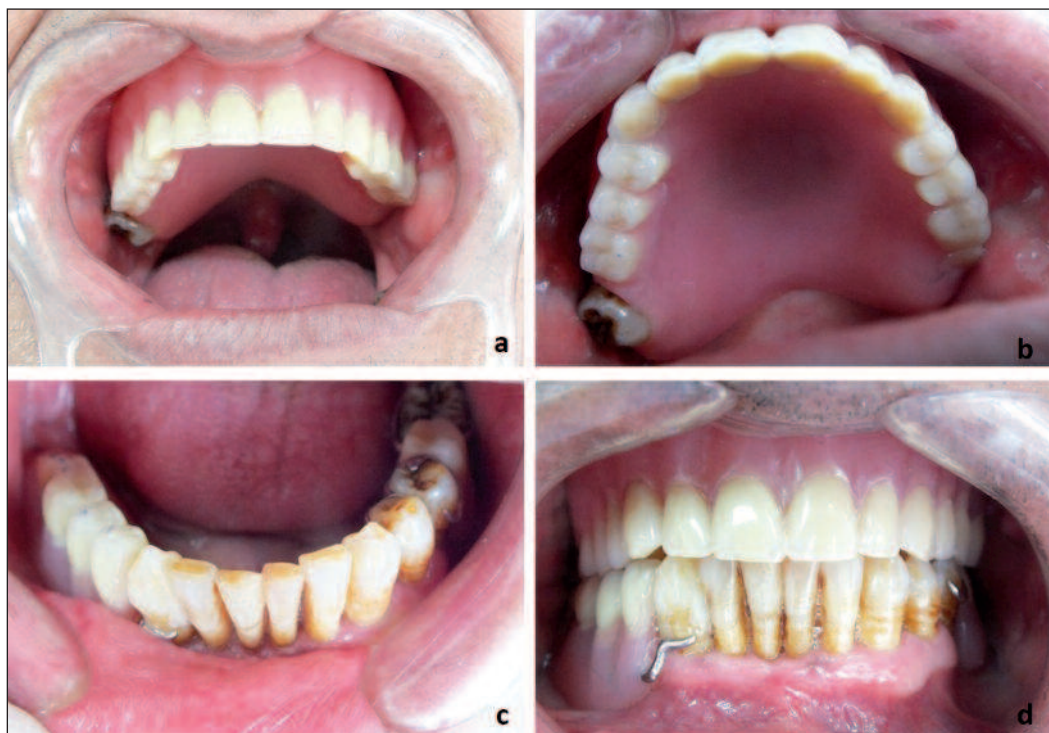
construction and it was seen that both functional and aesthetic results of the obturator prosthesis were adequate. The patient was controlled after 6 months of the insertion of the prosthesis. The prosthesis reestablished the speech, solved the swallowing problem, enabled the patient to mastication difficulties and restored an aesthetically smile. Consequently, the patient gets satisfaction except for complaint of mouth sore.

## DISCUSSION

Maxillofacial prosthodontic rehabilitation of bilateral maxillectomy defects is reported rarely.<sup>9</sup> Cheng et al. described the clinical management of a patient with a bilateral maxillectomy in their article published in 2004. Furthermore, D'Agostino et al. reported that the successful implant supported prosthetic rehabilitation of a patient who underwent bilateral maxillectomy for an oral squamous cell carcinoma.<sup>10,11</sup>



**FIGURE 3:** Definitive prostheses. **a)** Lateral view of maxillary removable prosthesis. **b)** Ground plan of removable maxillary prosthesis **c)** Mandibular removable prosthesis. **d)** Prostheses are in situ.



**FIGURE 4:** a) Frontal view of maxillary removable prosthesis is in situ. b) Occlusal view of maxillary removable prosthesis is in situ. c) Occlusal view of mandibular removable prosthesis is in situ. d) Maxillary and mandibular prostheses are in situ.

Bilateral complete maxillary resections involving the maxillae, hard palate, and paranasal sinuses show unusual surgical and prosthodontic rehabilitation difficulties.<sup>12</sup> The maxillectomy defects can be reconstructed by a prosthetic obturator or free flap transfer, but the optimal method is not uniquely determined.<sup>1</sup> The decision of which treatment method should be chosen is related with the patient characteristics for example age, medical history, and defect size and depends on the surgeon's technical expertise.<sup>13-15</sup>

Surgical reconstruction with composite free flaps carries the risk of donor-site morbidity which can compromise quality of life.<sup>16</sup> Moreover, this treatment method is complex, recovery time is longer, and missing teeth can be difficult to be restored.<sup>3</sup> On the other hand, fabrication of obturator prostheses makes the procedure time shorter as well as offering the chance of immediate and adequate dental treatment.<sup>17</sup> As a result, the reconstructions of such bilateral maxillary defects with obturator prostheses have become valuable means for the rehabilitation of these patients. These pros-

theses improve the ability of chewing function and phonation and preserve psychological well-being.

Insufficient retention, support, and stability are usual prosthodontic difficulties for a bilateral complete maxillectomy patient.<sup>10</sup> Ortegon et al. describe several methods for the retention of a bilateral complete obturator, which can be supported by using the remaining teeth and mouth structures, supporting the obturator with a lateral healing band such as extending the prosthesis extra-orally within the nasal fossa or fixing it to osteointegrated implants.<sup>18</sup> Therefore, remaining tooth with insufficient bone support was left in the mouth in the treatment plan. By the existence of this tooth the retention and stability of the prosthesis were improved. Since anatomic form of the tooth and its undercut can't be imitated and patients consent isn't taken because the increase of treatment duration, restoration of this tooth could not be done. Another method for the retention of large obturator prostheses is extending the prosthesis through the bilateral undercut areas. In situations where the lateral undercuts are more severe, block-out of un-

dercut areas for insertion might be required.<sup>10</sup> In this clinical report, due to severe bilateral undercuts, the undercut areas were blocked-out.

Weight is one of the main problem of an obturator maxillary prosthesis. As the defect gets larger the prosthesis gets heavier. For defects with over a certain size the capacity of retention of the substructures and residual elements gets defeated by the force of gravity.<sup>19</sup> With the purpose of reducing the weight we aim to create an obturator to be able to maintain the weight of the prosthesis within acceptable values. Moreover, with this technique patient's phonation can be enhanced by a harmonic resonance box.

Prosthetic prognosis is affected by the volume and location of postsurgical bony anatomy, availability of abutment teeth, size of the defect,

quality of mucosa, history of therapeutic radiation therapy, and the patient's neuromuscular control.<sup>10</sup> Since abutment tooth is present, retention could be provided despite a large defect, and the patient have a desirable neuromuscular control due to the fact that his age, prosthodontic prognosis is successful in the present case. Bilateral maxillary resections present unusual difficulty in prosthetic rehabilitations. The purpose of prosthetic rehabilitation include recreate the partition between the oral cavity and nasal cavity to allow adequate deglutition and articulation of teeth, restore facial contour, improve speech intelligibility and a satisfactory aesthetic outcome. The patient stated that the prostheses provided that not only the appropriate support, stability, and retention but also the psychosocial well being.

## REFERENCES

- Kreeft AM, Krap M, Wismeijer D, Speksnijder CM, Smeele LE, Bosch SD, et al. Oral function after maxillectomy and reconstruction with an obturator. *Int J Oral Maxillofac Surg* 2012;41(11):1387-92.
- Fierz J, Hallermann W, Mericske-Stern R. Patients with oral tumors. Part 1: prosthetic rehabilitation following tumor resection. *Schweiz Monatsschr Zahnmed* 2013;123(2):91-105.
- Chigurupati R, Aloor N, Salas R, Schmidt BL. Quality of life after maxillectomy and prosthetic obturator rehabilitation. *J Oral Maxillofac Surg* 2013;71(8):1471-8.
- Brauner E, Valentini V, Jamshir S, Battisti A, Guarino G, Cassoni A, et al. Two clinical cases of prosthetic rehabilitation after a tumor of the upper maxilla. *Eur Rev Med Pharmacol Sci* 2012;16(13):1882-90.
- Dobbs J, Barnet A, Ash D. Chapter 11: Oral Cavity. *Practical radiotherapy planning*. 3<sup>rd</sup> ed. Arnold, London: Oxford University Press; 1999. p.108-21.
- Nagler RM. The enigmatic mechanisms of irradiation induced damage to major salivary glands. *Oral Dis* 2002;8(3):141-6.
- Anneroth G, Holm LE, Karlsson G. The effect of radiation on teeth. A clinical, histological, and microradiographic study. *Int J Oral Surg* 1985;14(3):269-74.
- Epstein JB, Lunn R, Le N, Stevenson-Moore P. Periodontal attachment loss in patients after head and neck radiation therapy. *Oral Surg Oral Med Oral Pathol Endod* 1998;86(6):673-7.
- Kirchner JA. Prosthetic replacement of bilateral maxillectomy. *Otolaryngol Head Neck Surg* (1979) 1980;88(1):37-9.
- Cheng AC, Somerville DA, Wee AG. Altered prosthetic treatment approach for bilateral complete maxillectomy: a clinical report. *J Prosthet Dent* 2004;92(2):120-4.
- D'Agostino A1, Procacci P, Ferrari F, Trevisiol L, Nocini PF. Zygoma implant-supported prosthetic rehabilitation of a patient after subtotal bilateral maxillectomy. *J Craniofac Surg* 2013;24(2):59-62.
- Panje WR, Hetherington HE, Toljanic J, LaVelle WE, Fyler A. Bilateral maxillectomy and midfacial reconstruction. *Ann Otol Rhinol Laryngol* 1995;104(11):845-9.
- Ali A, Fardy MJ, Patton DW. Maxillectomy--to reconstruct or obturate? Results of a UK survey of oral and maxillofacial surgeons. *Br J Oral Maxillofac Surg* 1995;33(4):207-10.
- Devlin H, Barker GR. Prosthetic rehabilitation of the edentulous patient requiring a partial maxillectomy. *J Prosthet Dent* 1992;67(2):223-7.
- Okay DJ, Genden E, Buchbinder D, Urken M. Prosthetic guidelines for surgical reconstruction of the maxilla: a classification system of defects. *J Prosthet Dent* 2001;86(4):352-63.
- Rogers SN, Lakshmiah SR, Narayan B, Lowe D, Brownson P, Brown JS, et al. A comparison of the long-term morbidity following deep circumflex iliac and fibula free flaps for reconstruction following head and neck cancer. *Plast Reconstr Surg* 2003;112(6):1517-25.
- Depprich R, Naujoks C, Lind D, Ommerborn M, Meyer U, Kübler NR, et al. Evaluation of the quality of life of patients with maxillofacial defects after prosthetic therapy with obturator prostheses. *Int J Oral Maxillofac Surg* 2011;40(1):71-9.
- Ortegon SM, Martin JW, Lewin JS. A hollow delayed surgical obturator for a bilateral subtotal maxillectomy patient: a clinical report. *J Prosthet Dent* 2008;99(1):14-8.
- Tirelli G, Rizzo R, Biasotto M, Di Lenarda R, Argenti B, Gatto A, et al. Obturator prostheses following palatal resection: clinical cases. *Acta Otorhinolaryngol Ital* 2010;30(1):33-9.