

Blind-Ended Bifid Ureter: Case Report

Kör Sonlanan Bifid Üreter

Cenk Murat YAZICI,^a
Arda KAYHAN,^b
Çağrı DOĞAN,^a
Rumeysa ALPARSLAN^b

Departments of
^aUrology,
^bRadiology,
Namık Kemal University
Faculty of Medicine, Tekirdağ

Geliş Tarihi/Received: 28.12.2012
Kabul Tarihi/Accepted: 12.04.2013

Yazışma Adresi/Correspondence:
Cenk Murat YAZICI
Namık Kemal University
Faculty of Medicine,
Department of Urology, Tekirdağ,
TÜRKİYE/TURKEY
drckenkyazici@yahoo.com

ABSTRACT Blind-ended bifid ureter is a rare congenital ureteral anomaly that is mostly asymptomatic. Premature branching of ureteral bud cause incomplete interaction between newly formed ureteral bud and metanephric mezenchyme causing a blind-ending ureter without a functional renal unit. There are nearly 200 cases reported in literature and most of the patients were diagnosed with invasive radiological techniques. This anomaly is more frequently diagnosed at third and fourth decade with female predominance. Although, most of the patients are asymptomatic, recurrent urinary tract infections, poorly defined abdominal or flank pain, incontinence, hematuria and renal colicky pain can be seen at symptomatic patients. In this case, we reported an asymptomatic blind-ended bifid ureter in which a non-invasive, radiation free radiological technique had been used for diagnosis of this rare anomaly.

Key Words: Ureter; magnetic resonance imaging; congenital

ÖZET Kör sonlanan bifid üreter, genellikle asemptomatik olan ve nadir görülen bir konjenital üreteral anomali çeşididir. Üreteral tomurcuklanmanın erken oluşması sonucu, metanefrik mezenkim ile üreteral tomurcuk etkileşiminin tamamlanamaması, kör sonlanan bifid üreter oluşumunda ana mekanizmayı oluşturmaktadır. Literatürde yaklaşık 200 vaka sunulmuş olup, bu hastaların çoğunda tanının invaziv radyolojik tekniklerle konulduğu bildirilmiştir. Kör sonlanan bifid üreter anomalisi sıklıkla üçüncü veya dördüncü dekatta tanı almakta ve kadınlarda daha sık gözlenmektedir. Tanımlanan vakaların çoğu asemptomatik olsa da, semptomatik hastalarda tekrarlayan idrar yolu enfeksiyonları, kesin tariflenemeyen abdominal veya flank ağrı, idrar kaçırma, hematüri ve renal kolik ağrı gözlenebilmektedir. Bu olgu sunumunda, non-invaziv, radyasyon bulundurmeyen radyolojik teknik ile tanısı konulan, asemptomatik kör sonlanan bifid üreter vakası tanımlanmaktadır.

Anahtar Kelimeler: Üreter; manyetik rezonans görüntüleme; konjenital

Türkiye Klinikleri J Urology 2013;4(1):43-6

Blind-ending bifid ureter is a rare embryologic anomaly among ureteral pathologies. Approximately two hundred cases had been described to date. It is believed that, blind-ending bifid ureter is more often than it is documented because most of the patients are asymptomatic. In this case report, we tried to demonstrate an asymptomatic blind-ending bifid ureter which was detected incidentally.

CASE REPORT

A 45 years old female patient was consulted to our clinic by internal medicine, because of microscopic hematuria detected in routine evaluation of di-

abetes. There was no clinical abnormality in the history of patient and her physical examination was totally normal. She was using oral antidiabetic and antihyperlipidemic medication for her primary diseases. There was only microscopic hematuria on urinalysis and her urine culture was sterile. Biochemical evaluations including blood urea nitrogen and blood creatinine levels were normal. We performed a direct urinary system graphy for the evaluation of hematuria, which demonstrated a 0.9 cm. opacity located in the right lower portion of the pelvic grim (Figure 1a). As there was no abnormality in urinary system ultrasonography, we performed an intravenous pyelography for the differential diagnosis of ureter stone. As the opacity observed out of urinary system, we surprisingly detected a blind-ending bifid ureter located in the middle portion of right ureter with its blind end extending cranially (Figure 1b). After the detection of blind-ending bifid ureter we re-questioned the patient about the possible symptoms that can be related with this embryological anomaly and found that patient was totally asymptomatic. To determine the anatomic properties of blind-ending bifid ureter, we performed magnetic resonance urography (MRU) (Figure 1 c,d). In this radiological evaluation we were able to distinguish the blind-ending bifid ureter extending from middle ureter to the level of upper ureter. It was easily seen that both ureter share the same ureteral sheet. As the patient was asymptomatic, we performed semirigid ureteroscopy and pneumatic lithotripsy for lower ureteric stone and followed the patient conservatively. Patient was asymptomatic at the third and sixth month of follow-up, without microscopic hematuria.

DISCUSSION

Blind-ended bifid ureter is an ureteral pathology related with an embryological development anomaly. Ureteric bud appears as an epithelial protrusion of the Wolffian duct in 28th day of embryological life. As it moves cranially, it reaches metanephric mezenchyme forming ureter, renal pelvis, calices and collecting tubules. At this period, glomeruli, proximal tubules, Henle loop and distal tubules develop from metanephric mezenchymal part of this interac-

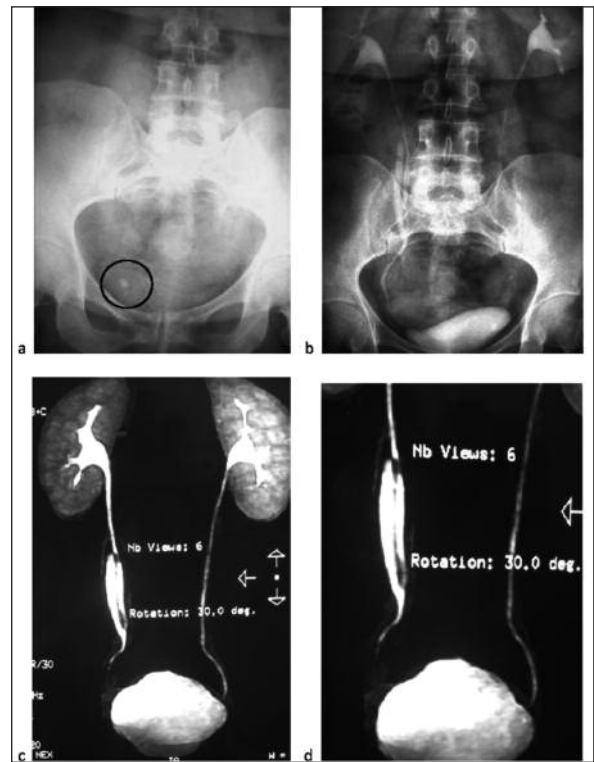


FIGURE 1: Radiological evaluation of patient. **a.** Direct graphy demonstrating opacity in pelvis. **b.** Intravenous pyelography with blind-ending bifid ureter. **c,d.** Magnetic resonance urography demonstrating anatomical properties of blind-ending bifid ureter.

tion. If premature branching of ureteral bud occurs, this may cause incomplete interaction between newly formed ureteral bud and metanephric mezenchyme causing a blind-ending ureter without a functional renal unit.¹ From histomorphological aspect, Culp defined the blind-ended bifid ureter as; it has the same histological properties of normal ureter, its length is greater than twice of its diameter and it joins to the native ureter with a sharp angle.² Congenital diverticulum was thought to be different entity from blind-ended bifid ureter, but Rank et al. showed that they may arise from the same embryological anomaly in their histological study.^{3,4}

Although, nearly 200 cases had been reported, blind-ending ureter is thought to be more frequent.⁵ From the data reported in the literature, these congenital anomalies were diagnosed three times more frequently in women. Anatomically they were seen twice as common on the right side, mostly originating from middle and distal ureter.⁶

Even it was mostly diagnosed in 3. and 4. decades of life, there were also some reported cases detected in childhood.^{5,7,8} According to age of diagnosis and anatomic properties of the blind-ended bifid ureter, our patient was consistent with the literature.

Most of the patients with blind-ending bifid ureter are asymptomatic. However recurrent urinary tract infections, poorly defined abdominal or flank pain, incontinence, hematuria and renal colicky pain can be seen at symptomatic patients. Abdominal and flank pain can be related with the reflux to blind-ended ureter from native ureter because of asynchronous peristalsis. Stone formation in a blind ending ureter, even the presence of transitional cell carcinoma had been reported in the literature.⁹ In our patient there was no symptom except microscopic hematuria detected incidentally. As microscopic hematuria disappeared during follow-up, our patient became totally asymptomatic.

Our patient was incidentally documented to have blind-ended bifid ureter during the evaluation of microscopic hematuria. A lower ureteric stone was diagnosed at the ipsilateral of blind-ended bifid ureter. An ureteroscopy and pneumatic lithotripsy was performed without any complication. Ureter stone with bifid ureter is not a rare combination. Even the presence of ureteric stone can be a cornerstone for incidental diagnosis of this congenital anomaly. It may cause colicky pain and recurrent urinary tract infection. Reflux from the main ureter to the blind ended section was proposed to lead a urinary retention and may cause loin pain, urinary tract infection and stone formation.¹⁰ Asynchronous peristalsis in the two ureteric limbs may be another explanation for urinary retention and stone formation.¹¹ Microscopic hematuria due to ureteric stone was the reason of incidental diagnosis of blind-ended bifid ureter and the stone was successfully treated without any problem.

In some cases, intravenous pyelography may not be enough for diagnosis and further evaluation may be warrant. Retrograde pyelography, which is an invasive technique, is preferred for further radiological evaluation of these patients. However, Chang et al. reported that CT urography can be used

for the diagnosis of bifid ureter as a non-invasive technique.¹² We performed MRU to our patient. By this non-invasive and radiation-free method, we were able to evaluate the anatomical properties of blind-ended bifid ureter in our patient. Magnetic resonance urography has the potential to revolutionize imaging of the urinary tract because of its ability to provide anatomic information and quantitative functional evaluation of each kidney. It enables the assessment of obstructive uropathy.¹³ It has the potential to noninvasively assess the urinary collecting system, renal parenchyma and surrounding structures without the use of ionizing radiation.¹⁴ The clinical applications of MRU are urolithiasis, urinary tract obstruction unrelated to urolithiasis, hematuria, congenital anomalies. Magnetic resonance urography may be used as a first choice diagnostic modality for demonstrating upper urinary tract malformations and variants. It enables to noninvasively obtain multiplanar detailed images and provides a comprehensive overview of the urinary system. Additionally, it is a beneficial imaging technique in the patients with a history of adverse reaction to iodinated contrast material and it does not use ionizing radiation.^{15,16} The limitation of the system is the lower spatial resolution compared with CT and radiography. In the current case, MRU was performed as an incremental modality to differentiate a bifid ureter and duplex ureter as well as to locate the bifurcation point accurately. We suggest that MRU may be sufficient in diagnosis of such cases and it may decrease the need for an invasive procedure.

Surgical excision is required in symptomatic patients. Although open surgical technique had been used for the excision of blind-ended double ureter, Adam et al. reported that laparoscopy can safely be used for this surgery.¹⁷ It should be noted that, both blind-ended and native ureter proceed in the same Waldeyer's sheath and supplied by the same arterial source. So excision should be performed without disturbing the blood supply to the native ureter. For this purpose, it is recommended to start dissection from cranial region of bifid ureter. As our patient was asymptomatic, surgical excision was not performed.

REFERENCES

1. Peterson LJ, Grimes JH, Weinerth JL, Glenn JF. Blind-ending branches of bifid ureters. *Urology* 1995;5(2):191-5.
2. Culp OS. Ureteral diverticulum classification of the literature and report of an authentic case. *J Urol* 1947;58(5):309-21.
3. Arda K, Akbay E, Tahtalı N, Tekin T, Erol A, Yürür H. [Blind-Ending Bifid Ureter: Case Report] *Türkiye Klinikleri J Med Sci* 1993; 13(5): 418-20.
4. Rank WB, Mellinger GT, Spiro E. Ureteral diverticula: etiologic considerations. *J Urol* 1960; 83:566-9.
5. Kiliçarslan H, Ayan S, Gökçe G, Kaya K, Gültekin EY. Cranial blind-ending branch of a bifid ureter. *Int Urol Nephrol* 2001;32(4):635-6.
6. Ozmen E, Ozkardeş H, Ozkan S, Ozen HA. Calculi in a blind-ending limb of a duplicated ureter. *Scand J Urol Nephrol* 1993;27(4):541-2.
7. Rege VM, Deshmukh SS, Borwankar SS, Gandhi RK. Blind ending bifid ureter (a case report). *J Postgrad Med* 1986;32(4): 233-5.
8. Lam HS. Bifid blind-ending ureter--a case report. *Singapore Med J* 1991;32(1):84-6.
9. Kawamura H, Sasaki N. Transitional cell carcinoma in the blind-ending branch of the bifid ureter. *Br J Urol* 1998;82(2):307-8.
10. Wespes E, De Sy W, Thiry AJ, Schulman CC. Blind ending bifid and double ureters. *Urology* 1983;21(6):586-9.
11. Lenaghan D. Bifid ureters in children: an anatomical, physiological and clinical study. *J Urol* 1962;87:808-17.
12. Chang E, Santillan C, O'Boyle MK. Blind-ending branch of a bifid ureter: multidetector CT imaging findings. *Br J Radiol* 2011;84(998): e38-40.
13. Grattan-Smith JD, Jones RA. MR urography: technique and results for the evaluation of urinary obstruction in the pediatric population. *Magn Reson Imaging Clin N Am* 2008; 16(4):643-60.
14. Leyendecker JR, Barnes CE, Zagoria RJ. MR urography: techniques and clinical applications. *Radiographics* 2008;28(1):23-46.
15. Nolte-Ernsting CCA, Staatz G, Tacke J, Günther RW. MR urography today. *Abdom Imaging* 2003;28(2):191-209.
16. Verswijvel GA, Oyen RH, Van Poppel HP, Goethuys H, Maes B, Vaninbrouckx J, et al. Magnetic resonance imaging in the assessment of urologic disease: an all-in-one approach. *Eur Radiol* 2000;10(10)1614-9.
17. Perlmutter AE, Parousis VX, Farivar-Mohseni H. Laparoscopic retroperitoneal resection of blind-ending bifid ureter in patient with recurrent urinary tract infections. *Urology* 2005; 65(2):388.