

An Unusual Cause of Restriction of Shoulder Motion, Intraarticular Osteochondroma

 Kemal ŞİBAR^a,  Erkan AKGÜN^a

^aAnkara Etlük City Hospital, Clinic of Orthopaedics and Traumatology, Ankara, Türkiye

ABSTRACT A 53 years-old woman presented with pain and restriction of left shoulder range of motion to our clinic. Complaints increasing gradually over the past four years. She had been diagnosed with frozen shoulder at different clinics from the beginning and she had received ineffective treatments. A rare diagnosis of intraarticular osteochondroma of proximal humerus was found and a surgical excision was performed. The occurrence of intraarticular osteochondroma in the glenohumeral joint is quite uncommon. This report will contribute to the literature in terms of osteochondroma being in an unusual location and growth occurring after skeletal maturity without undergoing malignant transformation.

Keywords: Osteochondroma; shoulder; range of motion, articular

Osteochondromas are the most common benign bone tumors and represent approximately 50% of them.^{1,2} Osteochondromas are benign lesions characterized by hyaline cartilage caps. They typically occur in the metaphyseal region of the bones. The presence of cortical and medullary continuity with the underlying bone are distinctive characteristics.^{3,4} Typically, these lesions manifest prior to reaching 20 years of age and are not anticipated to increase in size once skeletal maturity is complete.^{1,5} Typically, they exist solitary, but in 10-15% of instances, they might manifest as several growths, such as in the case of hereditary multiple exostoses.⁶

Osteochondromas are primarily asymptomatic and typically detected as an incidental finding on X-rays.² In symptomatic patients, symptoms such as bursitis, neurovascular symptoms, pain, and limitation of joint movement are usually caused by mechanical pressure on nearby structures or malignant

transformation.¹⁻³ The proximal humerus is the third most frequent location for osteochondromas, behind the distal femur and proximal tibia.⁷ Osteochondromas are uncommon outside of the metaphysis, and intra-articular osteochondromas are even more infrequent. While there have been a limited number of case reports of osteochondromas found within the knee, elbow, hip, and ankle joints, to our knowledge, there are only two case reports of osteochondromas within the shoulder joint.^{7,8}

In this report, we present a case of a patient who complained tenderness in the axillary region, restricted range of motion (ROM), and shoulder pain caused by an intraarticular osteochondroma of the proximal humerus after reaching skeletal maturity.

The patient was informed that data concerning the case would be submitted for publication, and he provided consent.

Correspondence: Kemal ŞİBAR

Ankara Etlük City Hospital, Clinic of Orthopaedics and Traumatology, Ankara, Türkiye

E-mail: kemalsibar@gmail.com

Peer review under responsibility of Türkiye Klinikleri Journal of Case Reports.

Received: 16 May 2024

Accepted: 28 May 2024

Available online: 31 May 2024

2147-9291 / Copyright © 2024 by Türkiye Klinikleri. This is an open access article under the CC BY-NC-ND license (<http://creativecommons.org/licenses/by-nc-nd/4.0/>).



CASE REPORT

A 53 years-old woman, with no history of trauma, presented with the pain and restriction of left shoulder ROM to our clinic. Pain and limitation of movement had been increasing gradually over the past four years and tenderness at the axillary region had been started for the last six months. Upon reviewing the patient's medical history, it was observed that she had been diagnosed with frozen shoulder at various clinics from the onset of her symptoms. Additionally, she had undergone two rounds of physical therapy and received two intra-articular corticosteroid injections.

On physical examination, when evaluated in comparison with the other side; forward flexion and abduction were limited to 90 degrees, internal and external rotation was limited to 30 degrees. Loss of muscle strength was not detected.

Anterior-posterior X-ray imaging of the left shoulder showed a mass originating from the medial part of the anatomical neck of the humerus (Figure 1A). A computed tomographic (CT) scan verified the presence of exostosis on the anatomical neck of the humerus, extending towards the axillary region (Figure 1B). The CT scan also revealed glenohumeral arthritic alterations. Magnetic resonance imaging (MRI) demonstrated cortical and medullary continuity between the lesion and the underlying bone (Figure 1C). Furthermore, there was an 8 mm cartilage cap present on the lesion.

We used a deltopectoral incision and reached the intraarticular osteochondroma after the partial release of latissimus dorsi and inferior part of subscapularis muscle (Figure 2A). The lesion was completely excised and the size of the lesion was approximately 4x4 cm (Figure 2B). Joint capsule, latissimus dorsi and subscapularis muscles repaired after lesion exci-

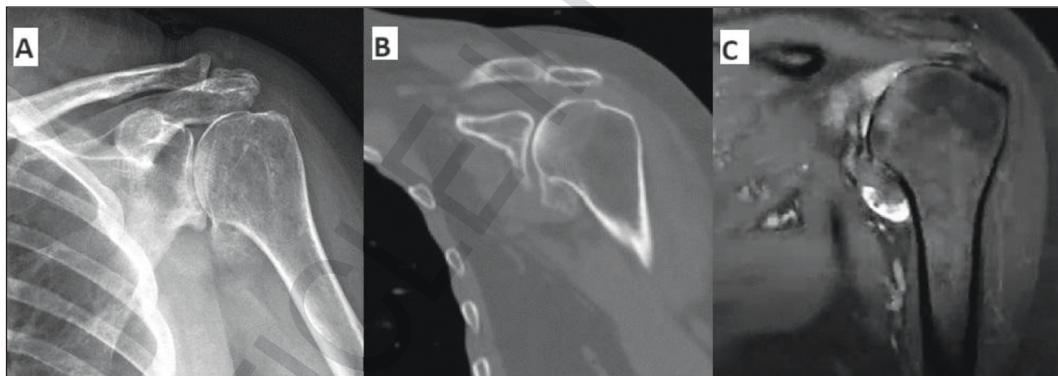


FIGURE 1: A) Anterior-posterior X-ray imaging of the left shoulder showed a mass originating from the medial part of the anatomical neck of the humerus. B) The coronal computed tomographic scan shows the intraarticular osteochondroma along the medial aspect of the anatomical neck of humerus. C) The coronal magnetic resonance imaging demonstrated cortical and medullary continuity between the lesion and the humerus.

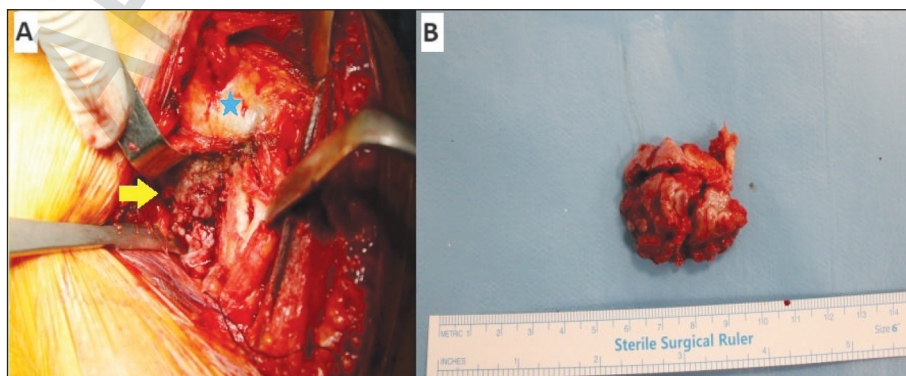


FIGURE 2: A) Intraoperative image of intraarticular osteochondroma. Yellow arrow: osteochondroma. Blue asterisk: humeral head. B) Total excised osteochondroma, approximately 4x4 cm.

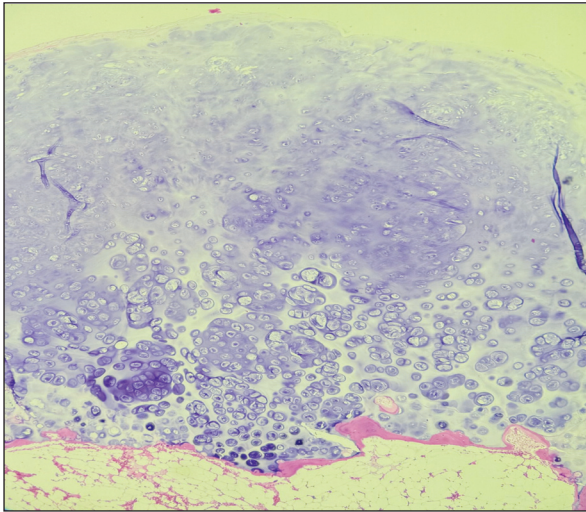


FIGURE 3: The histopathologic examination shows the lesion had a cartilage cap devoid of any indications of necrosis. There was no atypia or binucleate chondrocytes were found.

sion and axillary nerve was not exposed during the surgery. Histopathological evaluation confirmed the diagnosis of osteochondroma (Figure 3). The lesion had a cartilage cap devoid of any indications of necrosis. There was no atypia or binucleate chondrocytes were found.

The patient achieved full restoration of their normal ROM within a period of 8 weeks with physical therapy following the surgical procedure. One year after the surgery she remained free of any symptoms.

DISCUSSION

Proximal humerus is the third most common site for osteochondromas.⁷ Osteochondromas are usually located on the long bones, and the majority occur around the knee joint. They tend to settle in the metaphysis and grow away from the joint to the adjacent joint.^{9,10} The occurrence of an osteochondroma within the glenohumeral joint is exceptionally uncommon. To our knowledge there are only two case reports in the literature that presenting an intraarticular osteochondroma of the glenohumeral joint.^{7,8}

In our patient, similar to previously documented case reports, the intraarticular osteochondroma was located on the medial aspect of the anatomical neck of the humerus. This resulted in pain and restricted joint movement. However, it is worth noting that our patient had been suffering these symptoms for a very

extensive period of time. There had been many unsuccessful treatment attempts that includes intraarticular injections and physical therapies due to misdiagnosis. From the patient's medical records, we obtained X-ray images from the time her complaint started and confirmed that the lesion was smaller. Inattentively evaluated X-rays may fail to detect small lesions. The presence of pain, restricted shoulder ROM, and the feeling of tension in the axillary region during maximum abduction, similar to frozen shoulder, may have caused the clinicians to make a misdiagnosis.

Osteochondromas are usually asymptomatic and typically detected incidentally on radiographic images that were taken for unrelated causes.² In symptomatic patients, complaints may occur due to mechanical compression on adjacent tissues. Lesion can cause compression of the vascular structures, leading to the pulselessness, thrombosis, or discoloration of the extremity. Furthermore, nerve compression can lead to the occurrence of tingling and numbness.^{11,12} Sometimes, compression of the surrounding tissues can lead to pathologies related to bursa.³ In this report, we think that the causes of the symptoms are glenohumeral arthritic formation, the direct impingement between the mass and the glenoid and the tension caused by the mass growing towards the axillary recess.^{7,8}

Different radiological methods can be used for the diagnosis of osteochondroma. X-rays are typically adequate for diagnosis.¹ Osteochondromas, typically manifest as a clearly defined protrusion on the outer surface of a bone.¹³ CT is a powerful tool for detecting malignancies in anatomical regions that are challenging to visualize using plain radiographs such as shoulder. CT can be used to assess the presence of a cartilage cap and determine if it has calcification.¹⁴ MRI gives information about medullary and cortical continuity between the lesion and parent bone which is pathognomonic feature for osteochondroma.¹⁵ The radiological imaging of our patient, as described in this report, exhibited characteristic attributes of osteochondroma.

In differential diagnosis, it was thought that the mass may be osteophyte due to primary arthritis, but the joint was not affected by totally and the glenoid

was affected by progressive mass growth within 5 years. In addition the pathology report confirmed our diagnosis of osteochondroma. Likewise, our patient was evaluated in terms of hereditary multiple exocytosis (HME). There was no family history of our patient and no mass was detected in other extremities. Approximately 80% of HME cases had exocytosis at first decade.⁶ Our patient had a mass in the fifth decade.

The occurrence of malignant transformation is observed in around 1% of solitary osteochondroma cases.² If there is any growth in the mass after skeletal maturation, the presence of a cartilage cap thicker than 2 cm, or a new-onset pain in a known osteochondroma area, evaluation should be made in terms of malignant transformation to chondrosarcoma.^{3,15} In our patient, although there was a painful mass that started to grow in the fifth decade, the cartilage thickness was around 8 mm and histopathological examination showed results consistent with benign osteochondroma. In our case, surgical excision has been performed due to progressive pain and limited ROM.

To summarize, the occurrence of intraarticular osteochondroma in the glenohumeral joint is quite

uncommon. This report will contribute to the literature in terms of osteochondroma being in an unusual location and growth occurring after skeletal maturity without undergoing malignant transformation. To our knowledge, our case is the third case report in the literature in which the patient's entire history, physical examination findings, radiological imaging findings, intraoperative imaging and histopathological findings are reported.

Source of Finance

During this study, no financial or spiritual support was received neither from any pharmaceutical company that has a direct connection with the research subject, nor from a company that provides or produces medical instruments and materials which may negatively affect the evaluation process of this study.

Conflict of Interest

No conflicts of interest between the authors and / or family members of the scientific and medical committee members or members of the potential conflicts of interest, counseling, expertise, working conditions, share holding and similar situations in any firm.

Authorship Contributions

All authors contributed equally while this study preparing.

REFERENCES

1. Murphey MD, Choi JJ, Kransdorf MJ, Flemming DJ, Gannon FH. Imaging of osteochondroma: variants and complications with radiologic-pathologic correlation. *Radiographics*. 2000;20(5):1407-34. PMID: 10992031.
2. Garcia RA, Inwards CY, Unni KK. Benign bone tumors—recent developments. *Semin Diagn Pathol*. 2011;28(1):73-85. PMID: 21675379.
3. Motamedi K, Seeger LL. Benign bone tumors. *Radiol Clin North Am*. 2011;49(6):1115-34, v. PMID: 22024291.
4. Alyas F, James SL, Davies AM, Saifuddin A. The role of MR imaging in the diagnostic characterisation of appendicular bone tumours and tumour-like conditions. *Eur Radiol*. 2007;17(10):2675-86. PMID: 17342487.
5. Woolton-Gorges SL. MR imaging of primary bone tumors and tumor-like conditions in children. *Radiologic Clinics*. 2009;47(6):957-75. doi: 10.1016/j.rcl.2009.08.001
6. Alabdullrahman LW, Mabrouk A, Byerly DW. Osteochondroma. 2019. In: StatPearls [Internet]. Treasure Island (FL): StatPearls Publishing; 2019. <https://europepmc.org/article/NBK/nbk544296>
7. Padua R, Castagna A, Ceccarelli E, Bondi R, Alviti F, Padua L. Intracapsular osteochondroma of the humeral head in an adult causing restriction of motion: a case report. *J Shoulder Elbow Surg*. 2009;18(4):e30-1. PMID: 19131258.
8. Lee JY, Lee S, Joo KB, Lee BG, Baik SS, Bae J. Intraarticular osteochondroma of shoulder: a case report. *Clin Imaging*. 2013;37(2):379-81. PMID: 23465997.
9. Douis H, Saifuddin A. The imaging of cartilaginous bone tumours. I. Benign lesions. *Skeletal Radiol*. 2012;41(10):1195-212. PMID: 22707094.
10. Galasso O, Mariconda M, Milano C. An enlarging distal tibia osteochondroma in the adult patient. *J Am Podiatr Med Assoc*. 2009;99(2):157-61 PMID: 19299355.
11. Göçmen S, Topuz AK, Atabey Ç, Şimşek H, Keklikçi K, Rodop O. Peripheral nerve injuries due to osteochondromas: analysis of 20 cases and review of the literature. *J Neurosurg*. 2014;120(5):1105-12. PMID: 24405073.
12. Mnif H, Koubaa M, Zrig M, Zammel N, Abid A. Peroneal nerve palsy resulting from fibular head osteochondroma. *Orthopedics*. 2009;32(7):528. PMID: 19634838.
13. Tepelenis K, Papathanakos G, Kitsouli A, Troupis T, Barbouti A, Vlachos K, et al. Osteochondromas: an updated review of epidemiology, pathogenesis, clinical presentation, radiological features and treatment options. *In Vivo*. 2021;35(2):681-91. PMID: 33622860; PMCID: PMC8045119.
14. Kitsoulis P, Galani V, Stefanaki K, Paraskevas G, Karatzias G, Agnantis NJ, et al. Osteochondromas: review of the clinical, radiological and pathological features. *In Vivo*. 2008;22(5):633-46. PMID: 18853760.
15. Mehta M, White LM, Knapp T, Kandel RA, Wunder JS, Bell RS. MR imaging of symptomatic osteochondromas with pathological correlation. *Skeletal Radiol*. 1998;27(8):427-33. PMID: 9765135.