

Distribution of melanosomes in different hair types

M.Kemal IRMAK, Hakkı DALCIK, Osman ÖZCAN

Dept. of Histology and Embryology, Giihane Military Medical Academy, Ankara, TURKEY

It is well known that hair color is related to the density and distribution of melanosomes within the keratinocytes. However, no information is available about the distribution of the melanosomes in various hair types. Therefore, we investigated the distribution and the density of the melanosomes in the hairs of the scalp, eyelash and eyebrow by light microscopy. The number of melanosomes in the hairs of the scalp and in the eyebrow were much more than in the eyelashes. The melanosomes were cortically located in the scalp hairs, while they were homogeneously distributed in the other two types. Numerous melanosome aggregations were observed in the hairs of eyebrow. These results suggest that melanosome density and distribution express variations in different hair types. [Turk J Med Res 1995; 13(2): 47-49]

Key Words: Melanosome, Hair

Melanosome is a cellular organelle that is composed of a melanosomal matrix and melanin pigment. The melanosome is formed within the melanocyte and transferred to the surrounding keratinocytes through dendritic processes. Hair color is related to the number, size, type and distribution of melanosomes within the keratinocytes (1,2).

The scalp and eyebrow hairs and eyelashes are thick hairs (3). Thick hairs usually consist of three concentric layers; the medulla, cortex and cuticle. The medulla forms the loose central axis and consists of two or three layers of cuboidal cells. This central part of the hair shaft is absent in thinner hairs and is missing also from some of the hairs of the scalp and from blonde hair. Cortex is the main constituent of the hair and its cells carry most of the pigments of the hair (4). Superficially, there is a single layer of thin clear cells, the cuticle.

Little information is available about the distribution of the melanosomes in various hair types. The present study was designed to investigate the differences in the distribution and density of melanosomes in different hair types of the same individuals. Eyelashes,

scalp and eyebrow hairs were selected for this purpose.

MATERIALS AND METHODS

Three Caucasian male were included in the study. None of the subjects was suffering from any disease or illness. The age range was 30 to 33 years. From each subject hair specimens were taken from scalp, eyebrow and eyelashes. Small portions from each hair shaft were immediately fixed in glutaraldehyde and processed for electron microscopic examination according to standard routines. From each block, five to ten semi-thin cross sections were randomly examined without staining. A stereomicroscope was used to obtain true cross sections of the hair types, since it would be important in determining the hair shape. The distribution and density of melanosomes were compared between the groups and photographed under an Olymplus BHS/F2 microscope.

RESULTS

Examination of the cross sections revealed that the shape of the hair shaft were not uniform between the groups. The scalp hair (Fig. 1) was regular and ovoid and a cuticle was observed around the shaft. The eyelashes (Fig. 2) were also ovoid in shape but had irregular profiles, while the hair shaft of the eyebrow (Fig. 3) appeared to be round and regular. The cuticle was absent in both eyelashes and eyebrow hairs.

Received: Nov. 28, 1994

Accepted: Feb. 4, 1995

Correspondence: M.Kemal IRMAK

Dept. of Histology and Embryology,
Giihane Military Hospital,
Ankara, TURKEY

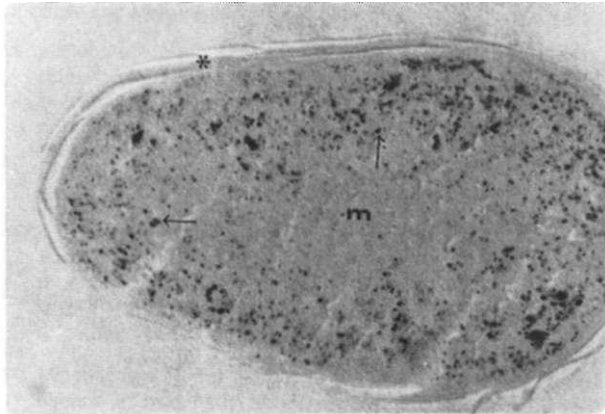


Figure 1. Micrograph of a scalp hair in transverse section, showing a large number of melanosomes in the cortex of the hair (Arrows). Melanosomes were individually distributed in cortex and few melanosomes are present in medulla (m). Asterisk: Cuticle (Unstained plastic section, x1100)

Melanosomes of the scalp hair (Fig. 1) were predominantly present in the cortical area, and only few scattered melanosomes were evident in the medulla. While in the eyelashes (Fig. 2) and in the eyebrow hairs (Fig. 3) the melanosomes were located homogeneously through the shaft.

In every section of the eyelashes, the number of the melanosomes was less than in the scalp and eyebrow hairs. In the scalp hairs and in the eyelashes, most of the melanosomes were independently localized and some were adherent to each other. However the melanosomes of the eyebrow hairs aggregated to form complexes (Fig. 3). The diameter of the melanosomes both in the hairs of the scalp and eyelashes were approximately uniform, while melanosomes of different diameter were observed in the hairs of the eyebrow.

DISCUSSION

Our results provide evidence that the shape of the hair shaft may be different according to the regional localization of the hair in the human body. We demonstrated that the scalp hair was ovoid in shape. This finding is consistent with the literature data, since the appearance of hair in cross section of the wavy hair of many people including Caucasians appears oval (3-5).

It is well documented that pigmentation of the hair is due to the melanocytes located over the tip of the dermal papilla (6). These melanocytes have been shown to liberate their pigment to the cells located in the matrix and the cortex of the hair (7) and hair color depends on the amount and distribution of these melanosomes (8). Blonde hair was demonstrated to contain fewer and incomplete melanized melanosomes and a relative absence of melanin was shown in gray

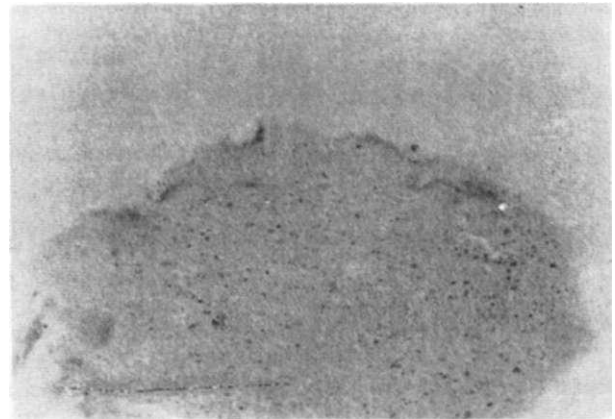


Figure 2. Cross section through the shaft of an eyelash. Few scattered melanosomes were individually distributed throughout the hair (Unstained plastic section, x1100)




Figure 3. The melanosomes were located homogeneously through the shaft and melanosomes aggregate to form melanosome complexes within the shaft of the eyebrow hair (Arrows) (Unstained plastic section, x1100)

hair (8,9). Human melanosomes were demonstrated to be uniformly elongated except in red-haired individuals, in whom they tend to be spherical (10). Melanosomes are somewhat larger in the keratinocytes of Negroids and Mongoloids than they are in Caucasoids (4). Renieri and co-workers (11) have characterized four pigmented phenotypes by examining the density and distribution of the melanosomes of the cattle. Other investigators have demonstrated that within the same individual the melanosomes appear to be larger in the hair follicles than in the skin (12). The purpose of the present study was to provide an additional information about the melanosomes of three different hair types in the same individual. We demonstrated that in the hairs of the eyelash and eyebrow, the melanosomes

homogeneously distributed through the hair shaft; while the melanosomes of the scalp hair were predominantly located in the cortex, and were consistently increased in the outer cortical area. This finding is in agreement with that of Kita and colleagues (13). They demonstrated that cortical cells carry most of the pigment of the hair, and the melanin density of the outer scalp hair cortex was higher than that of the inner hair cortex. In the present study, only the scalp hairs had the cortically distributed melanosomes. However, it is known that eyelashes and eyebrow hairs are also thick hairs and cortical cells must carry most of the pigments of the hair (4). Homogeneous distribution of melanosomes in these types of hairs might show that they have no medulla or medullary cells have the similar density of melanosomes with that of the cortex.

Present study has shown that the number of the melanosomes in the scalp hair and in the eyebrow were much more than in the eyelash. These data are in good agreement with the work of Nanninga and colleagues (14). The same authors demonstrated an increase of alpha melanin stimulating hormone binding sites in the human scalp hair, which is found to be associated with active melanin production. Furthermore, in the human, it was demonstrated that, the small melanosomes often aggregate to form melanosome complexes, while the large melanosomes usually are individually distributed in the cytoplasm of the keratinocytes (10). The present study demonstrates for the first time that, the melanosomes in the hairs of the eyebrow form aggregations.

In conclusion, our data suggest that, the melanosomes in the hairs located in different regions of the human body show morphological variation the significance of which needs to be established.

Çeşitli kıl tiplerinde melanozom dağılımı

Kıl renginin, keratinositlerde bulunan melanozomların yoğunluk ve dağılım farklılığına bağlı olduğu bilinmektedir. Bununla beraber, çeşitli kıl tiplerindeki melanozom dağılımı hakkında literatür bilgisi mevcut değildir. Bu nedenle saç, kaş ve kirpikteki melanozomların morfoloji ve dağılımları ışık mikroskopu düzeyinde araştırıldı. Melanozom sayısı saç ve kaşta, kirpiğe göre daha fazla bulundu. Melanozomların saçta kortikal olarak; kaş ve kirpikte homojen olarak dağıldıkları görüldü. Kaşta bolmiktardır.

da melanozom kümeleşmelerine rastlandı. Bu bulgular, melanozom yoğunluk ve dağılımının farklı kıl tiplerinde değişkenlik sergilediğini göstermektedir. [TurkJMedRes 1995; 13(2): 4749]

REFERENCES

- Ortonne JP, Prota G. Hair melanins and hair color: ultrastructural and biochemical aspects. *J Invest Dermatol* 1993; 101:82S-89S.
- Im S, Lee S, Hann SK et al. The ultraviolet B protection effects of topically applied melanosomes onto human skin. *Yonsei Med J* 1991; 32:330-4.
- Williams PL, Dyson M. GRAY's Anatomy. 37th ed. London: Churchill Livingstone, 1992:1215.
- Fawcett DW. A Textbook of Histology. 11th ed. Philadelphia: WB Saunders, 1986:556-66.
- Lindelöf B, Forslind B, Hedblad MA et al. Human hair form. *Arch Dermatol* 1988; 124:1359-63.
- Fitzpatrick TB, Szabo G, Seiji M et al. Biology of the melanin pigmentary system. In: Fitzpatrick TB et al, eds. *Dermatology in General Medicine*. 2nd ed. New York: McGraw-Hill Book Co, 1979:131.
- Ganong WF. Review of Medical Physiology. Lebanon: Typopress, 1989:340.
- Ackerman AB. Skin, structure and function. In: Ackerman AB, ed. *Histologic diagnosis of inflammatory skin disease*. Philadelphia: Lea&Febiger, 1978.
- Kita T, Hayashiba Y, Ohshima T et al. Determining aging changes of melanin granules of human scalp hairs by image analyser. *Nippon Hoigaku Zasshi* 1991; 45:44-51.
- Snell RS. An electron microscopic study of melanin in the hair and hair follicles. *J Invest Dermatol* 1972; 58:218-22.
- Renieri C, Ceccarelli P, Gargiulo AM et al. Chemical and electron microscopic studies of cattle with four types of phenotypic pigmentation. *Pigment Cell Res* 1993; 6:165-70.
- Billingham RE, Silvers WK. The melanocytes of mammals. *Qt Rev Biol* 1960;35:1-5.
- Kita T, Hayashiba Y, Minoda M et al. Image analytic studies of melanin granules of human hairs with transmission electron micrographs. *Sangyo Ika Daigaku Zasshi* 1990; 12:335-41.
- Nanninga PB, Ghanem GF, Lejeune FJ et al. Evidence for alpha-MSH binding sites on human scalp hair follicles: preliminary results. *Pigment Cell Res* 1991; 4:193-8.