

3-Dimensional Evaluation of the Secondary Alveolar Bone Grafting in Unilateral Cleft Lip Palate Patient Harvested from an Alternative Donor Site: The 4 Years Follow-Up: Case Report

Tek Taraflı Dudak Damak Yarıklı Hastada Alternatif Donör Bölgeden Elde Edilen Sekonder Alveolar Kemik Greftinin 3 Boyutlu Değerlendirilmesi: 4 Yıllık Takip

Sultan ÖLMEZ GÜRLEN,^a
Servet DOĞAN,^b
Eldar AYDINLI,^c
Ufuk BİLKAY^d

^aPrivate,
Departments of
^bOrthodontics,
^cPlastic and Reconstructive Surgery,
Ege University Faculty of Dentistry,
İzmir
^dPrivate, Antalya

Geliş Tarihi/Received: 27.01.2016
Kabul Tarihi/Accepted: 26.05.2016

Yazışma Adresi/Correspondence:
Sultan ÖLMEZ GÜRLEN
Private, İzmir
TÜRKİYE/TURKEY
sultanolmez@gmail.com

ABSTRACT Secondary alveolar bone grafting with autogenous bone is widely used and considered the gold standard in grafting procedures. Different sites including cancellous and/or cortical bone grafts can be used for donation. Iliac crest is one of the most used donor site especially in patients with large defects. In the present case report our aim was to evaluate the long term volumetric change of secondary alveolar bone graft in a patient with unilateral cleft lip and palate after using an alternative donor site.

Key Words: Cleft palate; cleft lip; bone transplantation

ÖZET Sekonder alveolar kemik grefti uygulamalarında sıklıkla otojen kemik kullanılmakta ve greftleme uygulamaları arasında altın standart olarak kabul edilmektedir. Donör bölge olarak kansellöz ve kortikal kemik greftlerinin olduğu farklı bölgeler kullanılabilir. Özellikle geniş defektli hastalarda en çok tercih edilen bölge iliak tepedir. Bu olgu sunumunda, tek taraflı dudak damak yarığına (TTDDY) sahip bir hastada alternatif bir donör bölgeden alınan sekonder alveolar kemik greftinin uzun dönem hacimsel değişiklikleri değerlendirilmiştir.

Anahtar Kelimeler: Yarık damak; yarık dudak; kemik transplantasyonu

Türkiye Klinikleri J Dental Sci Cases 2016;2(2):69-74

Secondary alveolar bone grafting provides a reliable method in the management of patients with alveolar clefts. Successful grafting is important in terms of maxillary arch stabilization by uniting the segments, supporting for soft tissue nasal base and lip, closure of oronasal fistulae, reconstruction of the hypoplastic piriform aperture.¹⁻³ The main advantage of alveolar bone grafting is the ability of moving the teeth by means of orthodontics into previous cleft sites.⁴

There are numerous sources of bone graft including calvarium, ribs, outer site of the parietal bone, mandibular symphysis, tibia and iliac crest. Among these bones the gold standard for secondary grafting is the iliac crest. However, alternative donor sites are required to avoid post-op pain, scar tissue causing esthetical problems and long hospitalization period. Therefore, if the cleft area is not too wide and mandibular 3rd molars are impacted with no chance to erupt, the bone over the impacted teeth can be used as bone graft material in such cases.⁵

doi: 10.5336/dentalcase.2016-50392

Copyright © 2016 by Türkiye Klinikleri

The aim of the present study is the closure of the cleft area by using autogenous bone graft harvested from an alternative donor site without a second operation in an unilateral cleft lip and palate (UCLP) patient and the long-term follow up of the effected site in terms of 3 dimensional (3D) volumetric assessment.

CASE REPORT

9 years and 10 months old boy with unilateral cleft lip and palate was referred to the Ege University, School of Dentistry, and Department of Orthodontics. The signed consent form was obtained from the parent of the patient. Lip closure and palate repair had been performed at the age of 3 months and 11 months, respectively. The patient had a Class III malocclusion with circular crossbite, and an alveolar gap remained with an impacted canine on the right side of the maxillary arch. Rapid palatal expansion followed by face-mask therapy was applied for the correction of transversal and sagittal discrepancies. At 12 years of age after leveling of both arches (Figure 1), secondary bone grafting for the closure of the remained alveolar gap and eruption of the canine was decided.

Radiographs and computed tomography (CT) images revealed impacted mandibular 3rd molars with enough bone material over the teeth for grafting. Under general anesthesia both mandibular 3rd molar teeth were extracted and the bone was harvested from the same site. In the same operation cleft area was exposed and filled with autogenous bone material (Figure 2). The closure of the defect and the eruption of the canine adjacent to the cleft area were shown (Figure 3). Long-term follow-up of the occlusion, canine position and cleft area were shown (Figure 4).

Volumetric measurements of the cleft area before and 4 years after the operation were calculated by the same investigator (S.O.G). A specific software program (Mimics ver. 10.01, Materialize Dental Japan, Funabashi, Japan) was used for the reconstruction of the structures (Figure 5). The measured defect volume before grafting was 304.09

mm³ and 46.28 mm³ 4 years after the surgery. The success rate of the grafting (closure of the defect) was measured as 84.78%.

DISCUSSION

Secondary alveolar bone grafting with autogenous bone is widely used and considered the gold standard in grafting procedures.⁶ Different sites with cancellous and cortical bone grafts can be used for donation. Iliac crest is one of the most used donor site in grafting especially in patients with large defects. However, some investigations have suggested that the iliac crest as donor site produces postoperative pain, hemorrhage, scar, contour deformation, delayed ambulation, risk of cutaneous nerve injury, and desensitization.^{2,7} In the present case since the defect volume was relatively small and only one surgical site was intended, the bone over the impacted mandibular 3rd molars was used.

There is only one case-report presentation having similar grafting procedure. In that study; only radiographic assessment of the bone graft with eye visual was carried out and the success ratio was not measured.⁵ The investigators concluded that although the grafting time was late than the optimal time, the results were satisfactory after the first year with a bone bridge remained functionally and esthetically acceptable.

Two dimensional radiographic assessments after bone grafting are only informative tools used to identify if a bone bridge is formed after grafting or not.⁸ Moreover, 2 dimensional (2D) imaging is too limited in volume analysis due to the superimposition of the adjacent anatomical structures, distortions and enlargements.⁹⁻¹² Therefore the use of CT in the assessment of the alveolar bone graft is recently widespread.^{10,11,13,14} The common point of agreement between these studies is that the amount of bone loss is significantly higher than that shown by 2D imaging. In the present study 3D CT scans were used to assess the defect volume after the grafting. This method seems to be accurate as reported by Jensen et al. (1998) who showed a strong correla-

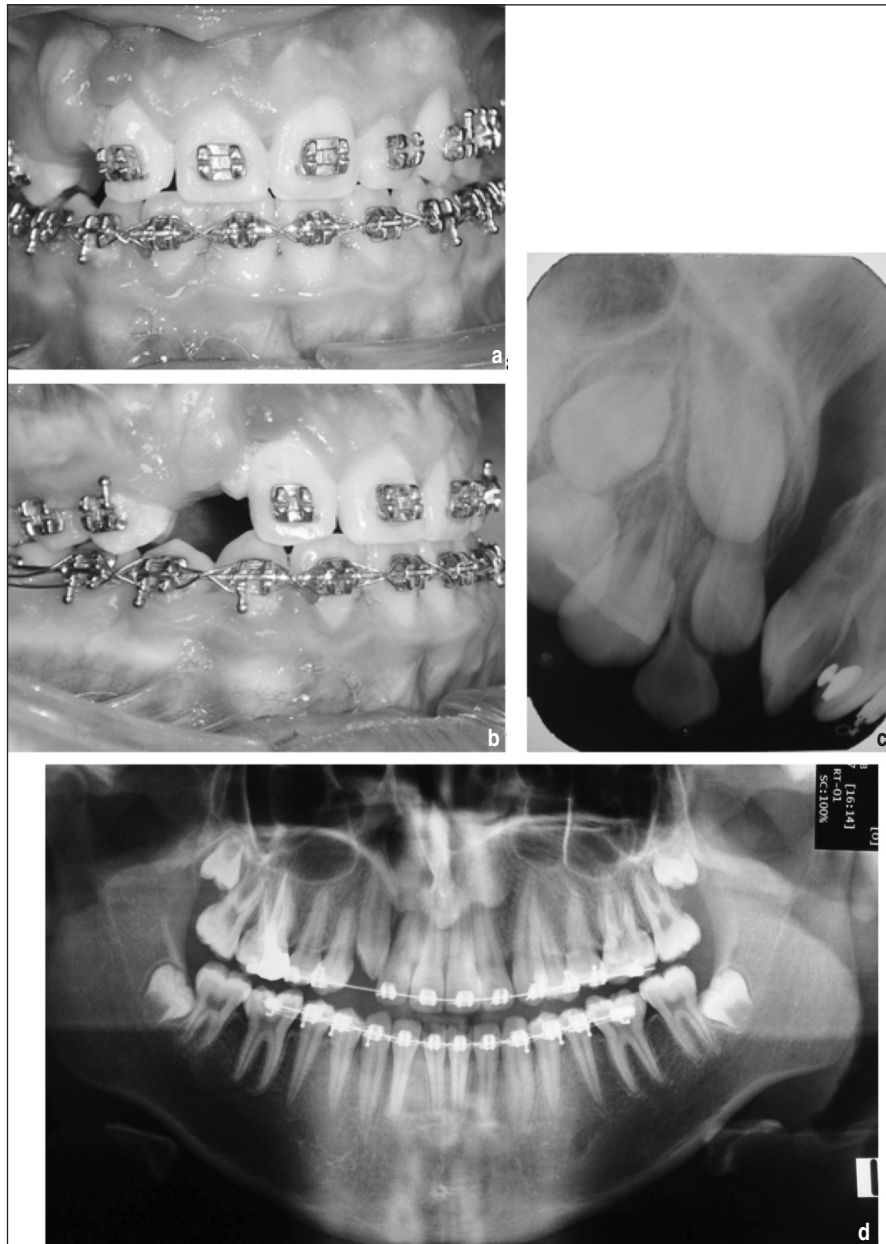

FIGURE 1: Pre-operative records. **a** and **b**. Intraoral photos showing the defect region; **c**. Periapical radiograph showing alveolar cleft region; **d**. Panoramic radiograph showing impacted mandibular 3rd molars and cleft region.

tion between the 3D reconstructions of the pre-defined graft volume based on axial CT scans and calculated graft volume according to the Archimedes principle.¹⁵

In the literature, there are many reports involving long-term success rates of secondary bone grafting based on computed tomography. Rosenstein et al. (1997) investigated the agreement between 3D and 2D assessment and found out that

although 2D method can be used in evaluating bone-graft success for a group of UCLP patient, 3D computed tomography is still a superior, and probably the only assessment method for determining the volumetric bone support for cleft-adjacent teeth in certain clinical situations in which great accuracy were called.¹⁶ The present case represented a high success ratio of %84.78 in the fourth year with 3D assessment. Bone loss was found to

be in bucco-palatine direction. The success rate of grafting in our patient was in accordance with the results of Honma et al. Several studies concerning postoperative bone volume measurements indicated higher bone resorption ratios than the present results especially 2 and 3 years after bone grafting procedure.^{10,11,17}

Closure of the alveolar defect with autogenous bone grafting, enabled the closure of the oronasal fistules, presentation of the arch integrity and eruption of the tooth in the cleft side. Therefore retromolar region where 3rd molars

were impacted served as a good site for alternative donation.

As a result, the surgeon's experience is one of the most important factor in the success of alveolar bone grafting surgery. If the defect is small, the bone over the impacted teeth can be used as an alternative donor site for secondary alveolar bone grafting in order to erupt the impacted canine in cleft side and good closure can be obtained after the grafting procedure. Further researches with more patients are needed to develop alternative donor site procedures.

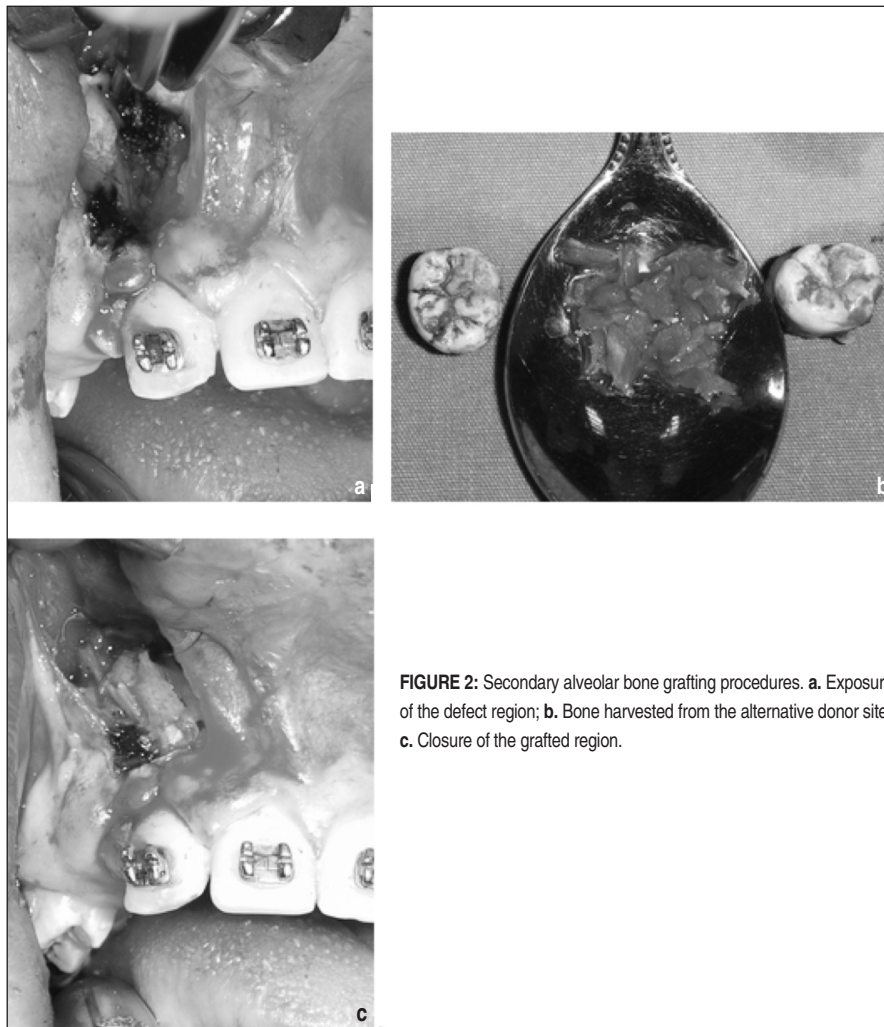


FIGURE 2: Secondary alveolar bone grafting procedures. **a.** Exposure of the defect region; **b.** Bone harvested from the alternative donor site; **c.** Closure of the grafted region.

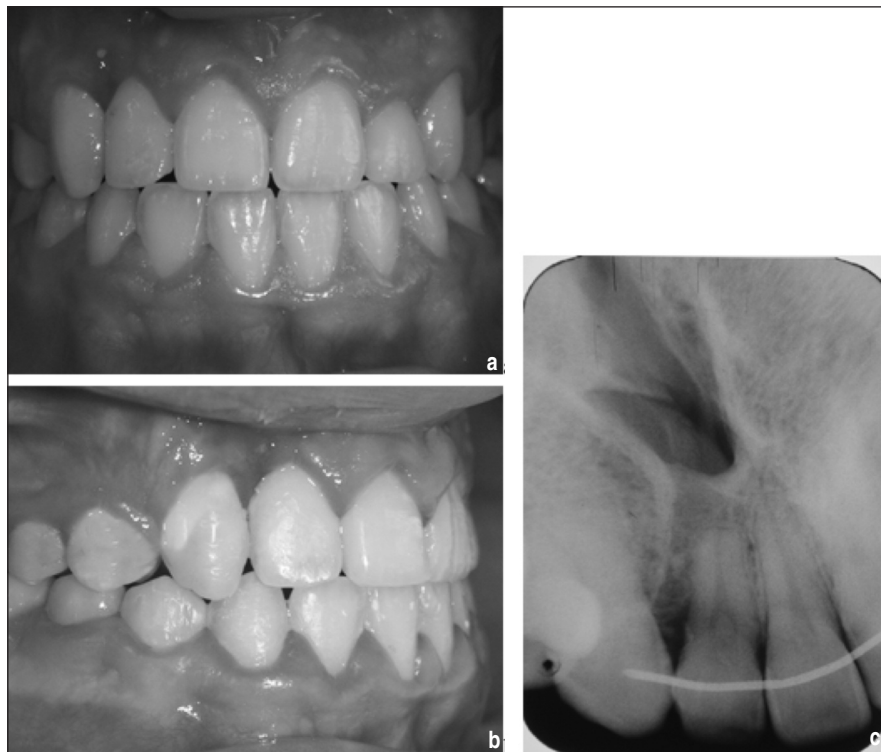

FIGURE 3: Post-treatment records. **a** and **b**. Intraoral photos showing the defect region; **c**. Periapical radiographs showing good bone material on the cleft side.

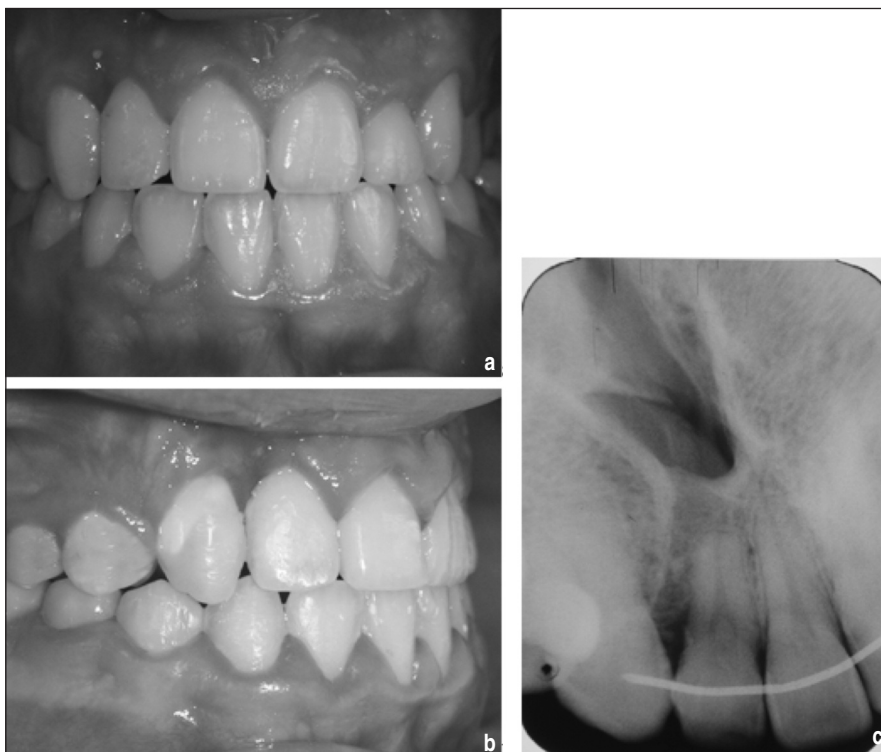

FIGURE 4: The four years follow-up records. **a** and **b**. Intraoral photos showing the defect region; **c**. Periapical radiographs showing improved bone material on the cleft side.

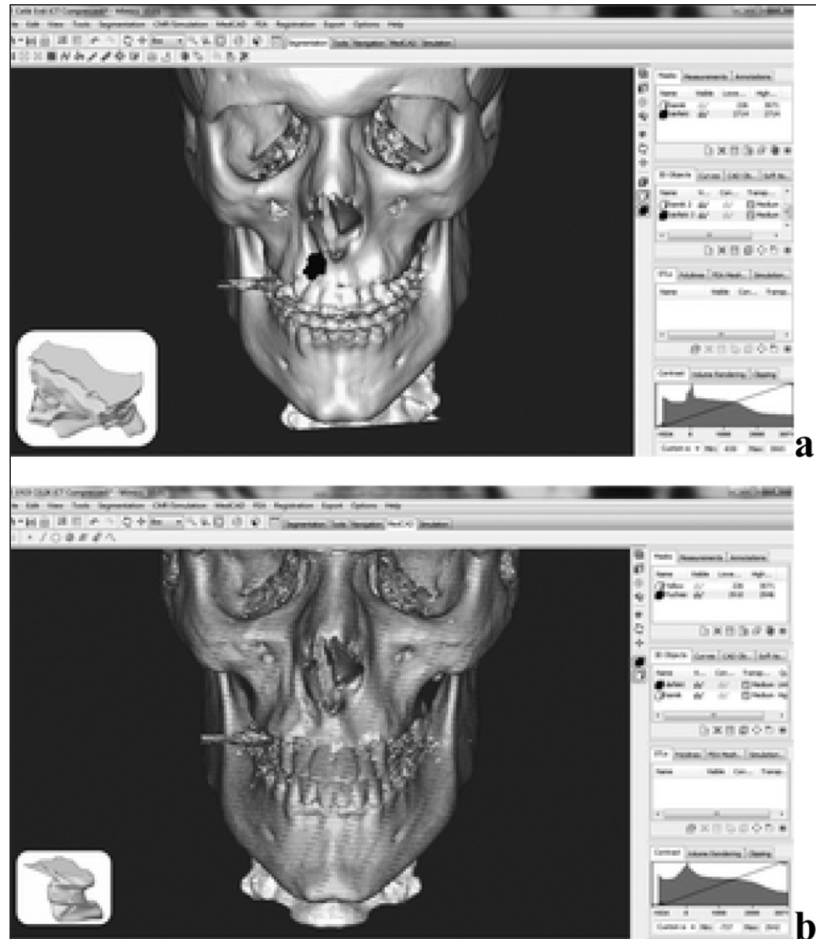


FIGURE 5: Volume calculation of the regions of interest. a. Preoperative cleft defect; b. 4 years postoperative residual cleft defect.

REFERENCES

1. Eppley BL, Sadove AM. Management of alveolar cleft bone grafting--state of art. *Cleft Palate Craniofac J* 2000;37(3):229-33.
2. Bajaj AK, Wongworawat AA, Punjabi A. Management of alveolar clefts. *J Craniofac Surg* 2003; 14(6):840-6.
3. McIntyre GT, Devlin MF. Secondary alveolar bone grafting (CLEFTSiS) 2000-2004. *Cleft Palate Craniofac J* 2010;47(1):66-72.
4. Jia YL, Fu MK, Ma L. Long-term outcome of secondary alveolar bone grafting in patients with various types of cleft. *Br J Oral Maxillofac Surg* 2006;44(4):308-12.
5. So LL, Lui WW. Alternative donor site for alveolar bone grafting in adults with cleft lip and palate. *Angle Orthod* 1996;66(1):9-16.
6. De Riu G, Meloni SM, Raho MT, Gobbi R, Tullio A. Delayed iliac abscess as an unusual complication of an iliac bone graft in an orthognathic case. *Int J Oral Maxillofac Surg* 2008;37(12):1156-8.
7. Rawashdeh MA, Telfah H. Secondary alveolar bone grafting: the dilemma of donor site selection and morbidity. *Br J Oral Maxillofac Surg* 2008; 46(8):665-70.
8. Dieleman FJ, Tump P, Baart JA, Tuinzing DB, Bezemer PD. A computed tomographic evaluation of change in bone volume after secondary bone grafting over the first postoperative year. *Plast Reconstr Surg* 2004;114(3):738-42.
9. Waitzman AA, Posnick JC, Armstrong DC, Pron GE. Craniofacial skeletal measurements based on computed tomography: Part I. Accuracy and reproducibility. *Cleft Palate Craniofac J* 1992;29(2): 112-7.
10. Feichtinger M, Zemann W, Mossböck R, Kärcher H. Three-dimensional evaluation of secondary alveolar bone grafting using a 3D- navigation system based on computed tomography: a two-year follow-up. *Br J Oral Maxillofac Surg* 2008;46(4): 278-82.
11. Feichtinger M, Mossböck R, Kärcher H. Assessment of bone resorption after secondary alveolar bone grafting using three-dimensional computed tomography: a three-year study. *Cleft Palate Craniofac J* 2007;44(2):142-8.
12. Kim KR, Kim S, Baek SH. Change in grafted secondary alveolar bone in patients with UCLP and UCLA. A three-dimensional computed tomography study. *Angle Orthod* 2008;78(4):631-40.
13. Van der Meij AJ, Baart JA, Prah-Andersen B, Valk J, Kostense PJ, Tuinzing DB. Bone volume after secondary alveolar bone grafting in unilateral and bilateral clefts determined by computed tomography scans. *Oral Surg Oral Med Oral Pathol Oral Radio Endod* 2001; 92(2):136-41.
14. Hamada Y, Kondoh T, Noguchi K, Iino M, Isono H, Ishii H, et al. Application of limited cone beam computed tomography to clinical assessment of alveolar bone grafting: a preliminary report. *Cleft Palate Craniofac J* 2005;42(2):128-37.
15. Jensen J, Kragsskov J, Wenzel A, Sindet-Pedersen S. Volumetry of bone grafts by three-dimensional computed tomographic reconstruction: an animal study in the minipig. *Dentomaxillofac Radiol* 1998;27(1): 41-4.
16. Rosenstein SW, Long RE Jr, Dado DV, Vinson B, Alder ME. Comparison of 2-D calculations from periapical and occlusal radiographs versus 3-D calculations from CAT scans in determining bone support for cleft-adjacent teeth following early alveolar bone grafts. *Cleft Palate Craniofac J* 1997;34(3):199-205.
17. Honma K, Kobayashi T, Nakajima T, Hayasi T. Computed tomographic evaluation of bone formation after secondary bone grafting of alveolar clefts. *J Oral Maxillofac Surg* 1999; 57(10):1209-13.