

Bilateral Fusion of Maxillary First Premolar and Impacted Supernumerary Teeth, Combined with Dens Evaginatus

Dens Evaginatus ile Maksiller Birinci Premolar ve Gömülü Süpernümerer Dişlerin İki Taraflı Füzyonu

^{ID} Kadriye Ayça DERE^a, ^{ID} Melih ÖZDEDE^b, ^{ID} Çağatay ŞİBE^a

^aDepartment of Oral and Maxillofacial Surgery, Pamukkale University Faculty of Dentistry, Denizli, TURKEY

^bDepartment of Oral and Maxillofacial Radiology, Pamukkale University, Faculty of Dentistry, Denizli, TURKEY

ABSTRACT Fusion is a developmental dental anomaly in which a single large tooth is formed from the germs of two normally adjacent teeth. The incidence of fused teeth is 0.1-0.3% in the permanent and 0.5-2.5% in the primary dentition, and fusion is usually unilateral. Another dental developmental anomaly, dens evaginatus, is defined as an accessory tubercle, consisting of enamel, dentine, and pulp. A 17-year-old female patient was referred to our clinic with a complaint of pain and swelling in the maxilla bilateral premolar regions. After the evaluation of clinical, two, and three-dimensional radiological findings, bilateral complete and incomplete fusion of the maxillary first premolar and impacted supernumerary teeth was diagnosed, which is a rare condition. Also, the left impacted supernumerary tooth had another developmental anomaly, dens evaginatus, that makes the case more interesting. Treatment options were recommended to the patient, who requested the extraction of the teeth, and the relevant teeth were extracted. Careful clinical and radiographic examinations should be performed for the diagnosis and treatment of fusion that may cause functional and esthetic problems.

Keywords: Cone-beam computed tomography; permanent dentition; supernumerary tooth; tooth abnormalities

ÖZET Füzyon, normal olarak bitişik 2 dişin germelerinden tek 1 büyük dişin oluştuğu gelişimsel bir diş anomalisidir. Füzyonlu dişlerin insidansı, daimi dişlerde %0,1-0,3; süt dişlerinde ise %0,5-2,5 aralığında olup, füzyon genellikle tek taraflıdır. Başka bir diş gelişimsel anomalisi olan dens evaginatus, mine, dentin ve pulpadan oluşan bir aksesuar tüberkül olarak tanımlanır. On yedi yaşında kadın hasta maksilla bilateral premolar bölgelerde ağrı ve şişlik şikâyeti ile kliniğimize başvurdu. Klinik, 2 ve 3 boyutlu radyolojik bulguların değerlendirilmesi sonucunda, nadir olarak görülen maksiller birinci premolar ve gömülü süpernümerer dişlerin bilateral füzyonu tespit edildi. Ayrıca soldaki süpernümerer dişte, başka bir gelişimsel anomali olan dens evaginatus mevcuttu. Dişlerin çekimini talep eden hastaya tedavi seçenekleri önerildi ve ilgili dişlerin çekimi yapıldı. Fonksiyonel ve estetik sorunlara neden olabilecek füzyonun tanı ve tedavisi için dikkatli klinik ve radyografik incelemeler yapılmalıdır.

Anahtar Kelimeler: Konik ışınlı bilgisayarlı tomografi; kalıcı diş çıkartma; süpernümere diş; diş anomalileri

The dental anomalies may occur due to genetic disorders or harmful factors affecting the tooth tissue and shapes. Dental anomalies also may occur idiosyncratically. These anomalies are classified according to their clinical features, such as size, condition, number, form, and tissue anomalies.¹

The terms “double teeth”, “joined teeth”, and “twinning” are usually used to describe gemination

and fusion. Gemination and fusion are form anomalies that dispute clinicians in terms of differential diagnosis due to their similar features. Embryonically, it has been suggested that fusion and gemination occur as a result of changes in the tooth germs separated from the dental lamina during tooth development.² Gemination is defined as an attempt of a single tooth germ to divide, with the resultant formation of

Correspondence: Melih ÖZDEDE

Department of Oral and Maxillofacial Radiology, Pamukkale University Faculty of Dentistry, Denizli, TURKEY/TÜRKİYE

E-mail: melihozdede@gmail.com



Peer review under responsibility of Türkiye Klinikleri Journal of Dental Sciences.

Received: 27 Jul 2020

Received in revised form: 26 Nov 2020

Accepted: 30 Nov 2020

Available online: 11 Feb 2021

2146-8966 / Copyright © 2021 by Türkiye Klinikleri. This is an open access article under the CC BY-NC-ND license (<http://creativecommons.org/licenses/by-nc-nd/4.0/>).

a tooth with a bifid crown and root.³ Fusion is defined as the merger of two developing teeth germs at the dentin level, forming a single large tooth structure. Fused teeth may have two separate root canals or single large root canal. Fusion is thought to occur because of external pressures and forces.^{2,4}

The prevalence of fused teeth was estimated as 0.1-0.3% in permanent dentition, and 0.5-2.5% in primary dentition.³⁻⁶ Fusion usually occurs unilaterally. This anomaly is usually observed in the anterior region, mostly between the mandibular lateral and canine teeth in primary dentition.^{7,8} The presence of fused teeth in occlusion may lead to aesthetic, orthodontic, and chewing problems in the patients, especially when supernumerary teeth are involved. Also, periodontal problems, caries, and pulpal pathologies may occur in fused teeth.^{4,9}

Another dental developmental anomaly, dens evaginatus, is defined as an accessory tubercle, consisting of enamel, dentine, and pulp tissues. Dens evaginatus may be located on the oral surfaces of the anterior teeth, or the central groove or tubercle of premolar and molar teeth.¹⁰ This dental anomaly is mentioned to have a genetic origin that occurs during the bell stage of dental development. It is suggested that a part of the inner enamel epithelium is abnormally proliferated, and the enamel organ is folded. This leads to the formation of a tubercle and dens evaginatus occurs.¹⁰

This paper reports the diagnosis and the treatment of a rare case of bilateral complete and incomplete fusion of maxillary first premolars with supernumerary teeth, combined with dens evaginatus.

CASE REPORT

A 17-year-old female patient was referred to the department of oral diagnosis and dentomaxillofacial radiology, with a chief complaint of pain and swelling in the bilateral maxillary premolar regions. Her medical history was not relevant, and no maxillofacial trauma history was reported. She had no family history of dental anomalies. Informed consent was taken before the examination. No abnormalities were detected during the extraoral examination. Intraoral examination revealed that the teeth were located in appropriate positions in both dental arches. Only the

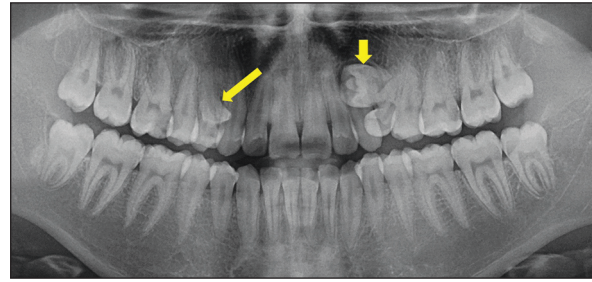


FIGURE 1: The panoramic image showed impacted supernumerary teeth in maxilla right (long arrow) and left (short arrow) first premolars.

left first premolar tooth was positioned palatally. The swelling was observed in the palatal mucosa of the bilateral maxillary second premolar teeth on inspection and palpation.

Radiographically, the panoramic radiographic image showed impacted supernumerary teeth in maxilla bilateral premolar regions (Figure 1). The supernumerary tooth on the left side was horizontally impacted and had an oval radiopacity on the crown. Cone-beam computed tomography (CBCT) was used to obtain a detailed three-dimensional examination. In the sections of the right maxilla premolar region, a supernumerary impacted tooth fused with the first premolar was detected (Figure 2). The crowns, roots, and pulps of two teeth were merged. On the left side, the first premolar tooth was fused with another supernumerary tooth which had dens evaginatus (Figure 3). The roots of two structures were merged. Based on these findings, the bilateral fusion of the first premolar and supernumerary teeth was diagnosed. The left supernumerary tooth had also dens evaginatus, occlusal tubercle type.

After clinical and radiological evaluations, treatment steps were explained to the patient as:

1. Root-canal treatment of the maxillary first premolars, combined with hemisection,
2. Orthodontic treatment, after root-canal treatments of the premolar teeth and hemisection,
3. Extraction of the supernumerary teeth with first premolar teeth.

The patient did not accept root-canal treatment or orthodontics options, she requested to eliminate the problem of chewing. As a result, the extraction of the fused teeth was planned.

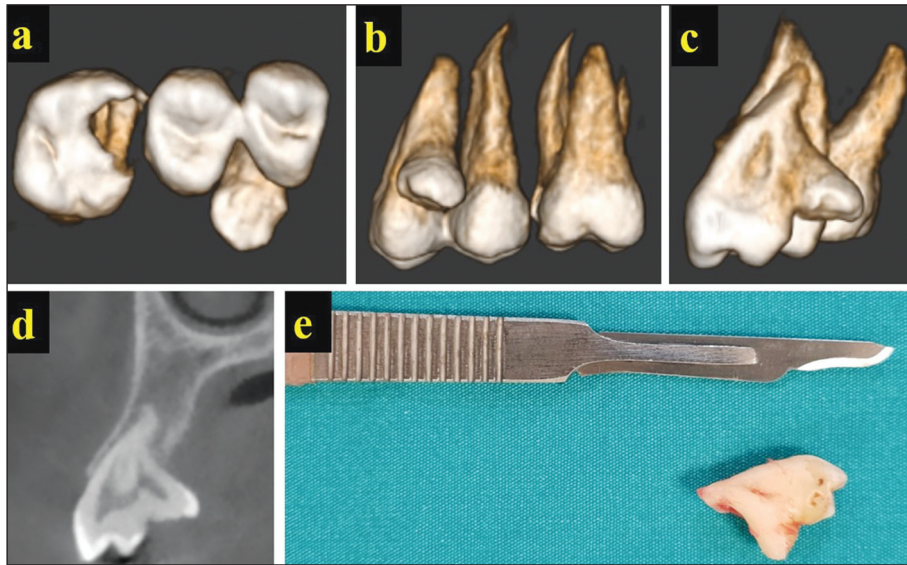

FIGURE 2: The fusion between the maxillary right first premolar and the supernumerary tooth is shown on three-dimensional reconstruction images [(a) inferior view, (b) palatal view, (c) mesial view], cross-sectional slice (d) of cone-beam computed tomography, and post-surgery photograph (e).

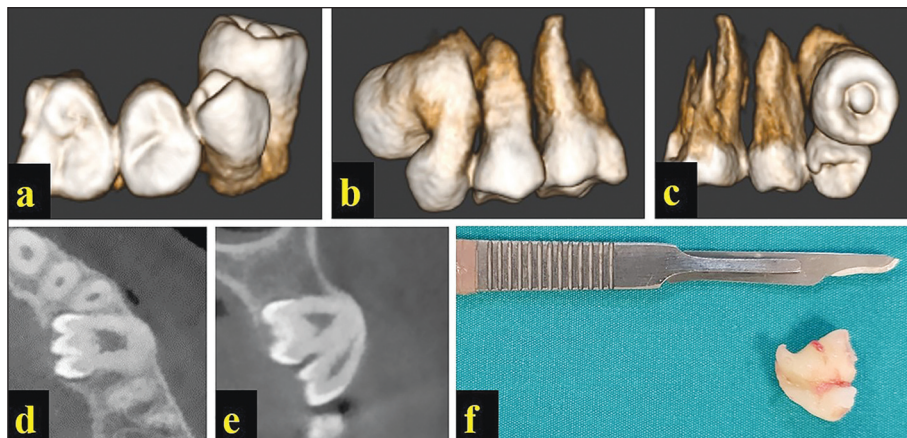


FIGURE 3: The fusion of the maxillary left first premolar and the supernumerary tooth with dense evaginatus, shown on three-dimensional reconstruction images [(a) inferior view, (b) buccal view, (c) palatal view] axial slice (d), cross-sectional slice (e) of cone-beam computed tomography, and post-surgery photograph (f).

The patient was informed about the surgical procedure. The surgical removal of first premolars and supernumerary teeth was performed in the department of oral and maxillofacial surgery. Surgical treatment was performed under local anesthesia using an articaine solution containing 2% adrenaline. Palatal incisions were made with a no. 15 scalpel and full-thickness mucoperiosteal flaps were raised bilaterally. All teeth were moved with the Bein elevator and removed from the socket with the help of a dental extraction forceps (Figure 2, and Figure 3). After the bleeding had been controlled, the region was closed with 3.0 silk sutures.

DISCUSSION

Gemination and fusion are developmental anomalies clinically characterized by a wide tooth. The differential diagnosis should be made with detailed clinical and radiographic examinations. Fusion occurs when two separate tooth germ merge together, while gemination occurs as a result of the splitting of a single tooth germ.² Due to the detection of merged teeth in two separate forms, we established the diagnosis as bilateral impacted supernumerary teeth fused to the first premolar teeth.

Complete or incomplete fusion may occur, depending on the stage of development of the teeth. When fusion occurs before the calcification stage, the tooth contains wide enamel, dentin, root, and pulp, and this results a complete fusion. If fusion occurs after calcification, fusion is seen at the root, defined as an incomplete fusion.^{2,4} Both complete (right side) and incomplete (left side) fusion were detected in our patient.

Rarely, fusion can develop between the permanent and supernumerary teeth.¹¹ In our case, the supernumerary teeth were fused with the first premolar teeth. In addition, fused teeth usually erupt into the oral cavity together. In the present case, the merged teeth did not erupt together, because of the different angulation and attachment levels. No fused tooth was found in this position in the literature, suggesting that our case is quite rare.

Fusion can usually develop unilaterally, bilateral fusion is rarely seen.^{3,5} The prevalence of bilateral fusion was reported as 0.03-0.05% in permanent dentition.²⁻⁴ Chalakkal and Thomas reported that only 14 cases of bilateral fusion of mandibular primary lateral incisors and canines had been published in the literature.⁵ Only a few cases of fusion of molar and premolar teeth have been reported.^{7,8} The prevalence is higher in the anterior region in both jaws.^{7,8} The fusion found in bilateral permanent dentition fusion affecting the premolar teeth makes our case remarkable. This case is more interesting due to the dens evaginatus found in the left supernumerary tooth.

Fused teeth are usually asymptomatic. However, fusion can cause an increased risk of malocclusions, caries, and periodontal problems depending on the fused tooth's structure and crowding of the dental arch.² A multidisciplinary dental treatment plan is required to solve these problems. The treatment options are separation and extraction of the supernumerary tooth with or without root-canal treatment (hemisection), restoration or prosthetic treatment of the tooth, orthodontic treatment for malocclusion, or extraction of the fused tooth.^{2,4,5,9} The patient requested extraction of the teeth, despite the offer of other treatment options. The treatment was completed in this direction, which was the most marginal treatment option.

In the diagnosis of dental anomalies, conventional two-dimensional imaging might sometimes be insufficient. In these cases, CBCT imaging may help for identifying the accurate location and shape of the dental anomalies.¹² This radiographic technique provides a three-dimensional evaluation of the structures. CBCT is easier, cheaper, and requires a lower radiation dose compared to medical computed tomography. However, the decision to use CBCT should be made carefully, as it requires more radiation doses than conventional dental imaging.¹² Two-dimensional imaging was insufficient for determining the exact location/shape of the supernumerary teeth in our case. For detailed examination, CBCT was obtained, and the diagnosis was confirmed.

In conclusion, careful clinical and radiographic examinations should be performed for the diagnosis and treatment of developmental dental anomalies that may cause functional and esthetic problems. Multidisciplinary treatment options should be evaluated, and the function and aesthetics of the dentition should be restored.

Source of Finance

During this study, no financial or spiritual support was received neither from any pharmaceutical company that has a direct connection with the research subject, nor from a company that provides or produces medical instruments and materials which may negatively affect the evaluation process of this study.

Conflict of Interest

No conflicts of interest between the authors and / or family members of the scientific and medical committee members or members of the potential conflicts of interest, counseling, expertise, working conditions, share holding and similar situations in any firm.

Authorship Contributions

Idea/Concept: Kadriye Ayça Dere, Melih Özdede; **Design:** Melih Özdede, Kadriye Ayça Dere; **Control/Supervision:** Melih Özdede, Kadriye Ayça Dere; **Data Collection and/or Processing:** Melih Özdede, Kadriye Ayça Dere, Çağatay Şibe; **Analysis and/or Interpretation:** Melih Özdede, Çağatay Şibe, Kadriye Ayça Dere; **Literature Review:** Melih Özdede, Kadriye Ayça Dere; **Writing the Article:** Kadriye Ayça Dere, Melih Özdede; **Critical Review:** Melih Özdede, Kadriye Ayça Dere; **References and Findings:** Melih Özdede, Kadriye Ayça Dere; **Materials:** Melih Özdede, Kadriye Ayça Dere.

REFERENCES

1. Tarasingh P, Balaji K. Gemination in primary teeth - a report of two clinical cases. *Ann Essences Dent.* 2010;2(2):48-51. [[Crossref](#)]
2. Tomizawa M, Shimizu A, Hayashi S, Noda T. Bilateral maxillary fused primary incisors accompanied by succedaneous supernumerary teeth: report of a case. *Int J Paediatr Dent.* 2002;12(3):223-7. [[Crossref](#)] [[PubMed](#)]
3. Akay G, Ispir NG, Haroglu D, Gungor K, Alkurt MT. Frequency and distribution of fusion and gemination in permanent dentition : Clinical and radiological study. *Türkiye Klinikleri J Dental Sci.* 2020;26(3):348-53. [[Crossref](#)]
4. Saxena A, Pandey RK, Kamboj M. Bilateral fusion of permanent mandibular incisors: a case report. *J Indian Soc Pedod Prev Dent.* 2008;26 Suppl 1:S32-3. [[PubMed](#)]
5. Chalakkal P, Thomas AM. Bilateral fusion of mandibular primary teeth. *J Indian Soc Pedod Prev Dent.* 2009;27(2):108-10. [[Crossref](#)] [[PubMed](#)]
6. Guimarães Cabral LA, Firoozmand LM, Dias Almeida J. Double teeth in primary dentition: report of two clinical cases. *Med Oral Patol Oral Cir Bucal.* 2008;13(1):E77-80. [[PubMed](#)]
7. Caceda JH, Creath CJ, Thomas JP, Thornton JB. Unilateral fusion of primary molars with the presence of a succedaneous supernumerary tooth: case report. *Pediatr Dent.* 1994;16(1):53-5. [[PubMed](#)]
8. Beltes P, Huang G. Endodontic treatment of an unusual mandibular second molar. *Endod Dent Traumatol.* 1997;13(2):96-8. [[Crossref](#)] [[PubMed](#)]
9. Türkaslan S, Gökçe HS, Dalkız M. Esthetic rehabilitation of bilateral geminated teeth: a case report. *Eur J Dent.* 2007;1(3):188-91. [[Crossref](#)] [[PubMed](#)] [[PMC](#)]
10. Chen JW, Huang GT, Bakland LK. Dens evaginatus: Current treatment options. *J Am Dent Assoc.* 2020;151(5):358-67. [[Crossref](#)] [[PubMed](#)]
11. Chipashvili N, Vadachkoria D, Beshkenadze E. Gemination or fusion? - challenge for dental practitioners (case study). *Georgian Med News.* 2011;(194):28-33. [[PubMed](#)]
12. Akay G, Özdede M, Güngör K. An evaluation of mesiodentes: a retrospective study with cone-beam computed tomography. *Selcuk Dent J.* 2018;5:203-11. [[Link](#)]