

Circulating Serum Zonulin Levels Before and After Probiotic Enema Treatment in Dogs with Atopic Dermatitis: Randomized Clinical Study

Atopik Dermatitli Köpeklerde Probiyotik Enema Sağaltımı Öncesi ve Sonrası Dolaşım Serum Zonulin Seviyesi: Randomize Klinik Çalışma

Kerem URAL^a, Hasan ERDOĞAN^a, Songül ERDOĞAN^a, İlker CAMKERTEN^b, Nurcan ŞAHİN^a

^aDepartment of Internal Medicine, Aydın Adnan Menderes University Faculty of Veterinary, Aydın, TURKEY

^bDepartment of Internal Medicine, Aksaray University Faculty of Veterinary, Aksaray, TURKEY

ABSTRACT Objective: In the present study, we investigated the benefits of rectal enema probiotic combination in dogs with atopic dermatitis and detected circulating serum zonulin levels in these. **Material and Methods:** An open-label, self-controlled case series involved 6 privately owned dogs with atopic dermatitis. Diagnosis involved corneometric analytes, Canine Atopic Dermatitis Extent and Severity Index version 4 (CADESI-04) scores, visual analogue scale (VAS) pruritus scores and *in vitro* allergen specific tests. Faecal samples were forwarded to dual indexing one-step polymerase chain reaction and 16S rRNA targeted metagenomics in an attempt to determine gut microbiota alterations before and after rectal enema probiotic once daily for 10 days. **Results:** Following rectal enema probiotic treatment, as the in the vast majority *Prevotella* genus was significantly detected in association with clinical cure and recovery. Median CADESI-04 ($p=0.028$) and VAS pruritus scores ($p=0.028$) along with circulating zonulin ($p=0.026$) levels were decreased in atopic dermatitis cases on day 10 in contrast to 0th day values. Corneometric analysis involving median epidermal pH ($p=0.027$) and hydration values ($p=0.028$) revealed a significant improvement. **Conclusion:** This positive impact on skin inflammation and diminished pruritus after application of rectal enema probiotic in this model of atopic dermatitis in dogs probably presented withdrawal of chronic barrier disruption and healed tight junctions. The selected *Lactobacillus* probiotic strains used as an enema potentially regulate on skin health by the manipulation of the gut microbiome resulted with intestinal balance.

Keywords: Canine atopy; intestinal microbiome; probiotics; rectal enema; zonulin

ÖZET Amaç: Bu çalışmada, atopik dermatitisli köpeklerde probiyotik kombinasyonlarının rektal uygulama yararlarının araştırılması ve bunlarda serum zonulin seviyelerinin belirlenmesi amaçlandı. **Gereç ve Yöntemler:** Açık-uçlu, öz deneyimli olgu serisi atopik dermatitisli 6 sahipli köpekten oluştu. Tanıda korneometrik analiz, Köpeklerde Atopik Dermatit Yaygınlık ve Şiddet İndeksi-04 [Canine Atopic Dermatitis Extent and Severity Index version 4 (CADESI-04)] skoru, vizüel analog skala (VAS) kaşıntı skoru ve *in vitro* alerjen spesifik test kullanıldı. Dışkı örnekleri, 10 gün boyunca günde 1 kez rektal enema probiyotik öncesi ve sonrasında bağırsak mikrobiyota değişikliklerini belirlemek amacıyla metagenomikleri hedefleyen ikili indeksemle tek adımlı polimeraz zincir reaksiyonu ve 16S rRNA analizine gönderildi. **Bulgular:** Rektal enema probiyotik sağaltımını takiben klinik iyileşme ve tedaviyle ilişkili büyük çoğunluğu *Prevotella* cinsi olacak şekilde önemli bulundu. Ortalama CADESI-04 ($p=0,028$) ve VAS kaşıntı skoru ($p=0,028$) ile zonulin ($p=0,026$) seviyesi 0. gün değerlerine kıyasla 10. günde azaldı. Korneometrik analizlerden epidermal pH ($p=0,027$) ve hidrasyon değeri ($p=0,028$) belirgin iyileşme gösterdi. **Sonuç:** Köpeklerde, bu atopik dermatitis modelinde rektal enema probiyotik uygulanmasından sonra deri yangısı ve azalan kaşıntı üzerindeki olumlu etki, muhtemelen kronik bariyer bozulmasının gerilemesi ve sıkı bağlantıların iyileşmesini temsil etmektedir. Enema kullanımında tercih edilen *Lactobacillus* probiyotik suşları, intestinal denge ile sonuçlanan bağırsak mikrobiyotasının manipüle edilmesi ile deri sağlığını potansiyel olarak düzenledi.

Anahtar Kelimeler: Kanin atopi; intestinal mikrobiyom; probiyotikler; rektal enema; zonulin

Given the connection between the gut with reference to in terms of intestinal microbiome and skin health, denoting the “gut-skin axis”, has been

well recognized.¹ The gut microbiome had an pivotal of regulation and formation of the skin disease. Gut and skin microbiome have been altered together in

Correspondence: Kerem URAL

Department of Internal Medicine, Aydın Adnan Menderes University Faculty of Veterinary, Aydın, TURKEY/TÜRKİYE

E-mail: uralkerem@gmail.com



Peer review under responsibility of Türkiye Klinikleri Journal of Veterinary Sciences.

Received: 20 Aug 2021

Received in revised form: 08 Dec 2021

Accepted: 13 Dec 2021

Available online: 14 Dec 2021

2146-8850 / Copyright © 2021 by Türkiye Klinikleri. This is an open access article under the CC BY-NC-ND license (<http://creativecommons.org/licenses/by-nc-nd/4.0/>).

skin diseases. The microbiome has maintained homeostasis between tissues and organs, and also it regulates the immune system. Hence, it is important to follow interplaying between skin and gut microbiome for the enhanced understanding of dysbiosis and to shed light on novel therapeutic approaches.²

Increasing intestinal permeability as resulted by dysbiosis can be followed with several biomarkers, one of them a protein called zonulin, that reversibly activates intestinal permeability through reducing tight junctions (tJs). So increasing intestinal permeability induces inflammation and transition of immune cells to circulation that effect most of system including skin.³ Thus targeting restoration of the intestinal dysbiosis, not only prevents the inflammation but also protects from the onset of skin disorders.

Aroused interest presented that beneficial bacteria, namely probiotics might mitigate dermal inflammation, with a great potential of preventing and treating several dermatological disorders. In a prior study, supplementation of *Lactobacillus plantarum* strain relived atopic dermatitis (aD) and eosinophil counts were diminished in humans, whereas *Lactobacillus paracasei* strain presented decreased skin sensitivity and transepidermal water loss.^{4,5}

In the present study, the researchers preferred probiotic enema involving two *Lactobacillus* species for treatment of aD, thereafter analyzed circulating zonulin levels in an attempt to determine gut microbiota alterations before and after rectal enema probiotic (rePt) once daily for 10 days.

MATERIAL AND METHODS

RESEARCH PERIOD/INCLUSION CRITERIA

This open-label, non-controlled study (self controlled case series) was performed with regard to written owner consent. Two subsequent re-evaluations at day 0 and at the end of day 10, after therapeutical intervention was denoted as the start and endpoints of the study.

The present study was conducted at the Veterinary Faculty of Aydın Adnan Menderes University. Six privately owned dogs with the age of

2 to 5 years old and both gender were involved in the study. Dogs with waxing and wanning pruritus were primarily detected with a presumed canine aD. Data involved a detailed history, records of clinical signs (erythema, lichenification and alopecia/excoriation) which were also scored in association with Canine Atopic Dermatitis Extent and Severity Index version 4 (CADESI-04) (Table 1) and visual analog scales (VAS) for pruritus, allergen-specific immunoglobulin E (IgE) detection (Polycheck Canine Allergy Test, GmbH, Germany; distributor RDA Group, İstanbul), corneometric analysis (epidermal pH and hydration by use of Callegari Soft Plus device, Italy) and dermatoscopic examination.⁶⁻⁸ All 6 cases were on a food trial involving hydrolyzed proteins. Neither treatment application nor previous drug administration was evident, as an inclusion criteria. Dogs were excluded if other disorders were detected. Routine blood work and endocrine panels were available on days 0 and 10 for all dogs enrolled.

MICROBIOME TESTING

This was available in 4 out 6 dogs involved, due to restricted financial support. Briefly, steps were as follows 1) Stool sample collection at the university practice by use of cotton swab directly from rectum lumen, and storage at 4-8°C prior to rePt, into 70% ethanol tubes provided by the company (Animal Biome, Oakland, California, USA). 2) Fecal material isolation, extraction of DNA and concentration measurement, 3) 16S rRNA gene (505F/816 R) generation using one step polymerase chain reaction, 4) Alpha and beta diversity analysis involving 100% Operational Taxonomic Units (OTUs) classified against SILVA reference database.⁹⁻¹² All of the procedures were completed at Animal Biome Laboratory at Oakland, USA by experted and specialized researchers.

PROBIOTIC ENEMA TREATMENT METHODOLOGY

rePt treatment involved *L. paracasei* 8700:2 and *L. plantarum* HEAL9 strains (Probest defense tablet, Abdi İbrahim, Turkey). Briefly, each tablet was poured and then dissolved in 20 mL sterile water, which was then rectally administered as an enema model. Treatment trial involved 10 days, and each owner was advised to be at the clinic everyday at the same time.

Methodology of and proposed mechanism of efficacy was shown in Figure 1 and Figure 2 below.

SERUM ZONULIN LEVELS AS DETECTED BY ELISA

Serum zonulin has been determined according to Dog Zonulin (HP) ELISA Kit supplied by Abbexa Ltd. United Kingdom.

STATISTICAL ANALYSIS

Descriptive statistics were given as median (minimum-maximum) and was shown in Table 2. All data were not normally distributed before and after logarithmic transformation process. Wilcoxon test was preferred for comparison of available data prior to-

TABLE 1: Proposed benchmarks for atopic dermatitis severity by use of CADESI-04 scores as determined by Olivry et al.⁶

Proposed benchmarks for atopic dermatitis severity by use of CADESI-04 scores*	Severity of dermatitis
<10 points	Normal
scores of 10-34	Mild
35-59 indicated	Moderate
60-180	Severe

The cases involved at this figure complex are to those of atopic dermatitis cases in the present study. *CADESI-04 score: Canine Atopic Dermatitis Extent and Severity Index version 4.

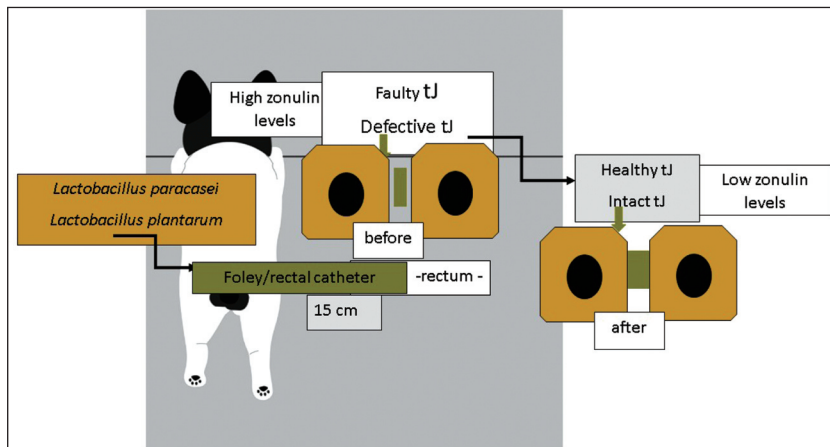


FIGURE 1: Methodology (used in this study) and probable mechanism of action for probiotic enema. Word drawings/cartoon depicts enterocytes with coloring (Enterocytes: ■ tight junctions ■). High zonulin levels detected prior to treatment might probably be related to faulty/defective tJ, which was reversed following rePt resulted in lowered zonulin levels and healthy tJ. tJ: Tight junction; rePt: Rectal enema probiotic.

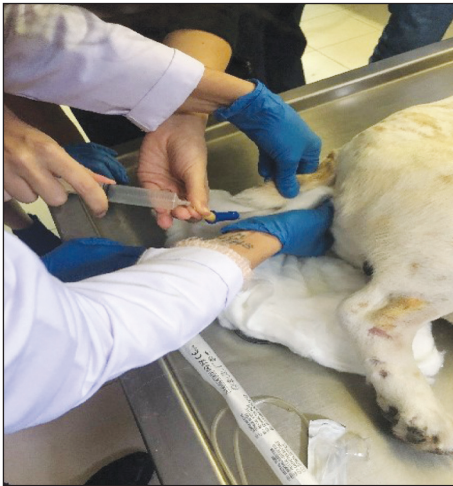

FIGURE 2: Prior to rePt, rectal catheter should be properly and truly placed at least 15 cm aside from rectum. rePt: Rectal enema probiotic.

and thereafter rePt. All analysis were performed on SPSS 20.0 (IBM, USA) and $p < 0.05$ was set as statistically significant.

ETHICS COMMITTEE APPROVAL

This study was approved by Aydın Adnan Menderes University Local Ethical Committee on Animal Experiments with number 64583101/2020/045 (9/7/2020). All animals enrolled in this study were humanely treated in accordance with the Guide for the Care and Use of Laboratory Animals (www.nap.edu/catalog/5140.html).

RESULTS

DEMOGRAPHIC DATA

Six dogs at the age of 2 to 5 years old, were involved. All 6 dogs were enrolled, entirely completed the

research. No side effects related to rePt. Analytes other than aD diagnostic, were entirely normal and within reference ranges involving endocrine profile.

ANALYTES AND LABORATORY RESULTS

All measurable analytes were shown in [Table 2](#) below.

CADESI-04 AND VAS PRURITUS SCORES

Both CADESI-04 and VAS pruritus scores were altered in aD cases. Proposed benchmarks for aD severity by use of CADESI-04 scores revealed.⁸ Pre-treatment day 0 CADESI-04 scores (50-176) belonging to 4 severe and 2 moderate aD cases, were significantly higher than scores on day 10 (7-41) switching the severity of the disease to mild status in 5 out of 6 cases, whereas 1 dog was mild aD. CADESI-04 scores [median (minimum-maximum)] (prior to treatment) was statistically significant 70.5 (50-176) vs. 12 (7-41), in contrast to rePt, respectively. On the other hand, day 0 VAS pruritus scores were (ranging between minimum-maximum 5 to 10) 7.5 (5-10) [median (minimum-maximum)] (prior to treatment), whereas owner VAS pruritus score was decreased to 2 (0-3) [median (minimum-maximum)] ($p=0.026$) ([Table 2](#)). No side effect attributable to the rePt was reported in any dogs with aD. All cases were monitored for 11 months after completion of rePt in which no recurrence was observed. Clinical photographs of a selected case was shown in [Figure 3](#), describing before and after treatment records along with gut microbiota changes. Allergen specific IgE analysis presented at least 1 antigen in each case enrolled (data not relevant to show, solely for diagnostic interpretation). All dogs

TABLE 2: Analytes recorded at the present study. All parameters were dedicated as useful biomarkers for diagnosis of canine atopic dermatitis, as to the present authors practice.

	Bt Median (minimum-maximum)	arePt Median (minimum-maximum)	p value
CADESI-04 scores	70.5 (50-176)	12 (7-41)	0.028
Epidermal hydration	3.5 (0-58)	97 (46-100)	0.028
Epidermal pH	4.9 (4.3-5.7)	7.0 (6.5-7.2)	0.027
VAS scores (1-10)	7.5 (5-10)	2 (0-3)	0.026
Zonulin (ng/mL)	19.5 (9-20)	2.7 (1.5-4.2)	0.028

CADESI-04: Canine Atopic Dermatitis Extent and Severity Index version 4; VAS: Visual analogue scale; Bt: Before treatment; arePt: After rectal enema probiotic treatment.

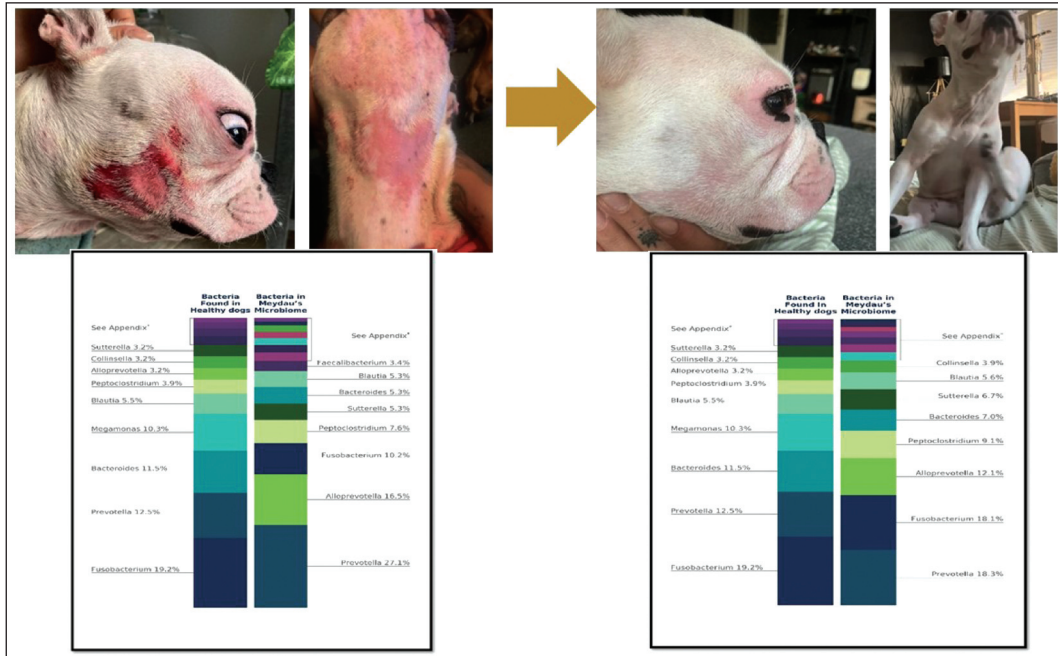


FIGURE 3: One of the cases enrolled in the present study. Clinical photographic records were obtained on day 0 and 10, following rePt. Briefly microbiome analysis were also shown before and after rePt entirely. Left column showed healthy dogs' average microbiome analysis comperatively. rePt: Rectal enema probiotic.

with aD experienced a strong IgE response against storage mites.

ZONULIN LEVELS

Linear graphic showing zonulin levels prior to and after rePt is presented in Figure 4. In dogs with aD participated in the present research, zonulin levels [median (minimum-maximum)] after treatment [2.7 (1.5-4.2) ng/mL] were significantly (p=0.028) decreased in contrast to pre-treatment values [19.5 (9-20) ng/mL].

GUT MICROBIOTA ALTERATIONS

Alpha diversity with respect to OTU richness, evenness and overall diversity was shown in an attempt to show ecological alterations within the dogs with aD via the Shannon indices. Alterations in OTU composition for aD cases involved in the present study, comparatively data involved day 0 (prior to rePt) and day 10, end point of the study. The OTU distribution composed phyla, family and genus levels.

In the present study, a comparison was made at time point day 0 (prior to rePt treatment) and there

afterwards with the completion of the study at time point day 10. The OTU distribution was investigated at the phyla, family and genus levels. At the phylum level, 16S rRNA analysis highlighted the OTU abundance differences, which presented that Firmicutes was significantly higher at time point day 0. At the phylum level, the most common bacteria phyla found (prior to rePt treatment) were as follows: case I (Firmicutes 64.7%, Actinobacteria 20.7% and Fusobacteria 14.0%), case II (Firmicutes 41.0%, Bacteroidetes 37.8%, Actinobacteria 8.8%,

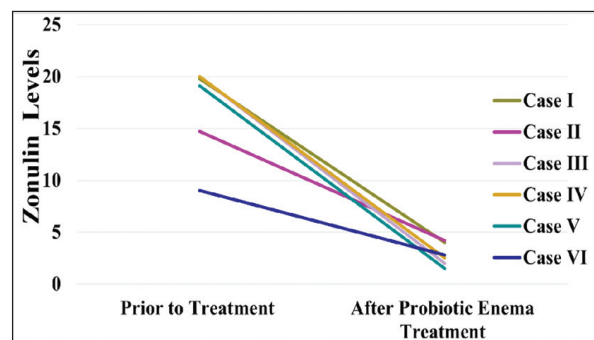


FIGURE 4: Zonulin levels prior to and after probiotic enema treatment in 6 cases enrolled.

Fusobacteria 7.3% and Proteobacteria 5.1%), case III (Firmicutes 50.5%, Fusobacteria 34.8% and Bacteroidetes 13.1%) case IV (Firmicutes 34.6%, Fusobacteria 39% and Bacteroidetes 25.7%). At the family level abundances of Lachnospiraceae (*Blautia* genus 25.5%), Coriobacteriaceae (*Colinella* genus 16.2%) and Streptococcaceae (*Streptococcus* genus 15.1%) were evident in case I. After rePt, case I presented abundance of Enterococcaceae (*Enterococcus* genus 44.8%) and Prevotellaceae (19.7% *Prevotella* genus) families. Relative abundances at the family levels were as follows for other cases: case II [Prevotellaceae (*Prevotella* genus 28.3%) and Fusobacteriaceae (*Fusobacterium* genus 7.3%)]; case III [Prevotellaceae (*Prevotella* genus 18.3%), Fusobacteriaceae (*Fusobacterium* genus 18.1%)] and case IV [Fusobacteriaceae (*Fusobacterium* genus 39.0%) and Bacteroidaceae (*Bacteroides* 25.7%)]. After rePt, relative abundances were characterized as follows and switched to Prevotellaceae [(*Prevotella* genus 35.2%) and Fusobacteriaceae (*Fusobacterium* genus 16.8%)]; Prevotellaceae (*Prevotella* genus 27.1% and *Alloprevotella* genus 16.5%) and Fusobacteriaceae (*Fusobacterium* genus 34.8%) and Lachnospiraceae [(*Ruminococcus*) *gnavus* group genus 21.6%], in case II to IV, respectively. Interestingly following rePt, *Prevotella* genus was significantly detected in association with clinical cure and recovery to those of case I; II and III.

At the genus level, case I showed higher relative abundances of *Blautia*, *Collinsella* and *Streptococcus*, whereas case II and III presented *Prevotella* and *Fusobacterium*. Case IV showed evidence of *Fusobacterium* and *Bacteroides*. Comparatively following rePt, at the genus level were detected as follows: *Enterococcus* (for case I), *Prevotella* (both for case II and III) and *Fusobacterium* (for case IV).

Dogs were monitored for a total of 1 year following completion of the study. None of them were diseased nor recurrence was detected. No observable side effects were detected during the study period, whereas probiotic enema was safely used. All dogs were clinically healthy at the time of writing this manuscript.

DISCUSSION

This treatment modality would have hastened usefulness of probiotics, whereas oral consumption of them would not prevent encountering with the stomach acid. Furthermore regarding the probiotic profits and the optimum route for administration has growing interest and with this study results, it would be foremost modality even in other than veterinary field.

Given aD as foremost cause of pruritus among dogs, inflamed and damaged skin along with dysfunction of the skin barrier involves epithelial cells and tJs. This tJ comprises epithelial barrier functions participating in physio-pathological conditions.¹³ Zonulin, a well recognized 47 kDa protein, has been responsible for elevated small intestinal permeability acting in the intestinal innate immune system.¹⁴ The latter biomarker, is the only recognized physiological protein reversibly modulating intestinal permeability by intercellular tJ, has increased expression within autoimmune disorders where the dysfunction of tJ participates.¹⁵⁻¹⁷ It has been postulated that tJ might participate within the pathophysiology of aD.¹⁷

In a prior study, serum zonulin concentrations of aD children and healthy ones, were detected. In that research, the aD children presented a significantly increased ($p < 0.001$) median serum zonulin level in contrast to the controls (11.00 ng/mL vs 7.8).¹⁸ *L. plantarum* CJLP133 treatment resulted with suppression of aD whereas another strain *L. paracasei* NCC 2461 alleviated skin sensitivity and hydration.^{5,6} *L. plantarum* successfully hydrates the epidermis through the modulating ceramidase mRNA and serine palmitoyltransferase levels.¹⁹ Another clinical research comprised 110 healthy people with wrinkles and dry skin, to those of *L. plantarum* HY7714 ingestion altered skin hydration and diminished wrinkle depth.²⁰ Given the latter study, *L. plantarum* HY7714 also affected gut microbiome with remarkable taxonomic differences and caused diminished inflammatory biomarkers. Strikingly according to the latter authors, *L. plantarum* HY7714 presented regulatory effect on gut tissue.²¹ On the

other hand, the same strain HY7714 ameliorate gut barrier integrity and suggested as probable treatment armamentarium for dysfunctions caused by tJ defects.²² Furthermore arousing data denoted that lactobacilli modify gut permeability in humanbeings.²³ *L. plantarum* strain altered relocation of ZO-1 and occludin in cells located at duodenum solely after 6 hours of ingestion.^{24,25} It was also suggested that probiotics probably increase tJ functions even if intestinal barrier function is abnormal.²⁶ In the present study, tJ functions were detected by zonulin levels. To those of dogs with aD enrolled in this study, zonulin levels after treatment were significantly decreased in contrast to pre-treatment values. Given elevated zonulin level causes an increase of intestinal permeability and foreign antigen entry, a significant decrease in circulating zonulin levels following probiotic enema treatment modality in the present study, suggesting that rePt might decrease zonulin in dogs with aD. Zonulin, a well known haptoglobin precursor, regulates the permeability of tJ among digestive tract cells.^{26,27} As elevations in zonulin is related to elevated gut permeability, zonulin elucidation is provoked by local/systemic subclinical inflammation, which is also evident in aD.²⁸ Given tJ defects obtained in humans with aD, circulating zonulin levels is associated with the presence and severity of aD in children, elevated zonulin levels among allergic pediatric cases, *L. plantarum* 1) Restoration of tJ defects and epithelial barrier functions, 2) Modulatory effects on skin health through improving intestinal condition, the effectiveness of *Lactobacillus casei* and *Lactobacillus rhamnosus* in children with aD all supported the efficacy of rePt modality in the present study.^{17,19,22,24,29,30} To the present authors, knowledge of this treatment modality would be a role model for future therapeutic interventions. As elevated zonulin might 1) Lead to an alteration in gut permeability, 2) Diminish the integrity of the intestinal barrier which would result with an entry dietary antigen to facilitate mucosal immune players, we, with our preliminary results in a limited subset of dogs with aD, proposed that rePt effect on zonulin and thereof short term gut microbiota alterations might be related to the

probiotic effect on the probable gut and modulation of intestinal microbiota, as was supported within 16S rRNA analysis in this study. Furthermore probiotics, especially to the best of our knowledge when given with rectal route, as in this study, boost the immunoregulation and integrity of the gut epithelial barrier as proven that HY7714 strain presented restorative efficacy against tJ defects in intestinal Caco-2 cells in humans.^{22,30,31} The latter *Lactobacillus* strain altered tJ proteins induced by tumor necrosis factor- α , and attenuated levels of pro-inflammatory cytokines reasonably decrease tJ permeability. According to the latter researchers, HY7714 might enhance skin disorder by stabilization of intestinal permeability.²² In parallel line, a mice study denoted that *L. paracasei* strain, which is also another choice of probiotic strain used as an enema in the present study, 1) Altered T regulatory cells and cytokines, 2) Protected intestinal mucus layer and tJ, 3) Enhanced diversity and composition of intestinal microbiome, 4) Prevented (probably) inflammatory bowel disease.³²

L. plantarum IS-10506, a novel probiotic, isolated from an Indonesian fermented buffalo milk, 1) Suppressed allergic reactions in BALB/c mice via acting T-regulatory cells cytokines through equating Th1/Th2 immune response, and 2) Resulted in decreased Scoring Atopic Dermatitis Index and circulating concentrations of interferon- γ , interleukin-4 and interleukin-17 in contrast to the placebo group among children with aD.^{33,34} According to the latter study, *L. plantarum* IS-10506 was suggested as a therapeutic option for children with aD.³² In our study, CADESI-04 and VAS pruritus scores tended to decrease (prior to treatment vs. rePt) significantly. Moreover corneometric analysis deemed clinical recovery as epidermal hydration and pH values improved with a relatively short term rePt. This positive impact on skin inflammation and diminished pruritus after application of rePt in this model of aD in dogs probably presented withdrawal of chronic barrier disruption and healed tJ. In parallel with the intestinal balance (restoration of gut microbiome along with 16S rRNA analysis performed in this study), probiotics (the first authors' several years experience) of are

recognized to present beneficial effects not only on skin inflammation, but also for restoration of gut microbiota. It should not be unwise to draw preliminary conclusion that the selected *Lactobacillus* probiotic strains potentially regulate on skin health by the manipulation of the gut microbiome.³⁵

CONCLUSION

In conclusion, the positive impact on skin inflammation and diminished pruritus after application of rePt in this model of aD in dogs probably presented withdrawal of chronic barrier disruption and healed tJs. The selected *Lactobacillus* probiotic strains used as an enema potentially regulate on skin health by the manipulation of the gut microbiome resulted with intestinal balance.

Source of Finance

During this study, no financial or spiritual support was received neither from any pharmaceutical company that has a direct

connection with the research subject, nor from a company that provides or produces medical instruments and materials which may negatively affect the evaluation process of this study.

Conflict of Interest

No conflicts of interest between the authors and / or family members of the scientific and medical committee members or members of the potential conflicts of interest, counseling, expertise, working conditions, share holding and similar situations in any firm.

Authorship Contributions

Idea/Concept: Kerem Ural; **Design:** Kerem Ural, Hasan Erdoğan, İlker Camkerten; **Control/Supervision:** Kerem Ural; **Data Collection and/or Processing:** Songül Erdoğan, Hasan Erdoğan, Nurcan Şahin; **Analysis and/or Interpretation:** Kerem Ural, Hasan Erdoğan, İlker Camkerten, Songül Erdoğan, Nurcan Şahin; **Literature Review:** Kerem Ural, Hasan Erdoğan, Nurcan Şahin; **Writing the Article:** Kerem Ural; **Critical Review:** Kerem Ural, Hasan Erdoğan; **References and Fundings:** Kerem Ural; **Materials:** Kerem Ural, Hasan Erdoğan, Nurcan Şahin, İlker Camkerten, Songül Erdoğan.

REFERENCES

- O'Neill CA, Monteleone G, McLaughlin JT, Paus R. The gut-skin axis in health and disease: A paradigm with therapeutic implications. *Bioessays*. 2016;38(11):1167-76. [[Crossref](#)] [[PubMed](#)]
- De Pessemer B, Grine L, Debaere M, Maes A, Paetzold B, Callewaert C. Gut-skin axis: current knowledge of the interrelationship between microbial dysbiosis and skin conditions. *Microorganisms*. 2021;9(2):353. [[Crossref](#)] [[PubMed](#)] [[PMC](#)]
- Nam B, Kim SA, Park SD, Kim HJ, Kim JS, Bae CH, et al. Regulatory effects of *Lactobacillus plantarum* HY7714 on skin health by improving intestinal condition. *PLoS One*. 2020;15(4):e0231268. [[Crossref](#)] [[PubMed](#)] [[PMC](#)]
- Han Y, Kim B, Ban J, Lee J, Kim BJ, Choi BS, et al. A randomized trial of *Lactobacillus plantarum* CJLP133 for the treatment of atopic dermatitis. *Pediatr Allergy Immunol*. 2012;23(7):667-73. [[Crossref](#)] [[PubMed](#)]
- Gueniche A, Philippe D, Bastien P, Reuteler G, Blum S, Castiel-Higounenc I, et al. Randomised double-blind placebo-controlled study of the effect of *Lactobacillus paracasei* NCC 2461 on skin reactivity. *Benef Microbes*. 2014;5(2):137-45. [[Crossref](#)] [[PubMed](#)]
- Olivry T, Saridomichelakis M, Nuttall T, Bensignor E, Griffin CE, Hill PB; International Committee on Allergic Diseases of Animals (ICADA). Validation of the Canine Atopic Dermatitis Extent and Severity Index (CADESI)-4, a simplified severity scale for assessing skin lesions of atopic dermatitis in dogs. *Vet Dermatol*. 2014;25(2):77-85, e25. [[Crossref](#)] [[PubMed](#)]
- Hill PB, Lau P, Rybnicek J. Development of an owner-assessed scale to measure the severity of pruritus in dogs. *Vet Dermatol*. 2007;18(5):301-8. [[Crossref](#)] [[PubMed](#)]
- Cosgrove SB, Wren JA, Cleaver DM, Walsh KF, Follis SI, King VI, et al. A blinded, randomized, placebo-controlled trial of the efficacy and safety of the Janus kinase inhibitor oclacitinib (Apoquel®) in client-owned dogs with atopic dermatitis. *Vet Dermatol*. 2013;24(6):587-97, e141-2. [[Crossref](#)] [[PubMed](#)] [[PMC](#)]
- Comeau AM, Douglas GM, Langille MG. Microbiome helper: a custom and streamlined workflow for microbiome research. *mSystems*. 2017;2(1):e00127-16. [[Crossref](#)] [[PubMed](#)] [[PMC](#)]
- Pichler R, Fritz J, Tulchiner G, Klinglmair G, Soleiman A, Horninger W, et al. Increased accuracy of a novel mRNA-based urine test for bladder cancer surveillance. *BJU Int*. 2018;121(1):29-37. [[Crossref](#)] [[PubMed](#)]
- Callahan BJ, McMurdie PJ, Rosen MJ, Han AW, Johnson AJ, Holmes SP. DADA2: High-resolution sample inference from Illumina amplicon data. *Nat Methods*. 2016;13(7):581-3. [[Crossref](#)] [[PubMed](#)] [[PMC](#)]
- Quast SA, Berger A, Eberle J. ROS-dependent phosphorylation of Bax by wortmannin sensitizes melanoma cells for TRAIL-induced apoptosis. *Cell Death Dis*. 2013;4(10):e839. [[Crossref](#)] [[PubMed](#)] [[PMC](#)]
- Lee DB, Huang E, Ward HJ. Tight junction biology and kidney dysfunction. *Am J Physiol Renal Physiol*. 2006;290(1):F20-34. [[Crossref](#)] [[PubMed](#)]
- El Asmar R, Panigrahi P, Bamford P, Berti I, Not T, Coppa GV, et al. Host-dependent zonulin secretion causes the impairment of the small intestine barrier function after bacterial exposure. *Gastroenterology*. 2002;123(5):1607-15. Erratum in: *Gastroenterology* 2003;124(1):275. El Asmar Rahzi [corrected to El Asmar Ramzi]. [[Crossref](#)] [[PubMed](#)]
- Fasano A. Regulation of intercellular tight junctions by zonula occludens toxin and its eukaryotic analogue zonulin. *Ann N Y Acad Sci*. 2000;915:214-22. [[Crossref](#)] [[PubMed](#)]

16. Fasano A, Not T, Wang W, Uzzau S, Berti I, Tommasini A, et al. Zonulin, a newly discovered modulator of intestinal permeability, and its expression in coeliac disease. *Lancet*. 2000;355(9214):1518-9. [[Crossref](#)] [[Pubmed](#)]
17. De Benedetto A, Rafaels NM, McGirt LY, Ivanov AI, Georas SN, Cheadle C, et al. Tight junction defects in patients with atopic dermatitis. *J Allergy Clin Immunol*. 2011;127(3):773-86.e1-7. [[Crossref](#)] [[Pubmed](#)] [[PMC](#)]
18. Sheen YH, Jee HM, Kim DH, Ha EK, Jeong IJ, Lee SJ, et al. Serum zonulin is associated with presence and severity of atopic dermatitis in children, independent of total IgE and eosinophil. *Clin Exp Allergy*. 2018;48(8):1059-62. [[Crossref](#)] [[Pubmed](#)]
19. Ra J, Lee DE, Kim SH, Jeong JW, Ku HK, Kim TY, et al. Effect of oral administration of *Lactobacillus plantarum* HY7714 on epidermal hydration in ultraviolet B-irradiated hairless mice. *J Microbiol Biotechnol*. 2014;24(12):1736-43. [[Crossref](#)] [[Pubmed](#)]
20. Lee DE, Huh CS, Ra J, Choi ID, Jeong JW, Kim SH, et al. Clinical evidence of effects of *Lactobacillus plantarum* HY7714 on skin aging: a randomized, double blind, placebo-controlled study. *J Microbiol Biotechnol*. 2015;25(12):2160-8. [[Crossref](#)] [[Pubmed](#)]
21. Ahrne S, Hagslåt ML. Effect of lactobacilli on paracellular permeability in the gut. *Nutrients*. 2011;3(1):104-17. [[Crossref](#)] [[Pubmed](#)] [[PMC](#)]
22. Nam B, Kim SA, Nam W, Jeung WH, Park SD, Lee JL, et al. *Lactobacillus plantarum* HY7714 restores TNF- α induced defects on tight junctions. *Prev Nutr Food Sci*. 2019;24(1):64-9. [[Crossref](#)] [[Pubmed](#)] [[PMC](#)]
23. Karczewski J, Troost FJ, Konings I, Dekker J, Kleerebezem M, Brummer RJ, et al. Regulation of human epithelial tight junction proteins by *Lactobacillus plantarum* in vivo and protective effects on the epithelial barrier. *Am J Physiol Gastrointest Liver Physiol*. 2010;298(6):G851-9. [[Crossref](#)] [[Pubmed](#)]
24. Sultana R, McBain AJ, O'Neill CA. Strain-dependent augmentation of tight-junction barrier function in human primary epidermal keratinocytes by *Lactobacillus* and *Bifidobacterium* lysates. *Appl Environ Microbiol*. 2013;79(16):4887-94. [[Crossref](#)] [[Pubmed](#)] [[PMC](#)]
25. Rittirsch D, Flierl MA, Nadeau BA, Day DE, Huber-Lang MS, Grailer JJ, et al. Zonulin as prehepato-globin2 regulates lung permeability and activates the complement system. *Am J Physiol Lung Cell Mol Physiol*. 2013;304(12):L863-72. [[Crossref](#)] [[Pubmed](#)] [[PMC](#)]
26. Pacifico L, Bonci E, Marandola L, Romaggioli S, Bascetta S, Chiesa C. Increased circulating zonulin in children with biopsy-proven nonalcoholic fatty liver disease. *World J Gastroenterol*. 2014;20(45):17107-14. [[Crossref](#)] [[Pubmed](#)] [[PMC](#)]
27. Küme T, Acar S, Tuhan H, Çatlı G, Anık A, Gürsoy Çalan Ö, et al. The relationship between serum zonulin level and clinical and laboratory parameters of childhood obesity. *J Clin Res Pediatr Endocrinol*. 2017;9(1):31-8. Erratum in: *J Clin Res Pediatr Endocrinol*. 2020;12(3):331. [[Crossref](#)] [[Pubmed](#)] [[PMC](#)]
28. Yamaide F, Fikri B, Nakano T, Shimojo N. Serum zonulin levels are higher in pediatric allergic patients than those in healthy children. *World Allergy Organ J*. 2020;13(8):122. [[Crossref](#)]
29. Cukrowska B, Ceregra A, Maciorkowska E, Surowska B, Zegadlo-Mylik MA, Konopka E, et al. The effectiveness of probiotic *Lactobacillus rhamnosus* and *Lactobacillus casei* strains in children with atopic dermatitis and cow's milk protein allergy: a multicenter, randomized, double blind, placebo controlled study. *Nutrients*. 2021;13(4):1169. [[Crossref](#)] [[Pubmed](#)] [[PMC](#)]
30. Brown M. Modes of action of probiotics: recent developments. *J Anim Vet Adv*. 2011;10(14):1895-900. [[Crossref](#)]
31. Bajaj BK, Claes IJ, Lebeer S. Functional mechanisms of probiotics. *JMBFS*. 2015;4(4):321-7. [[Crossref](#)]
32. Kim WK, Jang YJ, Seo B, Han DH, Park S, Ko G. Administration of *Lactobacillus paracasei* strains improves immunomodulation and changes the composition of gut microbiota leading to improvement of colitis in mice. *J Funct Foods*. 2019;52:565-75. [[Crossref](#)]
33. Surono IS, Nishigaki T, Endaryanto A, Waspo P. Indonesian biodiversities, from microbes to herbal plants as potential functional foods. *Journal of the Faculty of Agriculture Shinshu University*. 2008;44(1):23-7. [[Link](#)]
34. Prakoeswa CRS, Herwanto N, Prameswari R, Astari L, Sawitri S, Hidayati AN, et al. *Lactobacillus plantarum* IS-10506 supplementation reduced SCORAD in children with atopic dermatitis. *Benef Microbes*. 2017;8(5):833-40. [[Crossref](#)] [[Pubmed](#)]
35. Ural K. Veteriner İç Hastalıklarında Probiyotikler Probiyotik Kullanımı Rehber Kitabı ve Olgu Atlası. 1. Baskı. Ankara: Yayın Yeri: Atalay Konfeksiyon Matbaacılık ve Reklamcılık İnşaat Turizm Otomotiv San. ve Tic. Ltd. Sti.; 2020.