

# Keratoconus in a Case with Scleroderma: A Rare Coexistence

## Sklerodermalı Bir Olguda Keratokonus Varlığı: Nadir Bir Birliktelik

Mustafa Alpaslan ANAYOL,<sup>a</sup>  
Mehmet COŞKUN,<sup>b</sup>  
Sabri RAZA,<sup>c</sup>  
Nurullah ÇAĞIL,<sup>d</sup>  
Hasan Basri ÇAKMAK,<sup>e</sup>  
Şaban ŞİMŞEK<sup>f</sup>

<sup>a</sup>Clinic of Ophthalmology,  
Ulucanlar Eye Training and  
Research Hospital,  
Ankara

<sup>b</sup>Department of Ophthalmology,  
Karabük University Faculty of Medicine,  
Karabük

<sup>c</sup>American Hospital, American Eye Center,  
Tirane, Albania

<sup>d</sup>Clinic of Ophthalmology,  
Atatürk Training and Research Hospital,

<sup>e</sup>Department of Ophthalmology,  
Kastamonu University Faculty of Medicine,  
Kastamonu

<sup>f</sup>Clinic of Ophthalmology,  
Haydarpaşa Numune Training and  
Research Hospital,  
İstanbul

Received: 05.04.2016

Received in revised form: 13.07.2016

Accepted: 26.08.2016

Available online: 22.02.2018

Correspondence:

Mustafa Alpaslan ANAYOL  
Ulucanlar Eye Training and  
Research Hospital,  
Clinic of Ophthalmology, Ankara,  
TÜRKİYE/TURKEY  
dranayol@yahoo.com

**ABSTRACT** A 50 year-old female admitted to the hospital with the complaint of decreased vision, burning and grittiness in her eyes. The diagnosis of scleroderma had been made by a rheumatologist seven years ago. On presentation, her best corrected visual acuity was 8/10 in the right eye and 5/10 in the left eye. Central corneal thickness measured by an ultrasonic pachymeter was 455 micrometer ( $\mu\text{m}$ ) in the right eye and 423  $\mu\text{m}$  in the left eye. Corneal topography showed bilateral central steepening consistent with diagnosis of keratoconus. Schirmer tear test (after topical local anesthetic) was 2 mm/5 minute bilaterally. Break-up time was 1 second bilaterally. Her physical features related to scleroderma included tightness of the skin, per-oral puckering and facial telangiectasia of her face as well as flexion contracture on her fingers. This is the first case report in the literature describing the association of keratoconus with scleroderma. Although scleroderma is usually associated with increased central corneal thickness, it can also rarely be associated with keratoconus like ectatic corneal disorders.

**Keywords:** Keratoconus; scleroderma, systemic

**ÖZET** Elli yaşındaki kadın hasta gözlerinde yanma, batma ve görme azalması şikayeti ile hastanemize başvurdu. Yedi yıl önce bir romatoloji kliniği tarafından skleroderma tanısı almıştı. Başvuru anında en iyi düzeltilmiş görme keskinliği sağ gözde 8/10 ve sol gözde 5/10 idi. Ultrasonik pakimetre ile ölçülen merkezi kornea kalınlığı sağ gözde 455 mikrometre ( $\mu\text{m}$ ) ve sol gözde 423  $\mu\text{m}$  idi. Kornea topografisinde keratokonus ile uyumlu merkezi dikleşmesi mevcuttu. Topikal anestezi sonrası Schirmer testi her iki gözde 2 mm/5 dakika idi. Gözyaşı kırılma zamanı her iki gözde 1 saniye idi. Sklerodermanın fiziksel özellikleri olarak özellikle yüz bölgesinde cilt sıkılığı, yüzde telenjektaziler ve bunun yanı sıra parmaklarda fleksiyon kontraktürü mevcuttu. Bu olgu skleroderma ile keratokonus birlikteliğini bildiren ilk olgudur. Skleroderma daha çok artmış merkezi kornea kalınlığı ile bildirilmiş olmasına rağmen nadiren keratokonus gibi korneanın ektatik hastalıkları ile de birlikte görülebilir.

**Anahtar Kelimeler:** Keratokonus; skleroderma, sistemik

Scleroderma or systemic sclerosis (SSc) is a chronic multi-system disorder predominantly affecting the skin, musculoskeletal, gastrointestinal, pulmonary and renal systems.<sup>1</sup>

Corneal involvement in SSc is rare. Filamentous keratitis, exposure keratitis (secondary to lid changes), peripheral ulcerative keratitis, pellucid marginal degeneration and increase in the central corneal thickness (CCT) have all been reported to be associated with SSc.<sup>2-5</sup>

Keratoconus is a progressive non-inflammatory corneal ectasia. It is a bilateral and asymmetric corneal disease characterized by localized corneal thinning that leads to protrusion of the thinned cornea.<sup>6</sup>

In this paper we describe a patient with SSc and keratoconus. To our knowledge, in the literature there is no other case report that describes presence of keratoconus in patients with SSc.

## CASE REPORT

A 50 year-old female admitted to the hospital with the complaint of decreased vision, burning and grittiness in her eyes. The patient had been followed for seven years by her rheumatologist with the diagnosis of SSc. On presentation, her best corrected visual acuity was 8/10 in the right eye and 5/10 in the left eye. Manifest refractions were +0.50 (+1.50 $\alpha$ 98) diopter (D) in the right eye and -0.50 (-2.50 $\alpha$ 170) D in the left eye. Keratometry values were 49.47 $\alpha$ 93° D, 47.18 $\alpha$ 3° D in the right eye; 53.59 $\alpha$ 86° D, 50.15 $\alpha$ 176° D in the left eye. White to white cornea diameter was 11.79 mm in the right eye, 11.75 mm in the left eye. "Scissors" reflex was present in both eyes on retinoscopy. Slit lamp examination revealed normal conjunctival fornices, clear corneas with no evidence of inflammation, vascularization or ulceration. There wasn't Vogt's stria, Fleischer ring and apical scar. There was no history of eye surgery or inflammatory eye disease. Corneal sensation was intact bilaterally. Intraocular pressure measured with Goldmann applanation tonometry was 17 mmHg bilaterally. Minimal nuclear sclerosis of the lens was present in both eyes. Fundus examinations of both eyes did not reveal any pathology. CCT measured by an ultrasonic pachymeter was 455 micrometer ( $\mu$ m) in the right eye and 423  $\mu$ m in the left eye. Schirmer tear test (after topical local anesthesia) was 2 mm / 5 minute bilaterally. Break-up time was 1 second bilaterally.

Corneal topography (Keratron Corneal Analyzer, Optikron, Italy) showed bilateral central steepening of the cornea consistent with the diagnosis of keratoconus (Figure 1).

Her physical features of scleroderma included tightness of the skin, per-oral puckering and facial telangiectasia of her face as well as flexion contracture on her fingers (Figures 2a-b). The computerized visual field test and fundus angiography were within normal limits.

For her dry eye symptoms, patient was prescribed non-preserved topical lubricants. The patient was offered hard contact lenses but she did not accept to use lenses, so that glasses were prescribed.

## DISCUSSION

Scleroderma or systemic sclerosis (SSc) is a chronic multi-system disorder predominantly affecting the skin, musculoskeletal, gastrointestinal, pulmonary and renal systems. Although the exact etiology is unknown, recent evidence suggest that immune activation plays a pivotal role in the pathogenesis.<sup>1</sup> The most apparent clinical features of SSc are Raynaud's phenomenon and dermal thickening with attachment of the skin to underlying tissues, which is manifested by taut skin, pursed lip, mask-like face and tapering of the digits.<sup>2</sup>

The most common ocular findings of SSc include keratoconjunctivitis sicca, shallow conjunctival fornices, thickening and tightness of the eyelids and occlusive choroidal vascular disease.<sup>1,2</sup> The most frequent ocular manifestation of SSc is keratoconjunctivitis sicca, which has been reported to be present in 37-79% of patients.<sup>3,7-9</sup> Depending on its severity, keratoconjunctivitis sicca can be present with mucous strands in the precorneal tear film, superficial keratopathy, punctate keratopathy or filamentary keratitis.<sup>3,7</sup> In the presented case, the tests revealed dry eye, but mucous filaments, superficial and filamentous keratitis were not present in the biomicroscopy.

Type I collagen is the major component in the cornea, comprising about 68% of the dry weight of the cornea. In addition, collagen types III, V, VI, XII, and XIV have all been detected in the corneal stroma.<sup>10</sup> The cornea is particularly vulnerable to collagen vascular diseases due to its collagen composition and relation to the rich vascular supply of the conjunctiva and episclera.<sup>2</sup> Peripheral corneal thinning is the result of obliterative microangiitis from deposition of immune complexes in the limbal vasculature, especially in the setting of scleral inflammation. Collagenases and proteases, released by infiltrating leukocytes and activated stromal keratocytes, degrade stromal collagen.<sup>2</sup>

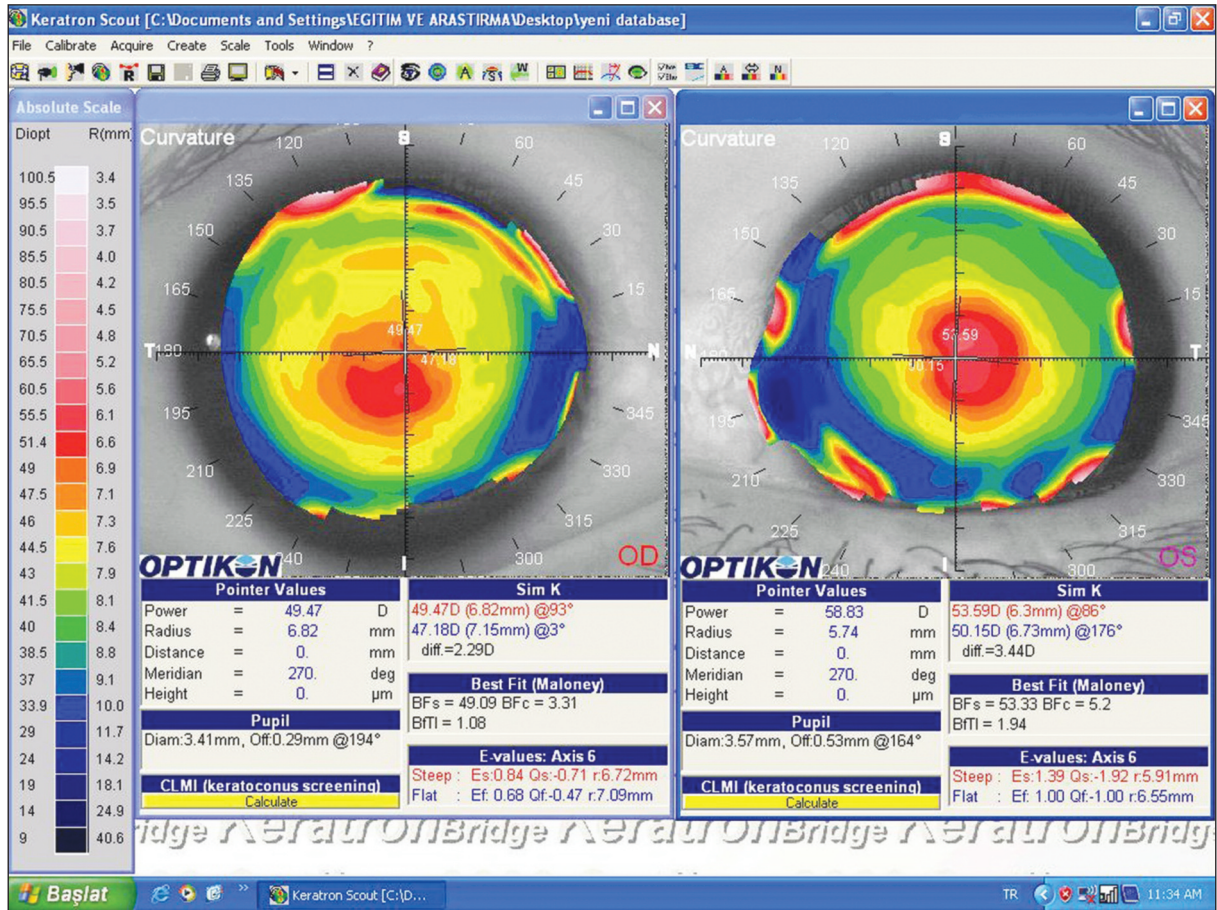


FIGURE 1: Corneal topography showing bilateral central steepening of the cornea.

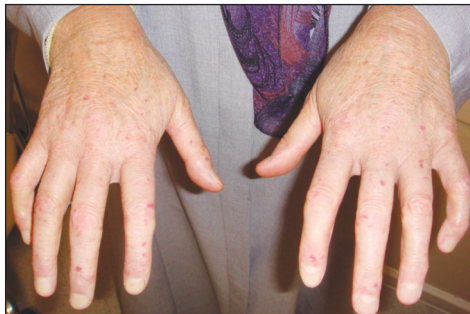

FIGURE 2a: This picture shows flexion contractures of the fingers.

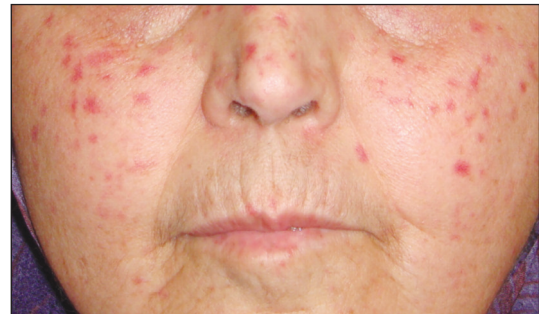

FIGURE 2b: This picture shows per-oral puckering and facial telangiectasia.

Corneal involvement in scleroderma is rare. Peripheral corneal thinning associated with scleroderma is more often inflammatory and ulcerative. Filamentous keratitis, exposure keratitis (secondary to lid changes) and peripheral ulcerative keratitis have all been reported to be associated with SSc.<sup>2-5,11</sup> Extracellular matrix overproduction by fibroblasts is the hallmark of SSc. Activated fibroblasts over-

produce extracellular matrix proteins, such as collagen type I, III, V, VI and VII, tenascin, proteoglycans, fibronectin, laminin and fibrillin-1. Ultrastructural studies showed collagen fibrils were increased in histopathology of SSc.<sup>12</sup> Two studies found statistically significant increased CCT in patients with SSc compared to matched controls.<sup>5,11</sup> However two studies showed no difference in CCT

of patients with SSc compared to matched controls.<sup>13,14</sup> They concluded that this phenomenon may be due to medical treatment of the scleroderma patients. So this issue remains unclear if the CCT of SSc patients are affected in the disease process.

Corneal ectasias, such as pellucid marginal degeneration (PMD) in a SSc case have been reported in the literature.<sup>2</sup> PMD is a non-inflammatory peripheral corneal thinning and it is not associated with signs of inflammation, vascularization or infiltrates. Corneal topography typically shows flattening in the vertical meridian with marked steepening inferiorly below the site of thinning that extends into the infero oblique meridian.<sup>2</sup> In contrast, the thinning in keratoconus occurs at the apex of conical shape, corneal protrusion and the steepening is the greatest at the apex of the cone and reduces concentrically towards the periphery, as with this case (Figure 1). It has been suggested that PMD and keratoconus may be different manifestations of the same etiological factor.<sup>15</sup>

In 1953, Agatston reported a case describing retinopathy in a SSc patient.<sup>16</sup> He claimed that scleroderma may also be associated with other eye disorders including keratoconus. However no association of scleroderma with keratoconus was reported in the literature yet. To the best of our

knowledge, our case is the first report in the literature presenting keratoconus in a scleroderma patient.

In conclusion, keratoconus can be associated with scleroderma. Since scleroderma is usually associated with increased central corneal thickness, in this first report in the literature, we presented the rare association of scleroderma with keratoconus.

#### Source of Finance

*During this study, no financial or spiritual support was received neither from any pharmaceutical company that has a direct connection with the research subject, nor from a company that provides or produces medical instruments and materials which may negatively affect the evaluation process of this study.*

#### Conflict of Interest

*No conflicts of interest between the authors and / or family members of the scientific and medical committee members or members of the potential conflicts of interest, counseling, expertise, working conditions, share holding and similar situations in any firm.*

#### Authorship Contributions

**Idea/Concept:** Mustafa Alpaslan Anayol; **Design:** Mehmet Coşkun; **Control/Supervision:** Şaban Şimşek; **Data Collection and/or Processing:** Sabri Raza; **Analysis and/or Interpretation:** Nurullah Çağıl; **Literature Review:** Sabri Raza; **Writing the Article:** Mustafa Alpaslan Anayol, Sabri Raza; **Critical Review:** Hasan Basri Çakmak.

## REFERENCES

- Taylor R, Gupta A, Herrick A, Kwartz J. Ocular manifestations of scleroderma. *Surv Ophthalmol* 2009;54(2):292-304.
- Sii F, Lee GA, Sanfilippo P, Stephensen DC. Pellucid marginal degeneration and scleroderma. *Clin Exp Optom* 2004;87(3):180-4.
- Horan EC. Ophthalmic manifestations of progressive systemic sclerosis. *Br J Ophthalmol* 1969;53(6):388-92.
- Horie K, Nishi M, Sawa M, Mochizuki M. [A case of peripheral corneal ulcer accompanied by progressive systemic sclerosis]. *Nippon Ganka Gakkai Zasshi* 1992;96(7):922-9.
- Serup L, Serup J, Hagdrup HK. Increased central cornea thickness in systemic sclerosis. *Acta Ophthalmol (Copenh)* 1984;62(1):69-74.
- Romero-Jiménez M, Santodomingo-Rubido J, Wolffsohn JS. Keratoconus: a review. *Cont Lens Anterior Eye* 2010;33(4):157-66.
- Alarcón-Segovia D, Ibáñez G, Hernández-Ortiz J, Velázquez-Forero F, González-Jiménez Y. Sjögren's syndrome in progressive systemic sclerosis (scleroderma). *Am J Med* 1974;57(1):78-85.
- Kirkham TH. Scleroderma and Sjögren's syndrome. *Br J Ophthalmol* 1969;53(2):131-3.
- West RH, Barnett AJ. Ocular involvement in scleroderma. *Br J Ophthalmol* 1979;63(12):845-7.
- Meek KM, Fullwood NJ. Corneal and scleral collagens--a microscopist's perspective. *Micron* 2001;32(3):261-72.
- Serup J, Serup L. Increased central cornea thickness in localized scleroderma (morphoea). *Metab Pediatr Syst Ophthalmol* 1985;8(2-3):11-4.
- Tamby MC, Chanseaud Y, Guillevin L, Mouthon L. New insights into the pathogenesis of systemic sclerosis. *Autoimmun Rev* 2003;2(3):152-7.
- Emre S, Kayıkçıoğlu O, Ateş H, Cinar E, Inceoğlu N, Yargucu F, et al. Corneal hysteresis, corneal resistance factor, and intraocular pressure measurement in patients with scleroderma using the Reichert ocular response analyzer. *Cornea* 2010;29(6):628-31.
- Palamar M, Seyhan Karatepe A, Egrilmez S, Yagci A. [Evaluation of cornea and anterior chamber with pentacam in scleroderma cases]. *TJO* 2011;41(4):221-4.
- Kayazawa F, Nishimura K, Kodama Y, Tsuji T, Itoi M. Keratoconus with pellucid marginal corneal degeneration. *Arch Ophthalmol* 1984;102(6):895-6.
- Agatston HJ. Scleroderma with retinopathy. *Am J Ophthalmol* 1953;36(1):120-1.