

Infected Primary Muscular Hydatid Disease at Posterior Cruris, A Very Rare Localization: Case Report

Cruris Posteriorıda Enfekte Primer Musküler Hidatik Hastalığı, Çok Nadir Bir Lokalizasyon

Meriç ÜNAL, MD, Msc,^a
Bünyamin GÜRBULAK, MD, Msc,^b
Sezer VATANSEVER, MD, Msc,^c
Demet ÖKKE, MD, Msc,^d
Mustafa ŞİT, MD, Assis.Prof.,^b
Esin GÜRBULAK, MD, Msc^b

^aClinic of Orthopedic,
Isparta Private Şifa Hospital, Isparta
Clinics of

^bGeneral Surgery,

^cRadiology,

^dInfectious Diseases,
Doğubayazıt State Hospital,
Ağrı

Geliş Tarihi/Received: 19.04.2010
Kabul Tarihi/Accepted: 14.01.2011

Yazışma Adresi/Correspondence:

Meriç ÜNAL, MD, Msc
Isparta Özel Şifa Hospital,
Clinic of Orthopedic, Isparta,
TÜRKİYE/TURKEY
abdmunal@yahoo.com

ABSTRACT A parasitic tapeworm, *Echinococcus*, causes hydatid disease. Disease is mostly seen in the abdominal and thoracic organs but can be seen in other tissues as well. Hydatid cysts of the extremities mostly present themselves in the subcutaneous region. Muscular hydatid cysts generally occur secondary to abdominal or thoracic hydatid disease. Primary muscular hydatidosis is a very rare disease and mostly seen in the gluteal and thigh muscles. Distal muscles are very rare localizations for primary muscular hydatidosis cases. In the treatment, surgical excision is the gold standard. Medical treatment is generally preferred after surgery. Here, we present an isolated infected primary muscular hydatid cyst in the deep posterior cruris muscles, which also surrounds the posterior neurovascular structures.

Key Words: Echinococcosis; orthopedics

ÖZET Bir parazit olan *Echinococcus*, hidatik hastalığa neden olmaktadır. Hastalık en sık olarak abdominal ve torasik organlarda görülebilmekle birlikte diğer dokularda da görülebilmektedir. Ekstremitelerin hidatik kistleri en sık subkütan olarak görülürler. Musküler hidatik kistler genelde abdominal ve torasik hidatik hastalığa sekonder olarak gelişirler. Primer musküler hidatidosis çok nadir görülür ve görüldüğünde de en sık olarak gluteal ve uyluk kaslarında karşımıza çıkarlar. Distal kaslar primer musküler hidatidosis olgularında çok nadir karşımıza çıkarlar. Tedavide cerrahi eksizyon altın standarttır. Medikal tedavi genelde cerrahi tedaviden sonra tercih edilir. Burada biz derin posterior cruris kaslarında posterior nörovasküler yapıları saran izole, enfekte bir primer musküler hidatik kist olgusu sunmaktayız.

Anahtar Kelimeler: Ekinokokkozis; ortopedi

Türkiye Klinikleri J Med Sci 2012;32(2):555-8

A parasitic tapeworm, *Echinococcus*, causes hydatid disease. *E. granulosus* and *E. alveolaris* are important for human infections. *Echinococcus* manifestations are endemic in Central Asia, Middle East, Northern Canada, Mediterranean Region and South America.¹

Hydatid disease is mostly seen in the abdominal (mostly liver and kidneys) and thoracic (lungs) regions. In addition, disease can occur in the brain, heart, bone, soft tissue, muscle, spinal cord, spleen and many other organs. Cysts generally settle in the organ that has an excessive blood supply.²

In muscular hydatidosis, primary foci are generally thoracic and abdominal organs. However, muscular involvement is very unusual.³ In the

literature, most of the case reports presented with muscular hydatid cysts had their lesions in gluteal and thigh muscles.³⁻⁹

Here, we present an isolated infected primary muscular hydatid cyst in the deep posterior cruris muscles, which also surrounds the posterior neurovascular structures.

CASE REPORT

A 39-year-old woman applied with the complaint of swelling at the left posterior cruris for six months. Physical examination revealed a painful swelling at the left proximal posterior cruris. However, there was no detected mass.

On ultrasonographic (USG) examination; posterior to tibia, inside the soleus muscle, a regular bordered mass was determined and it contained five to six minor cysts inside.

On magnetic resonance imaging (MRI), a well-defined, fusiform, 11x5.5 cm diametered cystic mass was found posterior to tibia, inside the soleus muscle. Mass had a very close relationship with fibula and posterior neurovascular structures. It also contained multiple cysts; the biggest one with a diameter of 1.5 cm (Figures 1A and 1B).

The patient was examined for primary foci with abdominal ultrasonography and thoracic computerized tomography. However, no other foci detected were detected. The case was accepted as a primary muscular hydatid disease.

The patient underwent surgery. During the operation, multiple cysts were found between the posterior tibia and soleus muscle, and they were surrounded by an abscess. The abscess was drained first, and then posterior cyst wall was totally removed. Afterwards, subtotal anterior cyst wall excision was performed following the neurovascular dissection (Figures 2A and 2B). Material was sent to Microbiology and Pathology departments for examination (Figure 2C). The cultures did not yield any bacterial growth. On pathological examination; basophilic, homogenic-colored and lamellary cuticula forming cysts that were surrounded by an inflammatory fibrous capsule was determined. The final diagnosis was *Echinococcus granulosus* infestation.

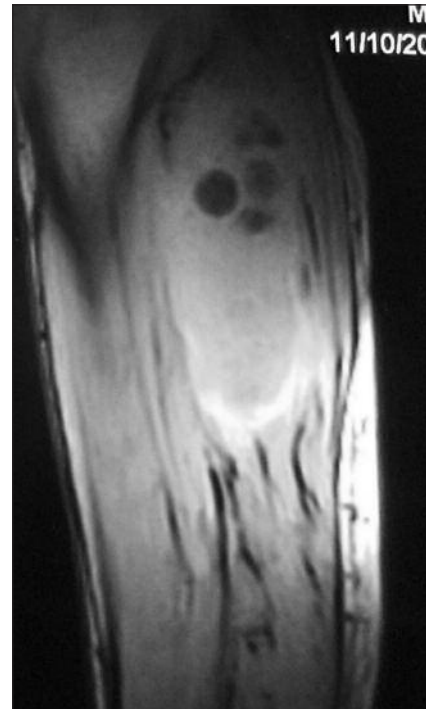


FIGURE 1A: Cysts detected with magnetic resonance imaging, sagittal image.

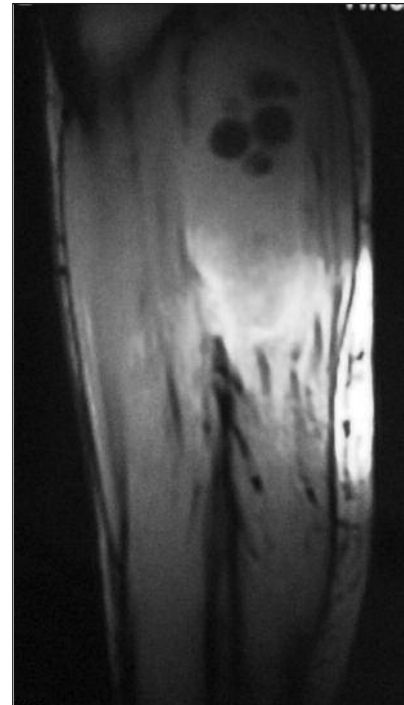


FIGURE 1B: Cysts detected with magnetic resonance imaging, sagittal image.

We administered 10 mg/kg/day albendazole after the operation.

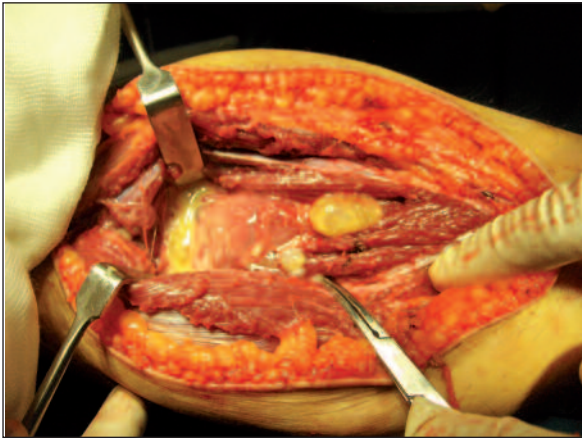


FIGURE 2A: Posterior cyst wall and a cyst.
(See for colored form <http://tipbilimleri.turkiyeklinikleri.com/>)

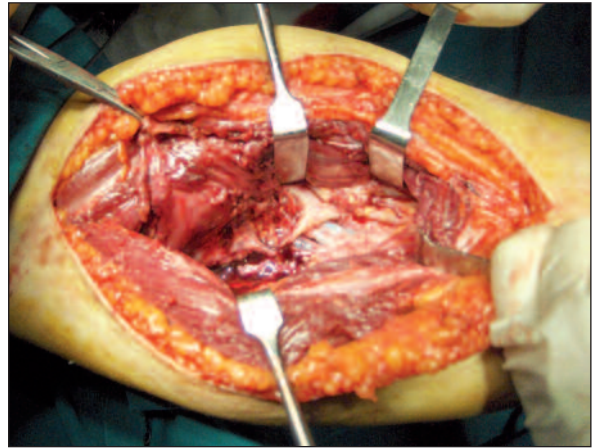


FIGURE 2B: Anterior cyst wall and its close relation with neurovascular structures.
(See for colored form <http://tipbilimleri.turkiyeklinikleri.com/>)

DISCUSSION

Hydatid disease is widespread in Southern Europe, Asia, Australia, Africa and Middle East. Definitive hosts are dogs, wolves, fox etc., and intermediate hosts are mostly sheep, goat cattle and humans. Infestations occur with ingesting viable parasitic eggs with food. After ingesting the eggs, parasites are transferred mostly to liver by portal circulation. Infestations mostly occur in the organs with an excessive blood supply.¹⁰ In humans, most common infestation site is liver followed by the lungs. Kidney, brain, soft tissue and bone involvement have also been reported.³

Possible soft tissue involvement have been discussed in review articles but muscular hydatidosis is a very rare disease.³ In muscular hydatidosis, primary foci are usually liver and lungs. For primary muscular hydatidosis, chest wall, sartorius, pectoralis major, quadriceps, supraspinatus, biceps brachii and gluteal muscles are some of the reported sites.¹¹⁻¹³ Case reports usually presented primary muscular hydatidosis determined in the gluteal and thigh muscles. It is difficult to characterize the typical presentation of soft tissue hydatidosis.

In our case, the disease presented as a mass in the deep posterior crural compartment and soleus muscle. To our knowledge, this is the first case presented at this location. In addition, the mass surrounded the posterior neurovascular structures in our

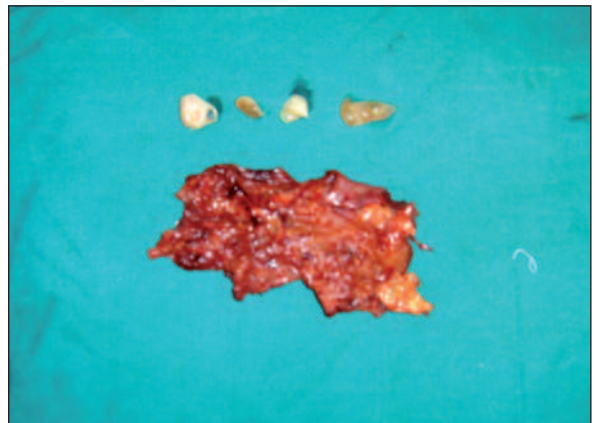


FIGURE 2C: Cyst wall and the cysts after excision.
(See for colored form <http://tipbilimleri.turkiyeklinikleri.com/>)

case, and in the literature there are no cases in whom neurovascular involvement has been reported.

In hydatid disease, diagnosis is based on radiographic examination such as USG and MRI. If surgery is performed, an experienced surgeon can recognize the cysts.⁴ However, the diagnosis is confirmed mostly by pathological examination.^{3,5}

Surgery is the best treatment method accepted for the treatment of muscular hydatidosis.^{12,13} Albendazole is also used before and after surgery for prevention of recurrence.^{3,4}

Finally, muscular hydatid disease is a rare disease that is mostly treated with combined chemotherapy and surgery. To our knowledge, our case is the first for its presentation site and its neurovascular involvement.

REFERENCES

1. Schneppenheim M, Jerosch J. Echinococcosis granulosa/cystica of the tibia. *Arch Orthop Trauma Surg* 2003;123(2-3):107-11.
2. Polat P, Kantarci M, Alper F, Suma S, Koryucu MB, Okur A. Hydatid disease from head to toe. *Radiographics* 2003;23(2):475-94.
3. Combalia A, Sastre-Solsona S. Hydatid cyst of gluteus muscle. Two cases. Review of the literature. *Joint Bone Spine* 2005;72(5):430-2.
4. Buyukbebeci O, Gulec A, Gokalp A, Karakurum G. Combined treatment of primary hydatid disease of the vastus lateralis muscle. *Orthopedics* 2004;27(6):621-2.
5. Guiral J, Rodrigo A, Tello E. Subcutaneous echinococcosis of the knee. *Lancet* 2004;363(9402):38.
6. Duygulu F, Karaoğlu S, Erdoğan N, Yıldız O. Primary hydatid cyst of the thigh: a case report of an unusual localization. *Turk J Pediatr* 2006;48(3):256-9.
7. Marwah S, Subramanian P, Marwah N, Rattan KN, Karwasra RK. Infected primary intramuscular echinococcosis of thigh. *Indian J Pediatr* 2005;72(9):799-800.
8. Koc Z, Ağildere AM, Yalcin O, Pourbagher A, Pourbagher M. Primary hydatid cyst in the anterior thigh: Sonographic findings. *J Clin Ultrasound* 2004;32(7):358-60.
9. Vicidomini S, Cancrini G, Gabrielli S, Naspetti R, Bartoloni A. Muscular cystic hydatidosis: case report. *BMC Infect Dis* 2007; 7:23.
10. Savas L, Onlen Y, Akcali C, Aslan B, Pourbagher A, Tunc T, et al. Hydatid disease with atypical localization: 4 cases report. *Scand J Infect Dis* 2004;36(8):613-5.
11. Ozkoç G, Akpınar S, Hersekli MA, Ozalay M, Tandoğan R. Primary hydatid disease of the quadriceps muscle: a rare localization. *Arch Orthop Trauma Surg* 2003;123(6):314-6.
12. Çolak MC, Kocatürk H, Çelik R, Gürsan N. [Primary hydatidosis within biceps brachii: case report]. *Turkiye Klinikleri J Med Sci* 2010; 30(1):406-9.
13. Tatarı H, Baran O, Sanlıdağ T, Göre O, Ak D, Manisali M, et al. Primary intramuscular hydatidosis of supraspinatus muscle. *Arch Orthop Trauma Surg* 2001;121(1-2):93-4.