

Surgical Management of Subperiosteal Orbital Abscess: Case Report

Subperiosteal Orbita Apselerinin Cerrahi Tedavisi

Halil Hüseyin ÇAĞATAY,^a
Metin EKİNCİ,^a
Yaran KOBAN,^a
Özlem DARAMAN,^a
Ersin OBA,^a
Sezgin KURT,^b
Mehmet KÜLEKÇİ,^b
Duygu KARA^c

Departments of
^aOphthalmology,
^bOtolaryngology,
^cRadiology,
Kafkas University Faculty of Medicine,
Kars

Geliş Tarihi/Received: 17.10.2014
Kabul Tarihi/Accepted: 28.01.2015

Yazışma Adresi/Correspondence:
Halil Hüseyin ÇAĞATAY
Kafkas University Faculty of Medicine,
Department of Ophthalmology, Kars,
TÜRKİYE/TURKEY
drhcgty@gmail.com

doi: 10.5336/ophthal.2014-42119

Copyright © 2015 by Türkiye Klinikleri

ABSTRACT Subperiosteal orbital abscess (SPOA) is a collection of purulent fluid between the periorbita and the bony orbital wall under the periosteum, which usually occurs as a complication of acute sinusitis. It usually originates from ethmoidal sinuses and is a potentially life threatening pathology. In this article, we present three cases who were treated surgically in a multi-disciplined approach, accompanied by a brief literature review. Successful results were obtained in all cases with medical treatment and external orbitotomy combined with or without transnasal endoscopic drainage.

Key Words: Orbit; orbital cellulitis; sinusitis; endoscopy

ÖZET Subperiosteal orbita apseleri (SPOA) genellikle akut sinüzit komplikasyonu olarak pürülan sıvının orbita kemik duvarında periost altında birikmesi ile meydana gelirler. Sıklıkla etmoidal sinüslerden kaynaklanırlar ve potansiyel olarak hayatı tehdit eden patolojilerdir. Bu makalede multidisipliner yaklaşımla cerrahi olarak tedavi edilmiş 3 olguya ait klinik veriler güncel literatür bilgisi ile sunulmaktadır. Tüm hastalarda medikal tedavi sonrasında uygulanan eksternal orbitotomi ile kombine olarak veya kombine edilmeden transnazal endoskopik drenaj yapılmış ve başarılı sonuçlar elde edilmiştir.

Anahtar Kelimeler: Orbit; orbital selülit; sinüzit; endoskopi

Türkiye Klinikleri J Ophthalmol 2015;24(3):202-6

Acute sinusitis is a common disorder which may cause serious orbital or intracranial complications. Subperiosteal orbital abscess (SPOA) may result from osteitic bone destruction, congenital or acquired bony defects or through the thrombophlebitis of communicating veins.^{1,2} When the infection does not penetrate the periorbit, it dissects under the periosteum and forms a SPOA of the orbit. Whereas the other sinuses may also be involved, infection mostly originates from ethmoid sinuses. Once a SPOA develops, surgical drainage is often required as well as intravenous antibiotics. In untreated or even treated cases, there is a potential risk for permanent visual loss or additional intracranial complications.³ However, transnasal endoscopic management of SPOA has gained popularity in recent years, open surgical approach is still an option in treating SPOA.⁴ In this study, we aimed to report the present clinical outcomes of surgically

treated SPOAs and discuss different methods of surgical intervention. Written informed consent forms were obtained from the patients.

CASE REPORTS

CASE 1

An 8-year-old female patient was admitted to our clinic with complaints of swelling of the left eyelids. In the ophthalmic examination, the best-corrected visual acuity (BCVA) was 1.0 on the right side and 0.2 on the left side according to the Snellen chart. Hertel exophthalmometer revealed 3 millimeters (mm) of proptosis on the left eye compared with the right eye. Diplopia and ocular pain were not detected. Normal pupillary reflexes were detected in the pupillary light reflex examination. In the 'swinging light test,' we did not detect a relative afferent pupil defect (RAPD). The left eyelids were edematous and extraocular muscle movements were limited. Fundus examinations were unremarkable in both eyes. Laboratory test findings were as follows: white blood cell (WBC) count was 12 000/mm³, the erythrocyte sedimentation rate (ESR) was 40 mm/h (normal <20 per hour) and C-reactive protein (CRP) was 60 mg/l (normal <10 mg/L). The patient was hospitalized and intravenous ampicillin sulbactam (40 mg/kg/day) and metronidazole (1000 mg/day) were administered. Monitoring of pupillary response, visual acuity, ocular motility, proptosis and systemic parameters including fever was done every four hours. Despite medical treatment, proptosis worsened upon which computed tomographic (CT) scans of the orbits and the paranasal sinus were performed. CT scans showed a SPOA on the medial wall of the left orbit and left ethmoid. On the second day of the medical treatment, RAPD occurred and a surgical intervention decision was made to proceed to surgical drainage. Functional sinus surgery combined with external orbitotomy through nasal conjunctiva were performed on the second day of the medical treatment under general anesthesia. After the periosteum of the medial orbital wall was dissected, the abscess was drained intra-operatively. Samples were collected for microbiological analysis and cultured *Staphylococcus aureus* sensitive to Beta lac-

tamase inhibitor was combined with extended spectrum penicillins. A dose of 625 mg of Amoxicillin/Clavulanate twice per day was prescribed postoperatively administered for 14 days. The patient was discharged with no complaints and recovered uneventfully (Figure 1).

CASE 2

A 13-year-old female patient was admitted to our clinic with a complaint of swelling of the right eyelids for the last three days. In the ophthalmic examination, the BCVA was 0.3 on the right side and 1.0 on the left side according to the Snellen chart. In the history of the patient, anisometropic amblyopia was detected in the right side, and in past records of the patient was at the same level of visual acuity. There were no RAPD and pupillary light reflexes abnormality or diplopia. Hertel exophthalmometry revealed 3 mm of proptosis on the right eye compared with the left eye and extra ocular

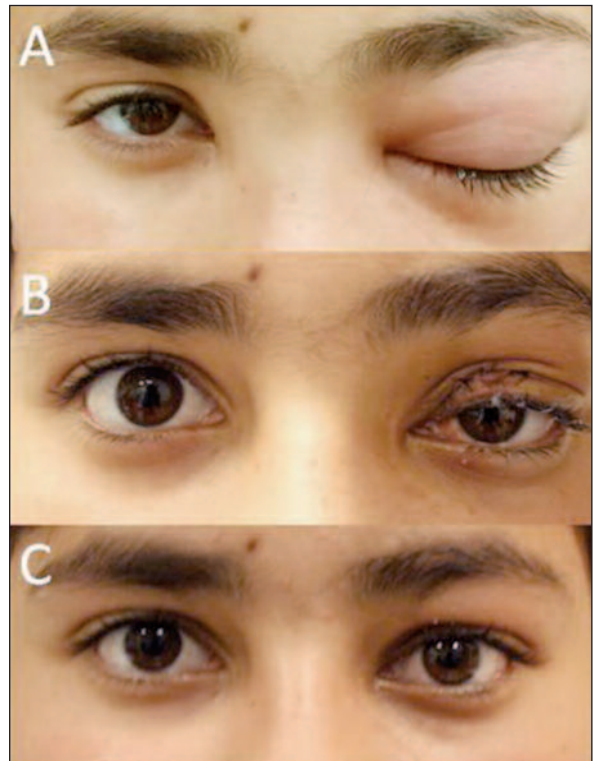


FIGURE 1: A. Preoperative photograph showing proptosis and eyelid edema and hyperemia on the left side. B. Early postoperative photograph of the patient. C. Postoperative 1st month photograph showing a complete recovery except minimal upper eyelid edema (Case 1).

movements were painful in all gazing directions. The right eyelids were edematous. Fundus examinations were unremarkable in both eyes. WBC count was 11 000/mm³, ESR was 55 mm/h (normal <20 per hour) and CRP was 9 mg/l (normal <10 mg/l). Intravenous ampicillin sulbactam (40 mg/kg/day) and metronidazole (1000 mg/day) were administered. Although proptosis regressed upon medical treatment, right extraocular movement limitation in the up gaze and ptosis of the right upper lid persisted. Surgical intervention decision was taken when magnetic resonance imaging (MRI) revealed a SPOA on the superior wall of the right orbit and right ethmoiditis, and maxillary sinusitis (Figure 2). Functional sinus surgery combined with external orbitotomy via skin crease incision were performed on the 8th day of the medical treatment under general anesthesia. After the periosteum of the superior orbital wall was dissected, the abscess was drained intra-operatively. Samples were collected for microbiological analysis but were not cultured (Figure 2). Proptosis recovered postoperatively and the patient was discharged on the third day after surgery with a prescription of oral antibiotics. A dose of 1000 mg Amoxicillin/Clavulanate twice per day was prescribed postoperatively administered for 14 days. Postoperatively, temporary ptosis developed but completely resolved in two months and no additional complications developed (Figure 3).

CASE 3

A 10-year-old female patient was admitted to our clinic with a complaint of swelling on the left eyelids. In the ophthalmic examination, BCVA was 1.0 on the right side, and 0.7 on the left side according to the Snellen chart. A pupillary light reflexes examination did not reveal a RAPD. Hertel exophthalmometer demonstrated 2 mm of proptosis in the left eye compared with the right eye and there was no complaint of diplopia. The left eyelids were edematous. Fundus examinations were unremarkable in both eyes. WBC count was 11 800/mm³, ESR was 37 mm/h and CRP was 12 mg/l. Despite intravenous ampicillin sulbactam (40 mg/kg/day) and metronidazole (1000 mg/day) treatment, prop-

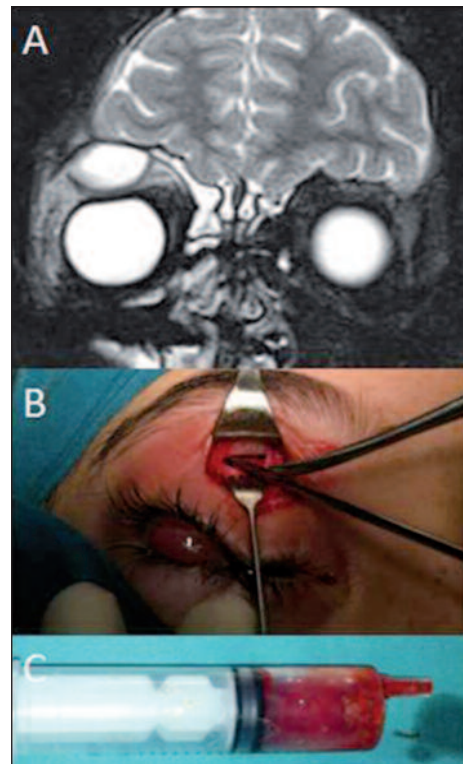


FIGURE 2: A. Coronal T2 weighted Magnetic Resonance Image shows subperiosteal hyperintense cystic lesion of orbital roof associated with focal area of mass effect and globe distortion inferiorly, confirming abscess. Adjacent ethmoid sinus is opacified with fluid intensity signal. B. Peroperatively, dissection of the periosteum and drainage of the abscess. C. Collected samples (Case 2).

tos worsened and visual impairment increased. CT scans showed a SPOA on the superior wall of the left orbit, and left ethmoiditis and maxillary sinusitis were revealed. When the clinical signs worsened, we decided to perform surgical treatment. External orbitotomy via skin crease incision was performed on the 3rd day of medical treatment under general anesthesia. Intra-operatively, after dissecting the periosteum of the superior orbital wall, the abscess was drained. Microbiological samples were collected and *Streptococcus pneumoniae* was isolated. Postoperatively, the patient recovered uneventfully and was discharged on the third day after surgery with a prescription of oral antibiotics. A dose of 625 mg Amoxicillin/Clavulanate twice per day was prescribed postoperatively administered for 14 days. Follow up examinations revealed complete recovery of the patient.

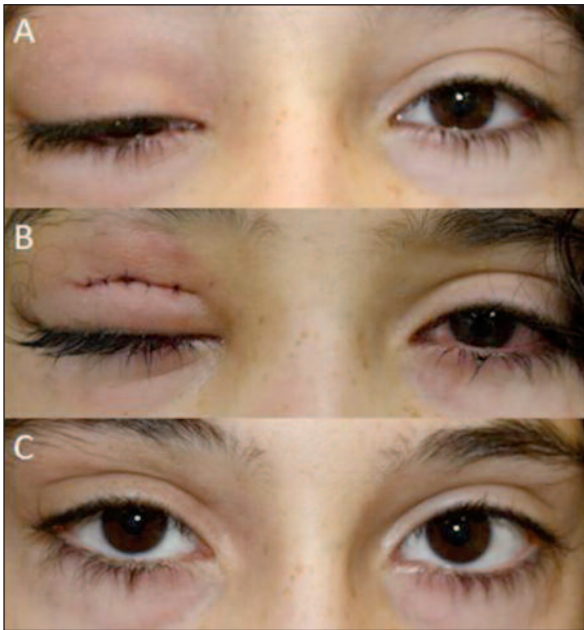

FIGURE 3: **A.** Pre-operative photograph of the patient (Case 2), with right upper eyelid ptosis and edema. **B.** One week after the abscess drainage showing the eyelid edema and persisted ptosis. **C.** All signs and symptoms resolved in the 2nd month follow up visit.

DISCUSSION

A SPOA is a collection of purulent fluid confined by the periosteal lining. Previously, it has been reported that the most common cause of SPOA is a contiguous sinusitis.⁴⁻⁶ In accordance with this knowledge, all of our cases were associated with ethmoidal sinusitis.

A SPOA may result from osteitic bone destruction, congenital or acquired bony defects, or via thrombophlebitis of communicating veins. However, any sinus infection may spread to the orbit and ethmoiditis is the most frequent origin.³ SPOA should be suspected in cases of orbital cellulitis that fails to improve by broad-spectrum intravenous antibiotics.

Patients often present eyelid edema/erythema/warmth, conjunctival injection with chemosis and restricted ocular motility with or without diplopia.³ Thorough ophthalmologic examinations must be performed serially, including evaluation for a relative afferent pupillary defect, proptosis, limitation of eye movements, increased

resistance to retropulsion, elevated intraocular pressure (IOP), decreased color vision, decreased skin sensation or an optic nerve or fundus abnormality. Restricted vision is one of the most frequent symptoms and usually occurs due to corneal astigmatism or optic neuropathy. Permanent visual loss was reported in 24-33% of the SPOA patients and usually occurs due to optic neuropathy.⁷ Non-axial displacement of the globe (as in hyper- or hypoglobus) and/or the presence of a palpable mass along the orbital rim should also be evaluated in the external examination. In the initial examination, none of the cases showed afferent pupillary defect and in all cases we revealed proptosis and limitation of eye movements. Restricted vision was a frequent symptom but it was recovered following the treatment.

In general, ophthalmologic symptoms were the most common clinical presentations of these patients. Therefore, SPOA should be considered when medical treatment of the orbital cellulitis fails.⁸ In suspected cases, radiological imaging has a critical importance in defining the SPOA. Neoplasms with inflammation such as rhabdomyosarcoma should be considered in the differential diagnosis. Contrast enhanced computed tomography has long been the preferred imaging technique for evaluating patients with acute sinusitis and suspected orbital involvement.⁷ Magnetic resonance imaging can be chosen when intracranial complications are suspected such as cavernous sinus thrombosis and intracerebral abscess.

There is no consensus regarding the optimal management of SPOAs. Some authors prefer early surgical intervention, whereas other authors recommend a trial of medical management.⁹⁻¹¹ Late diagnosis and treatment of SPOA can cause serious complications. Rapid diagnosis and surgical intervention by a collective work of ophthalmologists and otorhinolaryngologists are necessary to prevent patients from having permanent complications.

The transnasal endoscopic method has significant advantages over traditional external approaches, but it may have some limitations

especially in an acutely inflamed and bloody surgical field. A superiorly located SPOA lesion usually needs an external approach.

Traditionally, when a SPOA persists regardless of medical treatment, surgical intervention must be done in 48 hours.^{7,8,12,13} Surgical management of SPOAs may be achieved through an external approach, a transnasal endoscopic approach, or combined approaches. However, external surgical drainage has a potential risk of cosmetic complications. Previously, it has been reported that there is no significant difference in the failure rates of transnasal endoscopic, external or combined approaches.^{5,14}

In our clinic, we applied medical treatment with a combination of ampicillin and beta lactamase inhibitors with metronidazole, and performed surgical intervention when a subperiosteal developed and was resistant to medical treatment.^{15,16} We performed functional sinus surgery combined with external orbitotomy in two cases of whom the CT scans showed ethmoiditis whereas in one case, external orbitotomy was performed alone as it was superiorly located and endoscopically unapproachable.

In the literature, it is reported that early surgical intervention is essential in adolescents and adults in cases of large sized abscess, worsening vision, proptosis, restriction of ocular movements, appearance of RAPD, gases in orbit, sphenoid sinusitis infections and pansinusitis infections located near the optic nerve.^{4,9,11} In our cases, decrease of vision and proptosis were present. RAPD was not detected in initial examinations, we performed surgical intervention in patients whose signs and symptoms cannot be improved or controlled with medical treatment. Successful results were obtained in all cases owing to collective work in a multidisciplinary approach. We believe that intensive follow up and a multidisciplinary approach have critical roles in the prevention of visual loss or intracranial complications. Although further studies are needed in order to determine optimal treatment strategies for SPOA, an external approach with or without transnasal endoscopic surgical intervention is still a safe and successful treatment modality.

Acknowledgments

With thanks to Ayşe Unal Ersonmez and Suzanna Borges for editing the article in terms of English.

REFERENCES

- Brown CL, Graham SM, Griffin MC, Smith RJ, Carter KD, Nerad JA, et al. Pediatric medial subperiosteal orbital abscess: medical management where possible. *Am J Rhinol* 2004;18(5):321-7.
- Güven M, Süoğlu Y, Haşiloğlu ZI, Katircioğlu OS. [Endoscopic approach in subperiosteal orbital abscesses: case reports]. *Turkiye Klinikleri J Med Sci* 2005;25(3):455-9.
- Oxford LE, McClay J. Complications of acute sinusitis in children. *Otolaryngol Head Neck Surg* 2005;133(1):32-7.
- Yazıcı B. [Bacterial infections of the orbit]. *Turkiye Klinikleri J Ophthalmol-Special Topics* 2012;5(2):106-14.
- Tanna N, Preciado DA, Clary MS, Choi SS. Surgical treatment of subperiosteal orbital abscess. *Arch Otolaryngol Head Neck Surg* 2008;134(7):764-7.
- Pond F, Berkowitz RG. Superolateral subperiosteal orbital abscess complicating sinusitis in a child. *Int J Pediatr Otorhinolaryngol* 1999;48(3):255-8.
- Berk AT, Ayhan Z, Yaman A, Ecevit C. [Diagnosis and treatment of preseptal cellulitis in pediatric age group] *TJO* 2010;40(4):227-31.
- Baring DE, Hilmi OJ. An evidence based review of periorbital cellulitis. *Clin Otolaryngol* 2011;36(1):57-64.
- Siedek V, Kremer A, Betz CS, Tschiesner U, Berghaus A, Leunig A. Management of orbital complications due to rhinosinusitis. *Eur. Arch. Otorhinolaryngol* 2010;267(12):1881-6.
- Özcan AA, Yalaz M, Cansever ZB, Aydoğan B. [Clinical features and treatment modalities in subperiosteal abscess: case report]. *Turkiye Klinikleri J Ophthalmol* 2009;18(3):202-6.
- Şensoy G. [Orbital and preseptal cellulitis]. *Turkiye Klinikleri J Pediatr Sci* 2007;3(2):42-5.
- Kayhan FT, Sayin I, Yazici ZM, Erdur O. Management of orbital subperiosteal abscess. *J Craniofac Surg* 2010;21(4):1114-7.
- Bedwell J, Bauman NM. Management of pediatric orbital cellulitis and abscess. *Curr Opin Otolaryngol Head Neck Surg* 2011;19(6):467-73.
- Rahbar R, Robson CD, Petersen RA, DiCanzio J, Rosbe KW, McGill TJ, et al. Management of orbital subperiosteal abscess in children. *Arch Otolaryngol Neck Surg* 2001;127(3):281-6.
- Ikeda K, Oshima T, Suzuki H, Kikuchi T, Suzuki M, Kobayashi T. Surgical treatment of subperiosteal abscess of the orbit: Sendai's ten-year experience. *Auris Nasus Larynx* 2003;30(3):259-62.
- Slavin ML, Glaser JS. Acute severe irreversible visual loss with sphenothmoiditis-'posterior' orbital cellulitis. *Arch Ophthalmol* 1987;105(3):345-8.