

## Descending Necrotising Mediastinitis Due to Thinner Injection in a Suicide Attempt: Case Report

Özgür Ömer YILDIZ,<sup>a</sup>  
Ülkü YAZICI,<sup>a</sup>  
Ertan AYDIN,<sup>b</sup>  
Ömer BAYIR,<sup>c</sup>  
Nurettin KARAOĞLANOĞLU<sup>a</sup>

Clinics of

<sup>a</sup>Thoracic Surgery,

<sup>c</sup>Otorhinolaryngology,

Ankara Dışkapı Yıldırım Beyazıt Training and Research Hospital,

<sup>b</sup>Ankara Kuru Private Hospital, Ankara

Received: 15.09.2015

Accepted: 13.03.2016

Correspondence:

Özgür Ömer YILDIZ

Ankara Dışkapı Yıldırım Beyazıt Training and Research Hospital,

Clinic of Thoracic Surgery,

Ankara, TURKEY

dr.ooyildiz@gmail.com

**ABSTRACT** Descending Necrotising Mediastinitis (DNM) is a serious complication caused by infection of mediastinal organs and mediastinal connective tissues. We report a case of DNM caused by thinner injection. The case is a 23 years old woman who transferred to a health institution after injecting thinner into cervical area in a suicide attempt. Her CT scans showed air artefacts on the left side of the cervical region and mediastinal enlargement. Cervical drainage, bilateral thoracotomy were performed. In follow-up CT scans, collapse on the cervical vascular structures, widespread air artefacts in the tissues were identified. Following the CT results, the patient underwent cervical fasciotomy, right rethoracotomy.

**Key Words:** Suicide, attempted; mediastinitis

**World Clin J Med Sci 2017;1(1):47-50**

**T**hinner is a chemical substance composed of organic solvents such as toluene, benzene and xylene used to lower viscosity of paints. Toluene used in paint thinners affects the lipids of cell membrane and myelin sheath due to its lipophilicity. Intake of the aromatic hydrocarbons through inhalation or oral ingestion affects lipid of cell membrane and myelin sheath and increases growth of free radicals; and this leads to their absorption in brain, kidney and lungs and tissues of the body that contain fat.<sup>1</sup> Injection of the thinner causes cellulite and necrosis of the hydrocarbons in the injection site.<sup>2</sup>

### CASE REPORT

A 23 age-old woman was admitted to a health institution after injecting thinner into her left cervical region in a suicide attempt. While the patient was conscious when she was admitted, she was intubated due to her deteriorating condition in 24 hours. In the cervical and thoracic CT scans, bilateral air artefacts from left cervical region to paracardial region, growth of the tissues under the skin in the left cervical region, mediastinal enlargement, loculated collections and bilateral pleural effusion were identified. Urgent surgical intervention was decided and bilateral tube thoracotomy

and transcervical mediastinal drainage were performed. Irrigation catheter was inserted in the mediastinal area. Follow up chest X-ray showed that mediastinal enlargement continued as before. Through right and left mini thoracotomy mediastinal debridement, pleuromediastinal connection and irrigation were performed. Tissue samples were sent for culture and antibiogram. Intubated patient was transferred to intensive care unit. She was given total parenteral nutrition and wide spectrum antibiotics treatment. Catheter was inserted in the pretracheal area allowing a daily irrigation of 0.9% NaCl solution (2000 cc/day), and simultaneous irrigation of both chest tubes with 2000 cc/day serum physiological solution. Mediastinal and pleural debridement were done (Figure 1).

Orhinolaryngology clinic was recommended that the patient should be followed up for oedema and pressure sores. The patient received tracheostomy on the postoperative day 3 due to deterioration of her general condition and increase the pressure sores in the neck area. Following the increase of oedema and pressure sores in the face area and particularly on the left shoulder and arm area, the case was examined by the otorhinolaryngology clinic again. Thoracic and cervical CT scans showed laryngeal and tracheal deviation towards the right side, increase in the air artefacts in the cervical region, new necrosis areas and new loculations in the paratracheal and paracardial areas (Figure 2). Cervical fasciatomy, debridement, drainage and right rethoracotomy, mediastinal re-debridement were decided to be performed. In the follow up, widespread skin necrosis and superficial venous thrombosis were identified. Incision was left open and dressings were applied. Rethoracotomy was performed for the new loculations in paratracheal and paracardial areas. On the first day of the second surgery, malignant hypertension developed. Echocardiography results were normal. The patient was followed up for baroreceptor dysfunction risk. Open cervical wound was controlled with daily change of dressings. The mediastinal catheter was removed after drainage from the mediastinum into the chest tube ceased. The chest tubes were removed after drainage seized and cul-

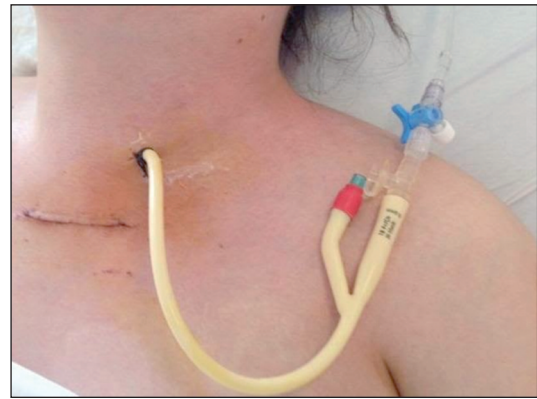

FIGURE 1: View of the catheter inserted in the pretracheal space.

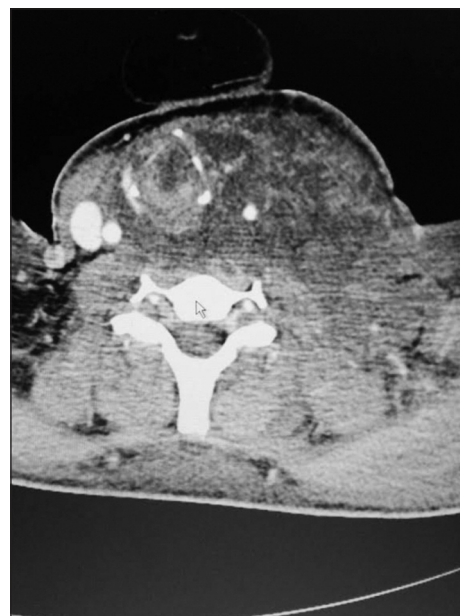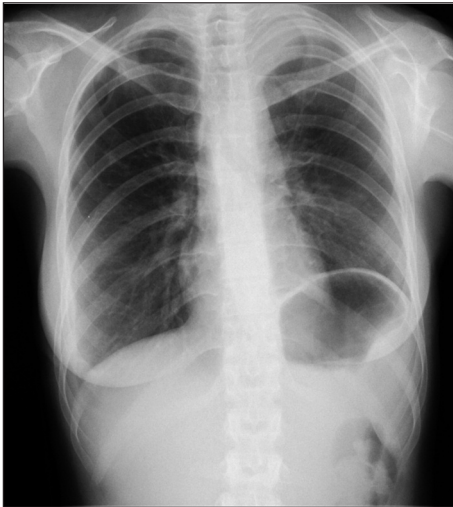


FIGURE 2: Cervical and thoracic CT scans before the operation.

ture antibiogram results were received. The patient in postoperative 18<sup>th</sup> month (Figure 3).

## COMMENT

DNM is a serious clinical complication with high mortality rates among the mediastinal infections. It often develops following infections caused by oropharyngeal, odontogenic, cervicofascial or cervical trauma. In our case, it was identified that thinner injected to the cervical region in a suicide attempt spread from the neck area to the mediastinal spaces and caused necrosis in both cervical and mediastinal spaces in the first 24 hours. The patient



**FIGURE 3:** Chest X-ray of the patient after she was discharged from the hospital.

might need intubation in a short time due to respiratory distress. Early tracheostomy might be beneficial. Our patient who also had epiglottis and vocal cord oedema underwent elective tracheostomy on the 3<sup>rd</sup> day.

Poor prognosis is a result of late diagnosis, insufficient medical treatment and lack of effective surgical drainage. The gold standard of the treatment is debridement, drainage and removal of necrotic tissues. It is argued that in DNM cases when infection is localised in the upper mediastinal region and above the tracheal bifurcation, cervical drainage would be sufficient and aggressive mediastinal drainage is not necessary. In cases when infection extends to lower mediastinum, complete mediastinal drainage is recommended.<sup>3</sup>

Following oral ingestion or inhalation of hydrocarbons such as toluene and xylene used in thinner, they are absorbed into the blood and distributed throughout the body. These are characterized particularly by uptake in wellperfused organs such as the brain, liver, lungs, and lipophilic tissues.<sup>4</sup> Pulmonary oedema and cardiac arrhythmia are determining in cases of mortality caused by high level inhalation of thinner.<sup>5</sup>

Other reported cases on parenteral intake of thinner through injection in a suicide attempt. In another case, following injection of thinner into

the pleural space, acute chemical empyema developed at the left hemithorax and it was treated with tube thoracotomy.<sup>6</sup> Likewise, in our case there was no bacterial growth according to the early culture results and antibiogram.

In another suicide attempt report thinner was injected into the right arm ante-cubital area and fasciotomy and debridement were performed.<sup>2</sup> Similarly, in our case we believe that local necrosis caused by the hydrocarbons led to widespread necrosis, changes in venous thrombosis and left ptosis, which we think, was caused by brachial plexus injury.

There are different surgical approaches including transcervical, subxiphoid approaches, median sternotomy, clamshell incision, thoracotomy, thoracoscopy (VATS). While some researchers emphasize that median sternotomy is the best approach to enable access to extensive infected areas, others do not recommend it due to the risk of sternal osteomyelitis and insufficient exposure of the posterior basal area of the left hemithorax.<sup>7</sup> Other approaches also arguing that VATS, a less invasive technique, can be a feasible and effective approach. Based on our clinical experience, we found thoracotomy is better than VATS in terms of mechanical debridement, with thoracotomy the expected complete mediastinopleural connection was established after failure with thoracoscopic surgery.

In conclusion, DNM is still a life-threatening infection and early diagnosis with appropriate treatment is crucial. As far as we are aware of, DNM caused by thinner injection has not been reported before and this case is first of its kind. We decided to perform mediastinal and intrapleural irrigation simultaneously as the essential part of the treatment. We believe that pleuromediastinal connection is an important part of the treatment enabling drainage into the pleural space through the irrigation catheter inserted in the pretracheal area from the cervical region.<sup>8</sup>

#### **Conflict of Interest**

*Authors declared no conflict of interest or financial support.*

### Authorship Contributions

**Idea/Concept: Formation of the hypothesis or the concept of the study and/or the article:** Özgür Ömer Yıldız, Nurettin Karaođlanođlu; **Design: Designing the methodology:** Özgür Ömer Yıldız, Ülkü Yazıcı, Ömer Bayır; **Monitoring/Supervision: Coordinating and supervising the study:** Ertan Aydın, Nurettin Karaođlanođlu; **Data Collection and/or Processing: Follow up of the patients, collection of biological materials,**

**classification and reporting of the data and conducting the experiments:** Özgür Ömer Yıldız, Ülkü Yazıcı, Ertan Aydın, Ömer Bayır; **Analysis and/or Commentary: Analysis of the results:** Özgür Ömer Yıldız, Ülkü Yazıcı, Ertan Aydın, Ömer Bayır; **Literature Review: Conducting literature review:** Özgür Ömer Yıldız, Ömer Bayır; **Writing of the article: Writing substantial parts of whole of the article:** Özgür Ömer Yıldız, Ülkü Yazıcı, Ertan Aydın, Ömer Bayır, Nurettin Karaođlanođlu.

## REFERENCES

1. Karatas F, Tug T, Konar V. [Serum antioxidant vitamins (A, E, C), selenium and melondi-aldehyde levels in workers exposed to aerosol]. *Toraks Derneđi* 2008;9(1):13-6.
2. Guz H, Doganay Z, Ozkan A, Colak E, Akbas H. Un unusual suicide attempt: intramuscular thinner injection. *JCEM* 2003;20(3):144-7.
3. Hasegawa T, Endo S, Sohara Y. Classification of descending necrotizing mediastinitis. *Ann Thorac Surg* 2000;69(4):1296.
4. Leikin JB. Substance-related disorders in adults. *Dis Mon* 2007;53(6):313-35.
5. Argo A, Bongiorno D, Bonifacio A, Pernice V, Liotta R, Indelicato S, et al. A fatal case of a paint thinner ingestion: comparison between toxicological and histological findings. *Am J Forensic Med Pathol* 2010;31(2):186-91.
6. Solak I, Cankayali I, Aksu H, Moral AR. An interesting thinner intoxication case: intrathoracic injection. *Adv Ther* 2006;23(3):502-5.
7. Gorlitzer M, Grabenwoeger M, Meinhart J, Swoboda H, Oczeni W, Fiegl N, et al. Descending necrotizing mediastinitis treated with rapid sternotomy followed by vacuum-assisted therapy. *Ann Thorac Surg* 2007;83(2):393-6.
8. Yazici U, Aydın E, Çelik A, Ozkan S, Karaoglanoglu N. Mediastinal Irrigation in the Treatment of Descending Necrotizing Mediastinitis. *J Clin Anal Med* 2015;6(3):389-92.