

# Modulation of Wound Healing Process in Glaucoma Filtration Surgery: Review

## Glokom Filtrasyon Cerrahisinde Yara İyileşmesi Sürecinin Düzenlenmesi

Mete GÜLER,<sup>a</sup>  
Burak BİLGIN<sup>b</sup>

<sup>a</sup>Department of Ophthalmology,  
Adiyaman University Faculty of Medicine,

<sup>b</sup>Department of Ophthalmology,  
Adiyaman University Training and  
Research Hospital,  
Adiyaman

Geliş Tarihi/Received: 09.11.2012  
Kabul Tarihi/Accepted: 21.03.2013

Yazışma Adresi/Correspondence:

Mete GÜLER

Adiyaman University Faculty of Medicine,  
Department of Ophthalmology, Adiyaman,  
TÜRKİYE/TURKEY

E-mail: meteglr@yahoo.com

**ABSTRACT** Despite the definition and the management of glaucoma have changed substantially over the past thirty years, intraocular pressure reduction remains the mainstay of glaucoma therapy. Filtration surgery is currently the best strategy for achieving target intraocular pressure and preserving visual function. In contrast to many other types of surgeries in which complete healing of tissue with restoration of normal architecture would be a desirable outcome, glaucoma surgery seeks to achieve incomplete healing that allows aqueous humor out flow. Wound healing process after glaucoma filtration surgery depends on a wide variety of clinical, physiologic, surgical, and pharmacologic factors that may affect surgical success. Several surgical and pharmacologic techniques have been introduced to enhance success of filtration surgery. Use of wound healing modifying agents as 5-fluorouracil and mitomycin C has significantly enhanced the outcomes of glaucoma surgery but they may be associated with significant sight-threatening complications. Recent developments in molecular and cell biology have greatly enhanced our understanding of the wound healing process and provided new approaches for designing scar preventing treatments. These new treatments may offer more specific, safer and local effects for modulation of the scarring response. In this review some of the old and new agents and the methods which have been used on the modulation of wound healing process in glaucoma filtration surgery are discussed.

**Key Words:** Glaucoma; filtering surgery; wound healing

**ÖZET** Glokomun tanımı ve yönetiminin son otuz yılda önemli ölçüde değişmesine rağmen intraoküler basınç düşürülmesi halen glokom tedavisinin temelini oluşturmaktadır. Filtrasyon cerrahisi günümüzde hedef basınca ulaşmada ve görsel fonksiyonu korumada en iyi stratejidir. Normal doku mimarisinin korunarak tam iyileşmenin istendiği diğer birçok cerrahinin aksine, glokom cerrahisinde aköz hümanın dışı akımına izin verecek, tam olmayan bir iyileşme hedeflenir. Glokom filtrasyon cerrahisi sonrasında yara iyileşmesi süreci, cerrahi başarıyı etkileyebilen çok çeşitli klinik, fizyolojik, cerrahi ve farmakolojik faktörlere bağlıdır. Filtrasyon cerrahisinin başarısını arttırmak için çeşitli cerrahi ve farmakolojik teknikler ileri sürülmüştür. 5- fluorourasil ve mitomisin C gibi yara iyileşmesini düzenleyici ajanların kullanımı glokom cerrahisinin sonuçlarını anlamlı ölçüde iyileştirmiş olsa da bunlar görmeyi tehdit eden ciddi komplikasyonlarla ilişkili olabilirler. Moleküller ve hücrel biyolojideki güncel gelişmeler yara iyileşmesi sürecini anlamamızı önemli ölçüde arttırmış ve skar oluşumunu engelleyici tedaviler için yeni yaklaşımlar sunmuştur. Bu yeni tedaviler skar cevabının düzenlenmesi için daha özgün, güvenli ve bölgesel etkiler sağlayabilirler. Bu derlemede glokom filtrasyon cerrahisinde yara iyileşmesi sürecinin düzenlenmesinde kullanılan bazı eski ve yeni ajanlar ve yöntemler tartışılmaktadır.

**Anahtar Kelimeler:** Glokom; filtrasyon cerrahisi; yara iyileşmesi

**Türkiye Klinikleri J Ophthalmol 2013;22(2):107-20**

Despite the definition and the management of glaucoma have changed substantially over the past three decades, intraocular pressure (IOP) reduction remains the mainstay of glaucoma therapy.

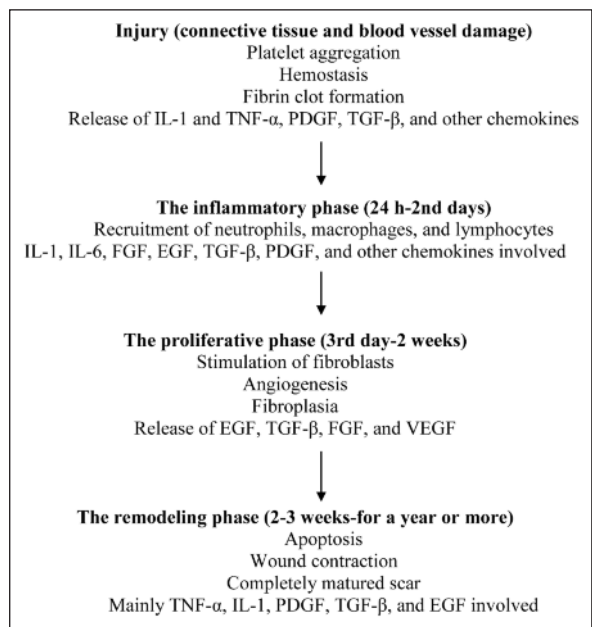
Currently available treatment modalities applied in a stepwise process initially include topical drug therapy (first single then multidrug combinations), followed by laser and finally surgical treatment.<sup>1</sup> Surgical intervention is mandatory in cases in which progression of glaucomatous optic neuropathy is documented despite maximum tolerated medical therapy or in cases which patient compliance is poor.<sup>2</sup> Surgical intervention is also preferred if local therapy is urgently needed but not tolerated because of systemic or local side effects, or regular use of eye drops is not possible because of patient's social and physical situation.<sup>3</sup> Filtration surgery is currently the best strategy for achieving target intraocular pressure and preserving visual function.<sup>4</sup> In contrast to many other types of surgeries in which complete healing of tissue with restoration of normal architecture would be a desirable outcome, glaucoma surgery seeks to achieve incomplete healing allows aqueous humor out flow. Recent developments in molecular and cell biology have greatly enhanced our understanding of the wound healing process and provided new approaches for designing anti-scarring regimens.<sup>5</sup>

This article discusses the main titles of the wound healing process and reviews some of the old and new agents and the methods which have been used on the modulation of wound healing process in glaucoma filtration surgery (GFS).

## CONJUNCTIVAL WOUND HEALING PROCESS

Conjunctiva shares many features of repair with skin. Wound healing is a complex and dynamic process which may be simplified in three phases; inflammatory, proliferative and remodelling.<sup>6</sup> Main stages of wound healing process in conjunctiva are summarized in Figure 1.

Injury (e.g. surgical conjunctival incisions) results in both connective tissue and blood vessel damage. Disruption of the epidermal barrier results with the release of prestored interleukin-1 (IL-1) and tumor necrosis factor- $\alpha$  (TNF- $\alpha$ ).<sup>7</sup> Platelets are the first responders, initiating hemo-



**FIGURE 1:** Main stages of wound healing process in conjunctiva. (Adapted from: Cordeiro MF, Chang L, Lim KS, Daniels JT, Pleass RD, Sirkwardena D, Khaw PT. Modulating conjunctival wound healing. *Eye (Lond)*. 2000; 14: 536-547).

stasis through fibrin clot formation. The resulting clot induces hemostasis and provides a matrix for the influx of inflammatory cells. Platelets also secrete growth factors such as: epidermal growth factor (EGF), platelet-derived growth factor (PDGF), transforming growth factor- $\beta$  (TGF- $\beta$ ) and several chemokines. These substances promote recruitment of inflammatory leukocytes to the site of injury.<sup>8</sup>

**Inflammatory phase** begins with the recruitment of neutrophils, macrophages, and lymphocytes.<sup>8</sup> First inflammatory cells recruited are neutrophils. They infiltrate massively into the wound during the first 24h post injury and attracted by the numerous inflammatory cytokines produced by the activated platelets, endothelial cells, as well as by the degradation products of pathogens. Neutrophils enter apoptosis soon after infiltrating the wound. Release of cytokines during this apoptotic process is an important component in macrophage recruitment. Macrophages infiltrate into the wound massively in 2 days post injury and exacerbate an intense phagocytic activity in this stage.<sup>9</sup> Macrophages play important roles in aug-

menting the inflammatory response and tissue debridement. Macrophages also initiate the development of granulation tissue and release a variety of proinflammatory cytokines (IL-1 and IL-6) and growth factors (fibroblast growth factor [FGF], EGF, TGF- $\beta$ , and PDGF).<sup>7</sup>

**Proliferative phase** starts on the third day of wound healing and lasts for about 2 weeks. In this phase of healing, cellular activity predominates. The major events during this phase are creation of a permeable barrier (ie, reepithelialization), establishment of appropriate blood supply (ie, angiogenesis), and reinforcement of the injured tissue (ie, fibroplasia).<sup>10</sup> Within hours of injury, release of EGF, TGF- $\beta$ , and FGF stimulate epithelial cell migration and proliferation, resulting in the initiation of reepithelialization. Activated macrophages release PDGF, TGF- $\beta$ 1, and FGF that stimulate fibroblasts to proliferate and migrate into the wound space. Fibroblasts produce a new extracellular matrix (ECM) required for cell growth.<sup>11</sup> Neovascularization is essential for the synthesis, deposition and organization of a new ECM. During this complex process, endothelial cells proliferate and migrate through the extracellular matrix to form capillary buds. The main stimuli for the endothelial cell proliferation are the release of FGF and vascular endothelial growth factor (VEGF) by macrophages and damaged endothelial cells.<sup>12</sup>

**Remodelling phase** begins 2-3 weeks after injury and lasts for a year or more. Wound contraction that has already begun in the proliferative phase extends. During this stage, all of the processes activated after injury wind down and cease. Most of the endothelial cells, macrophages and fibroblasts undergo apoptosis (that is, programmed cell death) or exit from the wound, leaving a mass that contains few cells and consists of mostly collagen and other extracellular-matrix proteins.<sup>13</sup> The final result is a completely matured scar with a decreased number of cells and blood vessels and increased tensile strength. The main cytokines involved in this phase are TNF- $\alpha$ , IL-1, PDGF and TGF- $\beta$  produced by fibroblasts. In addition to these, there are other cytokines produced by epithelial cells such as EGF and TGF- $\beta$ .<sup>12</sup>

## MODULATION OF WOUND HEALING PROCESS IN TRABECULECTOMY

### SURGICAL TECHNIQUE

Care should be taken to decrease tissue trauma in all steps of GFS. Meticulous hemostasis is essential in minimizing the number of inflammatory cells in the surgical field. This may be achieved by not cutting the large vessels, especially the anterior ciliary arteries and adequate cautery without excessive tissue contraction.<sup>4</sup> Gentle tissue handling is essential. Smooth or blunt-tipped forceps should be used to grasp the Tenon capsule while avoiding direct instrument contact with conjunctiva. Suture material should be carefully selected to minimize tissue reaction. Closure of the scleral flap can be performed using 10-0 nylon on a spatula cutting needle. When a limbus-based conjunctival flap is used, closure of the Tenon capsule and conjunctiva, preferably in separate layers, can be accomplished using 8-0 polyglactin on a fine, tapered-tip needle.<sup>14</sup>

### CORTICOSTEROIDS

Corticosteroids reduce and regulate wound healing through inhibition of macrophage functions such as phagocytosis and release of enzymes like collagenase, plasminogen activator, and growth factors and thus suppress inflammation. In the regeneration phase, corticosteroids inhibit conversion of membrane phospholipids to arachidonic acids, which act as chemotactic factors. Corticosteroids also inhibit vascular permeability and fibroblast proliferation.<sup>15</sup> Starita and colleagues demonstrated topical, postoperative administration of corticosteroids to be clearly effective in improving the success rates of GFS.<sup>16</sup> Subsequently they reported improved long-term outcomes (5-year and 10-year follow-up) in those eyes that had received corticosteroids after GFS.<sup>17,18</sup> In another study trabeculectomy with intraoperative sub-Tenon injection of triamcinolone acetonide for the treatment of secondary glaucoma neither increased the intermediate-term success rate nor decreased postoperative complications of trabeculectomy. Intraoperative sub-Tenon injection of triamcinolone acetonide was associated with a fewer number of

laser suture lysis.<sup>19</sup> Additional studies are needed to demonstrate optimal dose and duration of corticosteroid use following trabeculectomy.

### NONSTEROIDAL ANTI-INFLAMMATORY AGENTS

Nonsteroidal anti-inflammatory drugs are a heterogeneous group of agents that inhibit the enzyme cyclooxygenase from converting arachidonic acid into prostaglandins and thromboxanes. Prostaglandins are biologically active lipids with a diverse spectrum of activity and have been demonstrated to be potent mediators of ocular inflammation.<sup>15</sup> Topical ketorolac or fluorometholone use for one month before surgery was found to be associated with improved trabeculectomy outcomes. In the fluorometholone group, there was a significantly reduced need for additional postoperative IOP-lowering medication compared with the ketorolac group.<sup>20</sup> Kent and coworkers evaluated the efficacy and safety of diclofenac 0.1% versus prednisolone acetate 1% following trabeculectomy with adjunctive mitomycin-C. They found similar intraocular pressure results when either diclofenac or prednisolone acetate was prescribed postoperatively for intraocular inflammation.<sup>21</sup> In a rabbit model of GFS, the postoperative anti-inflammatory effects of diclofenac were demonstrated to be similar to those of prednisolone acetate.<sup>22</sup>

### MITOMYCIN C AND 5- FLUOROURACIL

Use of wound healing modifying agents as 5- fluorouracil (5-FU) and mitomycin C (MMC) has significantly enhanced the outcomes of glaucoma surgery.<sup>23</sup>

5-FU is a halogenated pyrimidine analog, and acts as a competitive inhibitor of thymidylate synthetase. It becomes incorporated into DNA and RNA within actively replicating cells, leading on to defective protein synthesis, and thus interfering with the cell growth cycle.<sup>24</sup> Subconjunctival injections of 5-FU may be administered in an undiluted concentration (50 mg/mL). The injection is usually given 90° to 180° from the trabeculectomy site. Intraoperative application of 5-FU is carried out with an amputated tip of a methylcellulose sponge soaked in a 50 mg/mL solution of 5-FU

which placed between the conjunctiva/Tenon capsule and episclera for 5 minutes.<sup>14</sup>

Mitomycin C is an alkylating agent, which cross-links DNA and inhibits the synthesis of protein and DNA, as well as inhibits mitosis. It is effective for increasing the success of glaucoma surgery through its inhibition of the proliferative phase of the wound-healing pathway. Mitomycin-C functionally inhibits and kills Tenon fibroblasts, providing a potent inhibitory effect on the scarring response and also has potent antiangiogenic properties.<sup>25</sup> MMC is approximately 100 times more potent than 5-FU (Comparison of intraoperative topical application doses of 5-FU and mitomycin C which are 50 mg/cc for 5-FU and 0.5 mg/cc for MMC).<sup>15</sup> Application of intraoperative subconjunctival MMC in trabeculectomy is similar to that described earlier for 5-FU. Clinical protocols vary with concentrations from 0.2 to 0.5 mg/mL and exposure times from 1.0 to 5.0 minutes, depending on the specific clinical situation and discretion of the surgeon.<sup>14</sup>

Application of MMC or 5-FU in glaucoma filtration surgery is sometimes associated with serious adverse effects including loss of corneal endothelial cells, cataract formation, bleb leaking, scleral necrosis and melting, iritis, hypotonous maculopathy, blebitis and endophthalmitis.<sup>26,27</sup> As a result of its biological potency with prolonged cytological toxicity occurring following its application, MMC is associated with development of potentially severe side effects and complications as compared to 5-FU.<sup>15</sup> Since the toxic effects of MMC and 5-FU have been serious, more selective and less toxic agents have been investigated to suppress the wound-healing process in GFS.

### CYCLOSPORIN-A AND TACROLIMUS

Cyclosporin-A and tacrolimus are both potent immunosuppressive drugs commonly used for reducing the incidence and severity of allograft rejection after organ transplantation. Cyclosporine and Tacrolimus share the same pharmacodynamic property of activated T-cell suppression via inhibition of calcineurin. Inhibition of calcineurin impedes calcium-dependent signal transduction, and

inactivates transcription factors (NF-AT) that promote cytokine gene activation, because they are direct or indirect substrates of calcineurin's serine-threonine phosphatase activity. As a consequence, the transcription of cytokines IL-2, IL-3, IL-4, IL-5, interferon- $\gamma$ , TNF- $\alpha$ , and granulocyte-macrophage colony-stimulating factor are suppressed. Tacrolimus is 50 to 100 times more potent than cyclosporin-A.<sup>28</sup> Topical cyclosporine has been demonstrated to be safe and effective for using as an antimetabolite in trabeculectomy.<sup>29</sup> In other studies it was found that intraoperative or postoperative treatment with cyclosporin is not associated with a decrease in intraocular pressure or prolonged bleb survival but it improves subjective ocular surface symptoms.<sup>30,31</sup>

### OCTREOTIDE

Octreotide is a synthetic octapeptide analog of endogenous somatostatin with more potency and longer half-life and has both antisecretory and antiproliferative properties.<sup>32</sup> In our study, topically administration of tacrolimus and octreotide effectively reduced the subconjunctival scarring response 2 weeks after experimental glaucoma filtration surgery. We did not see any corneal and conjunctival toxicity in histologic prepares.<sup>33</sup>

### SIROLIMUS

Sirolimus, also known as rapamycin is a macrolide currently used as an immunomodulatory medication, an anti-tumor agent, or an anti-viral agent, featuring low toxicity and high efficiency. It prevents activation of T cells and B-cells by inhibiting their response to interleukin-2.<sup>34,35</sup> Sirolimus sustained delivery film safely and effectively inhibited inflammation and fibroblast proliferation in rabbit eyes during GFS.<sup>36</sup>

### MYCOPHENOLATE-MOFETIL

Mycophenolate-mofetil (MMF), an immunosuppressive drug, is used to prevent graft rejection after kidney and liver transplantation. It is a reversible inhibitor of inosine monophosphate dehydrogenase. This is the rate-limiting enzyme in de novo synthesis of guanosine nucleotides. T- and B-lymphocytes are more dependent on this pathway than

other cell types.<sup>37</sup> Mycophenolate-mofetil had a concentration-dependent antiproliferative effect on human tenon fibroblasts in cell culture without any detected cytotoxicity.<sup>38</sup>

### ANTI VEGF AGENTS

Vascular endothelial growth factor (VEGF) not only has a role in angiogenesis, but also has a direct effect on fibroblast activity that may be modified directly at the time of filtration surgery. Elevated VEGF levels are found in the aqueous of patients with glaucoma who need trabeculectomy. In these patients, VEGF levels are increased to a higher level after surgery. The evidence shows that both preexisting VEGF in aqueous and postoperative elevation of VEGF can be suppressed by either a combination of subconjunctival and intracameral injections of anti-VEGF agents or by a single intravitreal injection.<sup>39</sup> Nilforushan and coworkers found that adjunctive subconjunctival bevacizumab with trabeculectomy is effective in controlling the IOP profile; however, its effect is less prominent than that of MMC. They injected 2.5 mg (0.1 mL) bevacizumab (Avastin) at the site of the scleral flap using a 30-gauge needle after suturing the conjunctiva. The site of the needle entrance was at least 8 mm away from the site of injection to prevent any leakage.<sup>40</sup> Sedghipour and associates reported that low dose (0.2 mg) subconjunctival bevacizumab is not found to affect the trend in intraocular pressure more than placebo after trabeculectomy for open-angle glaucoma.<sup>41</sup> In another study trabeculectomy was performed either with an adjuvant 5% solution of 5-fluorouracil applied for 4 minutes intraoperatively or with 1.25 mg of bevacizumab injected subconjunctivally just before and after the surgery and repeated 1st and 7th days after surgery. The 12-month intraocular pressure results showed no significant difference between the two groups of patients. However, to obtain successful intraocular pressure control, more patients in bevacizumab group needed medical anti-glaucomatous treatment.<sup>42</sup> In another study, bevacizumab in combination with 5-FU resulted in a greater antifibrotic effect compared with monotherapy with 5-FU or bevacizumab alone and



prolonged bleb survival.<sup>43</sup> Kahook reported that combination of intravitreal ranibizumab and topical MMC at the time of trabeculectomy resulted with more diffuse blebs and less vascularity when compared to use of topical MMC alone.<sup>44</sup> Prospective multicenter studies are still lacking for these pharmacotherapies and studies will be needed to better outline proper treatment regimens, most appropriate route of delivery, and optimum dose for each anti-VEGF agents.<sup>39</sup>

### BETA RADIATION

Constable et al. reported that growth inhibiting doses of beta radiation did not inhibit fibroblast migration or contraction in tissue culture. It did not significantly affect cellular migration or contraction, but ECM production was altered. Fibronectin production was inhibited following higher radiation doses, and collagen type I and III production were increased after 1000 cGy of beta radiation.<sup>45</sup> Beta radiation-augmented trabeculectomy reduces the risk of surgical failure compared to standard trabeculectomy. It may be clinically useful but the comparison of both its effectiveness and safety with other more widely used antimetabolites is not known. Data on its adverse effects are limited. The specific role of beta radiation is still unclear and this depends on there being more evidence available to guide practice.<sup>46</sup>

### DECORIN

Decorin is a small proteoglycan consists of a single glycosaminoglycan side chain linked to a core protein. Decorin exerts an antiproliferative effect, either directly by upregulating cyclin-dependent kinase or through its ability to interact with growth factors. Decorin binds to the potent wound-healing factor TGF- $\beta$  and inhibits its biological activity in a number of cell types.<sup>47</sup> A pilot study demonstrated that locally applied decorin improves GFS results in a rabbit model.<sup>48</sup>

### PACLITAXEL

Paclitaxel is used successfully in the treatment of malignant solid tumors such as ovarian and breast cancer as well as non small cell lung cancer. Paclitaxel binds to and stabilizes microtubules of the mi-

totic spindle, and thereby inhibits cell division.<sup>49</sup> Paclitaxel dose-dependently inhibited both proliferation and migration of the human Tenon's fibroblasts and reduced collagen production in the cell culture medium.<sup>50</sup> Paclitaxel has been demonstrated to provide MMC-like antifibrotic effects during conjunctival wound healing in the rabbit eyes.<sup>51</sup>

### PIRFENIDONE

Pirfenidone is a pyridone derivative which has anti-fibrotic and anti-inflammatory effects. It exerts its down regulating effects on a series of cytokines, including TGF- $\beta$ , connective tissue growth factor, PDGF, and TNF- $\alpha$ .<sup>52</sup> It has previously shown that pirfenidone can prevent proliferation, migration and collagen contraction of human Tenon's fibroblasts in vitro.<sup>53</sup> Postoperative use of pirfenidone 0.5% eye drops reduced the wound-healing response in surgical sites and associated with improved trabeculectomy bleb survival in a rabbit model of GFS.<sup>54</sup>

### SURAMIN

Suramin was originally synthesized and designed as an antiparasitic drug. Suramin is a heparin analogue; it binds to heparin binding proteins. The substance blocks the effects of growth factors and interferes with the action of growth factors by competitive binding to growth factor receptors. Growth factors inhibited by suramin are, TGF- $\alpha$ , PDGF, EGF, FGF, and insulin-like growth factor. Therefore, cytokines that have important roles on the stimulation of fibroblasts in wound healing process are affected.<sup>55</sup> In an animal model it was shown that suramin is highly effective in preventing scarring following filtering procedures for glaucoma.<sup>56</sup> In a clinical study suramin was compared with MMC in advanced stages of complicated glaucoma patients. The use of suramin was associated with fewer cases of severe hypotony, choroidal detachment, and severe visual loss as compared to MMC, while the success rates were similar.<sup>57</sup>

### TRANILAST

Tranilast is a derivative of anthranilic acid and has been used as an antiallergic drug for 20 years.

Along with the antiallergic action that inhibits the release of chemical mediators such as histamine and leukotriene. This drug reduces the release of cytokines such as interleukin and TGF- $\beta$ 1 and inhibits collagen synthesis.<sup>58</sup> Chihara and coworkers investigated the effects of topical instillation of tranilast 0.5% eye drops on intraocular pressure (IOP) and bleb formation after GFS in a prospective, randomized, double-masked, and controlled clinical trial. The patients were randomly assigned to receive either tranilast 0.5% eye drops or vehicle saline solution 4 times daily for 3 months after trabeculectomy. The bleb sizes were significantly larger at 6 and 12 months, and reduction of the IOP was more significant for 2 years postoperatively in tranilast-treated eyes than control eyes. No vision-threatening side reactions were associated with tranilast.<sup>59</sup> In a pilot study Spitzer and associates performed GFS on chinchilla rabbits, similar to that in clinical practice. They used UV-cross-linked hyaluronic acid as a release-system for tranilast. They finally suggested that the intraoperative application of UV-crossed linked hyaluronic acid used as a slow release system for tranilast may improve the surgical outcome of GFS.<sup>60</sup>

### CHYMASE INHIBITOR

Chymase is a chymotrypsin-like serine protease contained in the secretory granules of mast cells. Previous reports demonstrated that chymase induces the accumulation of neutrophils, eosinophils and other inflammatory cells.<sup>61</sup> In a hamster model of glaucoma surgery, chymase activity and the number of chymase-positive mast cells in conjunctival tissues were significantly increased during the wound healing process.<sup>62</sup> Maruichi and colleagues evaluated the effect of dog chymase on cell proliferation of fibroblasts established from canine Tenon's capsule and the effect of a chymase inhibitor (CI) on scarring in a canine conjunctival flap model. In cultured canine Tenon's capsule fibroblasts, dog chymase significantly increased cell proliferation, and this chymase-dependent proliferation was completely suppressed by the CI. In the canine surgical model, chymase activity in placebo-treated eyes was significantly increased compared

to control eyes, while it was significantly decreased by treatment with the CI. Scores for adhesion degree in the CI-treated eyes were significantly decreased in comparison with those in placebo-treated eyes.<sup>63</sup> Effect of gelatin hydrogel (GH) containing a CI on intraocular pressure and conjunctival scarring was investigated in a canine model of glaucoma surgery. The implantation of GH maintained the IOP reduction and bleb formation for a longer duration compared with that in the control animals. The GH containing a CI prolonged the effect through the gradual release of the CI, which suppressed the cell-proliferative effect of chymase.<sup>64</sup>

### INTERFERON- $\alpha$ 2B

Interferons are cytokines that exhibit antiproliferative, antifibrotic, and antiviral effects in several cell types.<sup>65</sup> A prospective randomized study investigated the safety and potential efficacy of subconjunctival interferon- $\alpha$ 2b (IF- $\alpha$ 2b), either alone or in combination with 5-FU in reducing the risk of failure of glaucoma surgery. The results were consistent with a beneficial effect of IF- $\alpha$ 2b given either alone or in combination with 5-FU after glaucoma surgery.<sup>66</sup> Wang et al investigated the effectiveness of needle revision combined with subconjunctival injection of IF- $\alpha$ 2b in reversing early scarring of filtering blebs following trabeculectomy surgery. Twenty-five glaucoma patients (31 eyes) who presented with scarred or encapsulated filtering bleb after glaucoma surgery underwent needle revision in combination with subconjunctival injection of IF- $\alpha$ 2b and were followed for 12 months. At the 12-month follow-up visit, 18 eyes (58.1%) achieved complete success in IOP control, and 6 eyes (19.4%) had conditional success. The overall success rate for needling was thus 77.4%. Subconjunctival hemorrhage was observed in 4 eyes during the needle revision procedure. Punctate staining was found in the corneal epithelium of 2 eyes. Shallow anterior chamber (Grade I or II) was identified in 5 eyes. The authors have suggested that slit-lamp needle revision combined with subconjunctival injection of IF- $\alpha$ 2b may be efficacious in the treatment of early scarring of filtering blebs,

is easy and safe to perform, and may be considered for more widespread application.<sup>67</sup>

### ILOMASTAT

Cell migration is facilitated by the release of matrix metalloproteinases (MMPs) that proteolytically break down the surrounding ECM, thus creating a path for cell movement.<sup>68</sup> Collagen and ECM production by fibroblasts is remodeled with continuous synthesis and breakdown of the matrix. The amount of ECM turnover at the wound depends on the extent of MMP activity.<sup>69</sup> Cell-mediated collagen gel contraction *in vitro* has been shown to be inhibited by ilomastat, a broad-spectrum MMP inhibitor, without evidence of cellular toxicity.<sup>70</sup> Wong and coworkers designed a randomized, prospective, masked-observer study to determine the long-term antiscarring effect of ilomastat treatment after experimental GFS. The animals in this study were randomly allocated to one of three treatment regimens: intraoperative MMC or postoperative subconjunctival injection of 0.1 mL of 100 µM ilomastat or phosphate buffered saline as the vehicle control. Ilomastat significantly improved surgical outcome compared with vehicle ( $P < 0.0163$ ) and length of bleb survival was similar to the MMC group. The mean day of failure was 46.2 (range, 42-60) with ilomastat, 51.3 (range, 49-60) with MMC, and 16 (range, 15-21) with vehicle. IOP maintenance with ilomastat was similar to that in the MMC group. Histologically, minimal scar tissue was seen with MMC and ilomastat. MMC-treated tissue demonstrated subconjunctival hypocellularity associated with peripheral fibrosis. Ilomastat resulted in normal-appearing conjunctival morphology.<sup>71</sup>

### GENE THERAPY

**Adenovirus-mediated delivery of p27 (KIP1):** Cell cycle progression is regulated by a combination of positive and negative regulators. It is activated by a family of cyclins and cyclin-dependent kinases (CDKs). On the other hand, the CDK inhibitors (CKIs) negatively regulate progression of the cell cycle by inhibiting the activity of cyclin-CDK complexes. p27KIP1, a member of the CKI family, plays

a pivotal role in the control of cell proliferation.<sup>72</sup> A low level of p27KIP1 expression was correlated with high proliferative and migratory capacity, whereas nuclear accumulation of this CKI was associated with a quiescent and static phenotype.<sup>73</sup> Yang et al constructed a p27KIP1-expressing adenovirus (Ad-p27) vector and administered it to a rabbit model of GFS by subconjunctival injection. They used phosphate-buffered saline (PBS) and MMC as controls. Ad-p27 enhanced the surgical outcome and inhibited cell proliferation when compared with PBS. Histological analysis showed that total cell numbers were markedly reduced, and less scar tissue was observed at the surgical site in eyes treated with Ad-p27. Ad-p27 administration significantly improved the outcome of filtration surgery and inhibited postoperative proliferation in rabbit eyes.<sup>74</sup>

**p21 WAF-1/cip-1 gene transfer:** This transgene product normally blocks entry of dividing cells into S phase of the cell cycle by antagonizing the activity of several cyclin-dependent kinases.<sup>75,76</sup> Heatley and coworkers used a recombinant adenovirus (rAd) to introduce the human gene for p21 WAF-1/cip-1 (p21) into monkey eyes in a hypertensive model of glaucoma surgery. Eyes treated with p21 exhibited open surgical ostomies by both functional and histological criteria, and did not display any side effects seen in control animals that were treated with MMC.<sup>77</sup>

**RAD50 gene therapy:** hRAD50 has been found to have antitumor activity. The mechanism of hRAD50's antitumor activity is unknown, but it appears to involve a reduction of angiogenesis through the activity of NO as well as p21-caspase-dependent direct cytotoxic action.<sup>78</sup> Over expressed hRAD50 has an antiproliferation activity *in vitro* and *in vivo* in a p21-dependent manner.<sup>79</sup> Antiproliferative effect of the subconjunctival injection of human RAD50 (hRAD50) on fibroblasts in GFS was investigated in rabbit eyes. The subconjunctival injection of hRAD50 was performed after GFS. Morphologic changes in the subconjunctival area of hRAD50-treated eyes were compared with those of MMC-treated and control eyes using light and electron microscopy. Histologic antiprolifera-



tive effects of local hRAD50 on the conjunctival fibroblasts were similar to those of MMC without damaging to the basal lamina of the conjunctival epithelium. These findings suggest that injection of hRAD50 may be useful as a possible antifibroblastic agent for GFS.<sup>80</sup>

### HUMAN AMNIOTIC MEMBRANE

Human amniotic membrane, known for its antifibrotic, anti-inflammatory and anti-angiogenic properties, suppresses TGF- $\beta$  and has been tested as an adjuvant in high-risk glaucoma filtration surgery, as a substrate for the repair of leaking glaucoma blebs, and for the management of tube exposure following tube shunt surgery.<sup>81</sup> In a randomized human study subconjunctival (over the scleral flap) placement of amniotic membrane showed favorable effects on bleb survival.<sup>81</sup>

### HYALURONIC ACID FILM

Solid hyaluronic acid-carboxymethyl cellulose film which was inserted under and above the scleral flaps inhibited the formation of postoperative adhesion around the conjunctiva and sclera in an experimental study. This material functioned as a barrier to contact between separated tissues by which the postoperative formation of adhesions was reduced and delayed. Furthermore, because the film was comprised hyaluronic acid and sodium carboxymethylcellulose, no subsequent removal procedure was required, as the materials were eventually absorbed into the body.<sup>82</sup>

### BIODEGRADABLE, POROUS COLLAGEN MATRIX

Implantation of a biodegradable, porous collagen matrix in the subconjunctival space avoided early scar formation and maintained long-term IOP control by creating a loosely structured filtering bleb in rabbit eyes.<sup>83</sup>

### PHOTODYNAMIC THERAPY

Photodynamic therapy (PDT) is a minimally invasive treatment that utilizes the combination of a non-toxic dose of light-sensitive molecules, known as a photosensitizer (PS), with the application of light at a wavelength appropriate to excite the PS and tissue oxygen in order to generate tissue damage.<sup>84</sup> The re-

active oxygen intermediates produced during photoactivation of the PS may cause direct cytotoxicity or indirect effects by damaging the local vascular system within the targeted area.<sup>85</sup> Photodynamic therapy can cause regression of neovascularization and death of scleral and Tenon's fibroblasts in vitro and has shown promising results in the modulation of wound healing in GFS in both rabbits and humans.<sup>86</sup> Stasi and coworkers evaluated the safety and efficacy of postoperative verteporfin photodynamic treatment as an adjunct to experimental GFS in rabbits. The experimental group underwent i.v. injection of verteporfin and subsequent photoactivation at the operative site on postoperative day 1. Blebs in the experimental group differed from those in the control groups histologically, lacking significant collagen deposition in the area of the sclerostomy. They proposed that wound healing in glaucoma surgery may be successfully modulated postoperatively using photodynamic therapy with i.v. administered PS.<sup>86</sup> Jordan and associates combined trabeculectomy with photodynamic therapy in 42 consecutive eyes of 36 glaucoma patients. Patients received one subconjunctival injection of 80  $\mu$ g BCECF-AM (2,7-bis-(2-carboxyethyl)-5-(and-6)-carboxy-fluorescein, acetoxymethyl-ester) followed by an intraoperative illumination with blue light ( $\lambda = 450-490$  nm) for 8 minutes. With respect to the application of BCECF-AM, no tissue damage of the conjunctiva or the cornea was seen. Clinical follow up examinations did not reveal any local toxicity, uveitis, and endophthalmitis. Follow up of the filtering bleb was documented by slit lamp examination. Complete success was defined as an IOP reduction of >20% and/or an IOP constantly <21 mm Hg without the need for antiglaucomatous medication. Qualified success was defined as an IOP < 21 mm Hg under topical antiglaucomatous medication. Eyes had mean 1.1 preoperative surgical interventions (filtration and non-filtration glaucoma surgery). Mean preoperative IOP was 31.6 mm Hg. Patients were followed for mean 496 days (range 3.5-31.8 months). Of the 42 eyes, 25 eyes had an IOP decreased to 15.8 mm Hg without medication (complete success: 59.5%;  $p < 0.001$ ; t test). Seven eyes showed good IOP reduction < 21 mmHg under topical antiglaucomatous

medication (qualified success: 16.7%). 10 eyes failed because of scarring within 2-67 weeks (23.8%). They concluded that trabeculectomy with photodynamic therapy is a safe method and has a possible potential to prolong bleb survival.<sup>87</sup>

### FEMTOSECOND LASER

Owing to its ultrashort pulse duration, extremely high intensity, and high precision ablation effect, femtosecond pulsed laser is distinctly advantageous for minimally invasive surgery in ophthalmology. Although its major use at present is in the cutting of laser in situ keratomileusis flaps, the laser has proven its versatility in laser-assisted anterior and posterior lamellar keratoplasty, cutting of donor buttons in endothelial keratoplasty, customized trephination in penetrating keratoplasty, tunnel creation for intracorneal ring segments, astigmatic keratotomy, corneal biopsy, capsulotomy and lens fragmentation.<sup>88</sup> A recent experimental study compared the external sclerostomy produced using a femtosecond laser with that made by a surgical knife. 10 pigmented rabbits underwent external sclerostomy with a femtosecond laser in the right eye; 10 additional rabbits underwent sclerostomy with a surgical superblade in the right eye. The success rate of the laser-treated group was significantly higher than the knife group ( $p=0.005$ ). Histologically, the subconjunctival connective tissue was loosely arranged with partially patent sclerostomy in the laser-treated eyes at postoperative day 14. This contrasted with the completely scarred sclerostomy tract in the knife group. The mean numbers of fibroblasts and new vessels as well as the amount of new collagen deposition at bleb site were significantly decreased in the laser group ( $p=0.045$ ,  $0.013$  and  $0.036$ , respectively). This study demonstrated that external femtosecond laser sclerostomy may offer a safe and effective alternative for the minimally invasive surgical management of glaucoma.<sup>89</sup>

## MODULATION OF WOUND HEALING PROCESS IN NON-PENETRATING GLAUCOMA SURGERY

Non-penetrating glaucoma surgery (NPGS), like vitreocanalostomy and deep sclerectomy (DS) were

popularized in the 1990s as safer alternatives to trabeculectomy. Deep sclerectomy is the basic NPGS procedure.<sup>90</sup>

Deep sclerectomy with **intraoperative MMC** application (at a dose of 0.2 mg/ml for 2-3 min under the conjunctival flap) in eyes with previous failed glaucoma surgery and/or cataract extraction was reported as an effective surgical procedure.<sup>90</sup>

In DS a spacer device is often placed on the scleral bed to prevent adhesion of the scleral flap to the bed and help to form a subscleral lake and subconjunctival filtration bleb. In a clinical study, the use of a **collagen implant** in DS (the collagen implant drainage device was placed in the centre of the deep sclerectomy) enhanced the success rates and reduced the need for postoperative medication as compared to surgery without a collagen implant.<sup>91</sup> In another study on the basis of a 10-year follow-up, DS with collagen implant demonstrated its efficacy in controlling IOP with few postoperative complications.<sup>92</sup> In a clinical study rigid nonabsorbable **polymethylmethacrylate implant** offered success and complication rates equal to those of the collagen implant.<sup>93</sup> Deep sclerectomy with **reticulated hyaluronic acid implant (SkGel)** provided stable control of IOP in a retrospective clinical trial.<sup>94</sup> Studies about **autologous scleral implant** during the nonpenetrating DS operation have shown different results. Devloo and associates found no statistically significant difference between the groups with or without an autologous scleral implant.<sup>95</sup> In a prospective clinical study, the use of autologous scleral implant showed comparable results with the use of the expensive collagen implant in controlling IOP.<sup>96</sup> **T-flux** (Carl Zeiss) is a nonabsorbable hydrophilic acrylic implant has been used in DS. Deep sclerectomy combined with T-Flux implant was reported to be a relatively safe antiglaucomatic surgery with a minimum number of complications, high predictability of the results and very good long term effectivity.<sup>97</sup> Bahar et al. used **femtosecond laser** technology to perform scleral flep in NPGS in cadaver eyes. The creation of a scleral flap was achieved using a femtosecond laser technology without damage to overlying tissue in all NPDS operations.<sup>98</sup>

## MODULATION OF WOUND HEALING PROCESS IN GLAUCOMA DRAINAGE IMPLANT SURGERY

Tube-shunt procedures have shown encouraging results in the treatment of refractory glaucoma.<sup>99</sup> The major cause of their failure is excessive fibrosis. The thick vascularized fibrous capsule around the reservoir body leads to increased IOP.

In a randomized controlled clinical trial intraoperative MMC (0.5 mg/ml for 5 minutes) did not increase the short- or intermediate-term success rates of Ahmed Glaucoma Valve implantation.<sup>100</sup> Mahdy evaluated the use of bevacizumab intraoperatively versus MMC to enhance the survival of Ahmed valve in cases of pediatric glaucoma. Bevacizumab (1.25 mg in 0.05 mL) was injected around the valve body after completing the surgery and MMC (0.4 mg/mL for 3 min) was applied before valve implantation. The follow-up period was 12 months. He was reported that adjunctive use of bevacizumab or MMC during Ahmed valve implantation significantly enhances the valve survival. Bevacizumab seems to be much safer than MMC with no visually devastating complications.<sup>101</sup> Ma and coworkers applied Ahmed glaucoma valve implantation in patients with neovascular glaucoma (NVG) with or without intraoperative intravitreal bevacizumab injection. In the intraoperative intravitreal bevacizumab injection group, 1.25mg of bevacizumab was injected into the vitreous cavity during Ahmed valve implantation. In the control group, only Ahmed valve implantation was performed. Intraoperative intravitreal bevacizumab injections did not have a beneficial effect on the success of Ahmed valve implantation in NVG.<sup>102</sup> In a retrospective study, the use of MMC with Baerveldt implantation controlled IOP equivalent to that without MMC at intermediate follow-up.<sup>103</sup> Taglia and associates reported their retro-

spective study comparing the Ahmed valve, Krupin valve with disk, and the double-plated Molteno implant, all with adjunctive MMC. The success rate at 1st year was highest with the Molteno implantation; however, Ahmed valve implantation with MMC was associated with fewer complications and less vision loss than other procedures.<sup>104</sup> In an experimental study Jacob et al. showed that biodegradable plugs (collagen plugs containing 1.125 mg of 5-FU) placed within the silicone tubes of glaucoma drains can safely deliver 5-FU to filtering blebs over time, which can prolong the functional life of the bleb by decreasing the thickness of the anterior fibrous capsule and permitting sufficient fluid outflow to reduce IOP to physiological levels.<sup>105</sup> As it is seen, the findings supporting the use of antifibrotics adjunctively with glaucoma drainage devices are controversial.

## CONCLUSION

Wound healing after GFS depends on a wide variety of clinical, physiologic, surgical, and pharmacologic factors that may affect surgical success. A delicate balance is required to achieve the desired degree of healing. Although the introduction of the antiproliferative drugs MMC and 5-FU have revolutionized glaucoma surgery, they may be associated with significant sight-threatening complications. A more targeted algorithm incorporating different inhibitors and influencing separate phases of the wound healing process may improve the results. Rather than a single agent, it will probably be better to use a combination of different pharmacological agents and techniques which will ultimately secure long-term stable IOP lowering which is associated with halting glaucomatous vision loss without adverse effects. Developments in both molecular therapy and cell biology will offer safer and more specific agents (or methods) for modifying the wound-healing response after GFS.

## REFERENCES

1. McKinnon SJ, Goldberg LD, Peeples P, Wait JG, Bramley TJ. Current management of glaucoma and the need for complete therapy. *Am J Manag Care* 2008;14(1 Suppl):S20-7.
2. Sharaawy T, Bhartiya S. Surgical management of glaucoma: evolving paradigms. *Indian J Ophthalmol* 2011;59(Suppl):S123-30.
3. Dietlein TS, Hermann MM, Jordan JF. The medical and surgical treatment of glaucoma. *Dtsch Arztebl Int* 2009;106(37):597-605; quiz 606.
4. Cordeiro MF, Siriwardena D, Chang L, Khaw PT. Wound healing modulation after glaucoma surgery. *Curr Opin Ophthalmol* 2000;11(2):121-6.
5. Razeghinejad MR, Spaeth GL. A history of the surgical management of glaucoma. *Optom Vis Sci* 2011;88(1):E39-47.
6. Cordeiro MF, Chang L, Lim KS, Daniels JT, Pleass RD, Siriwardena D, et al. Modulating conjunctival wound healing. *Eye (Lond)* 2000;14 (Pt 3B):536-47.
7. Kondo T, Ishida Y. Molecular pathology of wound healing. *Forensic Sci Int* 2010;203(1-3): 93-8.
8. Nauta A, Gurtner GC, Longaker MT. Wound healing and regenerative strategies. *Oral Dis* 2011;17(6):541-59.
9. Rodero MP, Khosrotehrani K. Skin wound healing modulation by macrophages. *Int J Clin Exp Pathol* 2010;3(7):643-53.
10. Li J, Chen J, Kirsner R. Pathophysiology of acute wound healing. *Clin Dermatol* 2007;25(1):9-18.
11. Mendonça RJ, Coutinho-Netto J. Cellular aspects of wound healing. *An Bras Dermatol* 2009;84(3):257-62.
12. Tsirogianni AK, Moutsopoulos NM, Moutsopoulos HM. Wound healing: immunological aspects. *Injury* 2006;37(Suppl 1):S5-12.
13. Gurtner GC, Werner S, Barrandon Y, Longaker MT. Wound repair and regeneration. *Nature* 2008;453(7193):314-21.
14. Atreides SP, Skuta GL, Reynolds AC. Wound healing modulation in glaucoma filtering surgery. *Int Ophthalmol Clin* 2004;44(2):61-106.
15. Lama PJ, Fechtner RD. Antifibrotics and wound healing in glaucoma surgery. *Surv Ophthalmol* 2003;48(3):314-46.
16. Starita RJ, Fellman RL, Spaeth GL, Poryzees EM, Greenidge KC, Traverso CE. Short- and long-term effects of postoperative corticosteroids on trabeculectomy. *Ophthalmology* 1985;92(7):938-46.
17. Roth SM, Spaeth GL, Starita RJ, Birbillis EM, Steinmann WC. The effects of postoperative corticosteroids on trabeculectomy and the clinical course of glaucoma: five-year follow-up study. *Ophthalmic Surg* 1991;22(12):724-9.
18. Araujo SV, Spaeth GL, Roth SM, Starita RJ. A ten-year follow-up on a prospective, randomized trial of postoperative corticosteroids after trabeculectomy. *Ophthalmology* 1995;102(12):1753-9.
19. Yuki K, Shiba D, Kimura I, Ohtake Y, Tsubota K. Trabeculectomy with or without intraoperative sub-tenon injection of triamcinolone acetonide in treating secondary glaucoma. *Am J Ophthalmol* 2009;147(6):1055-60, 1060.e1-2.
20. Breusegem C, Spielberg L, Van Ginderdeuren R, Vandewalle E, Renier C, Van de Veire S, et al. Preoperative nonsteroidal anti-inflammatory drug or steroid and outcomes after trabeculectomy: a randomized controlled trial. *Ophthalmology* 2010;117(7):1324-30.
21. Kent AR, Dubiner HB, Whitaker R, Mundorf TK, Stewart JA, Cate EA, et al. The efficacy and safety of diclofenac 0.1% versus prednisolone acetate 1% following trabeculectomy with adjunctive mitomycin-C. *Ophthalmic Surg Lasers* 1998;29(7):562-9.
22. Gwin TD, Stewart WC, Gwynn DR. Filtration surgery in rabbits treated with diclofenac or prednisolone acetate. *Ophthalmic Surg* 1994;25(4):245-50.
23. Bulut S, Akgün Ü, Duman S. [Long-term effects of trabeculectomy combined with mitomycin C in high risk glaucoma]. *Türkiye Klinikleri J Ophthalmol* 1999;88(2):77-80.
24. Anand N, Khan A. Long-term outcomes of needle revision of trabeculectomy blebs with mitomycin C and 5-fluorouracil: a comparative safety and efficacy report. *J Glaucoma* 2009;18(7):513-20.
25. Wang XY, Crowston JG, Zoellner H, Healey PR. Interferon-alpha and interferon-gamma sensitize human tenon fibroblasts to mitomycin-C. *Invest Ophthalmol Vis Sci* 2007;48(8): 3655-61.
26. Coppens G, Maudgal P. Corneal complications of intraoperative Mitomycin C in glaucoma surgery. *Bull Soc Belge Ophthalmol* 2010; (314):19-23.
27. Jongsareejit B, Tomidokoro A, Mimura T, Tomita G, Shirato S, Araie M. Efficacy and complications after trabeculectomy with mitomycin C in normal-tension glaucoma. *Jpn J Ophthalmol* 2005;49(3):223-7.
28. Kapturczak MH, Meier-Kriesche HU, Kaplan B. Pharmacology of calcineurin antagonists. *Transplant Proc* 2004;36(2 Suppl):25S-32S.
29. Turaçlı ME, Gündüz K, Aktan G, Sencer H. Topical cyclosporine as a possible new antimetabolite in trabeculectomy. *Ophthalmic Surg Lasers* 1996;27(6):438-44.
30. Lattanzio FA Jr, Crouch ER Jr, Mitrev PV, Williams PB, Allen RC. Cyclosporin as an adjunct to glaucoma filtration surgery. *J Glaucoma* 2005;14(6):441-7.
31. Fakhraie G, Lopes JF, Spaeth GL, Almodin J, Ichhpujani P, Mosler MR. Effects of postoperative cyclosporine ophthalmic emulsion 0.05% (Restasis) following glaucoma surgery. *Clin Experiment Ophthalmol* 2009;37(9):842-8.
32. Verslype C, Carton S, Borbath I, Delaunoit T, Demetter P, Demolin G, et al. The antiproliferative effect of somatostatin analogs: clinical relevance in patients with neuroendocrine gastro-entero-pancreatic tumours. *Acta Gastroenterol Belg* 2009;72(1):54-8.
33. Arslan S, Aydemir O, Güler M, Dağlı AF. Modulation of postoperative scarring with tacrolimus and octreotide in experimental glaucoma filtration surgery. *Curr Eye Res* 2012;37(3): 228-33.
34. Leblanc KG Jr, Hughes MP, Sheehan DJ. The role of sirolimus in the prevention of cutaneous squamous cell carcinoma in organ transplant recipients. *Dermatol Surg* 2011;37(6): 744-9.
35. Gera J, Lichtenstein A. The mammalian target of rapamycin pathway as a therapeutic target in multiple myeloma. *Leuk Lymphoma* 2011;52(10):1857-66.
36. Yan ZC, Bai YJ, Tian Z, Hu HY, You XH, Lin JX, et al. Anti-proliferation effects of Sirolimus sustained delivery film in rabbit glaucoma filtration surgery. *Mol Vis* 2011;17:2495-506.
37. Bardsley-Elliott A, Noble S, Foster RH. Mycophenolate mofetil: a review of its use in the management of solid organ transplantation. *BioDrugs* 1999;12(5):363-410.
38. Heinz C, Hudde T, Heise K, Steuhl KP. Antiproliferative effect of mycophenolate mofetil on cultured human Tenon fibroblasts. *Graefes Arch Clin Exp Ophthalmol* 2002;240(5):408-14.
39. Mathew R, Barton K. Anti-vascular endothelial growth factor therapy in glaucoma filtration surgery. *Am J Ophthalmol* 2011;152(1):10-15.e2.
40. Nilforushan N, Yadgari M, Kish SK, Nassiri N. Subconjunctival bevacizumab versus mitomycin C adjunctive to trabeculectomy. *Am J Ophthalmol* 2012;153(2):352-357.
41. Sedghipour MR, Mostafaei A, Taghavi Y. Low-dose subconjunctival bevacizumab to augment trabeculectomy for glaucoma. *Clin Ophthalmol* 2011;5:797-800.
42. Jurkowska-Dudzińska J, Kosior-Jarecka E, Zamowski T. Comparison of the use of 5-fluorouracil and bevacizumab in primary trabeculectomy: results at 1 year. *Clin Experiment Ophthalmol* 2012;40(4):e135-42.
43. How A, Chua JL, Charlton A, Su R, Lim M,



- Kumar RS, et al. Combined treatment with bevacizumab and 5-fluorouracil attenuates the postoperative scarring response after experimental glaucoma filtration surgery. *Invest Ophthalmol Vis Sci* 2010;51(2):928-32.
44. Kahook MY. Bleb morphology and vascularity after trabeculectomy with intravitreal ranibizumab: a pilot study. *Am J Ophthalmol* 2010; 150(3):399-403.e1.
45. Constable PH, Crowston JG, Occlleston NL, Khaw PT. The effects of single doses of beta radiation on the wound healing behaviour of human Tenon's capsule fibroblasts. *Br J Ophthalmol* 2004;88(2):169-73.
46. Kirwan JF, Rennie C, Evans JR. Beta radiation for glaucoma surgery. *Cochrane Database Syst Rev* 2009;(2):CD003433.
47. Zhang Z, Li XJ, Liu Y, Zhang X, Li YY, Xu WS. Recombinant human decorin inhibits cell proliferation and downregulates TGF-beta1 production in hypertrophic scar fibroblasts. *Burns* 2007;33(5):634-41.
48. Grisanti S, Szurman P, Warga M, Kaczmarek R, Ziemssen F, Tatar O, et al. Decorin modulates wound healing in experimental glaucoma filtration surgery: a pilot study. *Invest Ophthalmol Vis Sci* 2005;46(1):191-6.
49. Spratlin J, Sawyer MB. Pharmacogenetics of paclitaxel metabolism. *Crit Rev Oncol Hematol* 2007;61(3):222-9.
50. Choritz L, Grub J, Wegner M, Pfeiffer N, Thieme H. Paclitaxel inhibits growth, migration and collagen production of human Tenon's fibroblasts--potential use in drug-eluting glaucoma drainage devices. *Graefes Arch Clin Exp Ophthalmol* 2010;248(2):197-206.
51. Koz OG, Ozhuy S, Tezel GG, Karaman N, Unlu N, Yarangumeli A, et al. The effect of paclitaxel on conjunctival wound healing: a pilot study. *J Glaucoma* 2007;16(7):610-5.
52. Dosanjh A. Pirfenidone: anti-fibrotic agent with a potential therapeutic role in the management of transplantation patients. *Eur J Pharmacol* 2006;536(3):219-22.
53. Lin X, Yu M, Wu K, Yuan H, Zhong H. Effects of pirfenidone on proliferation, migration, and collagen contraction of human Tenon's fibroblasts in vitro. *Invest Ophthalmol Vis Sci* 2009; 50(8):3763-70.
54. Zhong H, Sun G, Lin X, Wu K, Yu M. Evaluation of pirfenidone as a new postoperative anti-scarring agent in experimental glaucoma surgery. *Invest Ophthalmol Vis Sci* 2011; 52(6):3136-42.
55. Sahu D, Saroha A, Roy S, Das S, Srivastava PS, Das HR. Suramin ameliorates collagen induced arthritis. *Int Immunopharmacol* 2012; 12(1):288-93.
56. Mietz H, Chávez-Barrios P, Feldman RM, Lieberman MW. Suramin inhibits wound healing following filtering procedures for glaucoma. *Br J Ophthalmol* 1998;82(7):816-20.
57. Mietz H, Krieglstein GK. Suramin to enhance glaucoma filtering procedures: a clinical comparison with mitomycin. *Ophthalmic Surg Lasers* 2001;32(5):358-69.
58. Rogosnitzky M, Danks R, Kardash E. Therapeutic potential of tranilast, an anti-allergy drug, in proliferative disorders. *Anticancer Res* 2012;32(7):2471-8.
59. Chihara E, Dong J, Ochiai H, Hamada S. Effects of tranilast on filtering blebs: a pilot study. *J Glaucoma* 2002;11(2):127-33.
60. Spitzer MS, Sat M, Schramm C, Schnichels S, Schultheiss M, Yoeuek E, et al. Biocompatibility and antifibrotic effect of UV-cross-linked hyaluronate as a release-system for tranilast after trabeculectomy in a rabbit model--a pilot study. *Curr Eye Res* 2012; 37(6):463-70.
61. He S, Walls AF. Human mast cell chymase induces the accumulation of neutrophils, eosinophils and other inflammatory cells in vivo. *Br J Pharmacol* 1998;125(7):1491-500.
62. Sakaguchi H, Takai S, Sakaguchi M, Sugiyama T, Ishihara T, Yao Y, et al. Chymase and angiotensin converting enzyme activities in a hamster model of glaucoma filtering surgery. *Curr Eye Res* 2002;24(5):325-31.
63. Maruichi M, Takai S, Sugiyama T, Ueki M, Oku H, Sakaguchi M, et al. Role of chymase on growth of cultured canine Tenon's capsule fibroblasts and scarring in a canine conjunctival flap model. *Exp Eye Res* 2004;79(1):111-8.
64. Kojima S, Sugiyama T, Takai S, Jin D, Shibata M, Oku H, et al. Effects of gelatin hydrogel containing chymase inhibitor on scarring in a canine filtration surgery model. *Invest Ophthalmol Vis Sci* 2011;52(10):7672-80.
65. Shridharani SM, Magarakis M, Manson PN, Singh NK, Basdag B, Rosson GD. The emerging role of antineoplastic agents in the treatment of keloids and hypertrophic scars: a review. *Ann Plast Surg* 2010;64(3):355-61.
66. Gillies MC, Brooks AM, Young S, Gillies B, Simpson JM, Goldberg I. A randomized phase II trial of interferon-alpha2b versus 5-fluorouracil after trabeculectomy. *Aust N Z J Ophthalmol* 1999;27(1):37-44.
67. Wang WH, Zhang JL, Huang Y, Huang JX, Jiang JH. Clinical study on interferon treatment of early scarring in filtering bleb. *Yan Ke Xue Bao* 2011;26(4):197-200.
68. Murphy G, Gavrilovic J. Proteolysis and cell migration: creating a path? *Curr Opin Cell Biol* 1999;11(5):614-21.
69. Matrisian LM. Metalloproteinases and their inhibitors in matrix remodeling. *Trends Genet* 1990;6(4):121-5.
70. Daniels JT, Cambrey AD, Occlleston NL, Garrett Q, Tarnuzzer RW, Schultz GS, et al. Matrix metalloproteinase inhibition modulates fibroblast-mediated matrix contraction and collagen production in vitro. *Invest Ophthalmol Vis Sci* 2003;44(3):1104-10.
71. Wong TT, Mead AL, Khaw PT. Prolonged anti-scarring effects of ilomastat and MMC after experimental glaucoma filtration surgery. *Invest Ophthalmol Vis Sci* 2005;46(6):2018-22.
72. Sheaff RJ, Groudine M, Gordon M, Roberts JM, Clurman BE. Cyclin E-CDK2 is a regulator of p27Kip1. *Genes Dev* 1997;11(11):1464-78.
73. Fredersdorf S, Burns J, Milne AM, Packham G, Fallis L, Gillett CE, et al. High level expression of p27(kip1) and cyclin D1 in some human breast cancer cells: inverse correlation between the expression of p27(kip1) and degree of malignancy in human breast and colorectal cancers. *Proc Natl Acad Sci U S A* 1997;94(12):6380-5.
74. Yang JG, Sun NX, Cui LJ, Wang XH, Feng ZH. Adenovirus-mediated delivery of p27(KIP1) to prevent wound healing after experimental glaucoma filtration surgery. *Acta Pharmacol Sin* 2009;30(4):413-23.
75. Harper JW, Adami GR, Wei N, Keyomarsi K, Elledge SJ. The p21 Cdk-interacting protein Cip1 is a potent inhibitor of G1 cyclin-dependent kinases. *Cell* 1993;75(4):805-16.
76. Gartel AL, Serfas MS, Tyner AL. p21--negative regulator of the cell cycle. *Proc Soc Exp Biol Med* 1996;213(2):138-49.
77. Heatley G, Kiland J, Faha B, Seeman J, Schlamp CL, Dawson DG, et al. Gene therapy using p21WAF-1/Cip-1 to modulate wound healing after glaucoma trabeculectomy surgery in a primate model of ocular hypertension. *Gene Ther* 2004;11(12):949-55.
78. Kook H, Ahn KY, Lee SE, Na HS, Kim KK. Nitric oxide-dependent cytoskeletal changes and inhibition of endothelial cell migration contribute to the suppression of angiogenesis by RAD50 gene transfer. *FEBS Lett* 2003;553(1-2):56-62.
79. Shin BA, Ahn KY, Kook H, Koh JT, Kang IC, Lee HC, et al. Overexpressed human RAD50 exhibits cell death in a p21(WAF1/CIP1)-dependent manner: its potential utility in local gene therapy of tumor. *Cell Growth Differ* 2001; 12(5):243-54.
80. Yoon KC, Yang KJ, Seo JS, Lee SE, Heo T, Chun BJ, et al. Effect of human RAD50 gene therapy on glaucoma filtering surgery in rabbit eye. *Curr Eye Res* 2004;28(3):181-7.
81. Stavarakas P, Georgopoulos G, Milia M, Papaconstantinou D, Bafa M, Stavarakas E, et al. The use of amniotic membrane in trabeculectomy for the treatment of primary open-angle glaucoma: a prospective study. *Clin Ophthalmol* 2012;6:205-12.

82. Takeuchi K, Nakazawa M, Yamazaki H, Miyagawa Y, Ito T, Ishikawa F, et al. Solid hyaluronic acid film and the prevention of post-operative fibrous scar formation in experimental animal eyes. *Arch Ophthalmol* 2009;127(4): 460-4.
83. Chen HS, Ritch R, Krupin T, Hsu WC. Control of filtering bleb structure through tissue bio-engineering: An animal model. *Invest Ophthalmol Vis Sci* 2006;47(12):5310-4.
84. Weiss A, den Bergh Hv, Griffioen AW, Nowak-Sliwinski P. Angiogenesis inhibition for the improvement of photodynamic therapy: the revival of a promising idea. *Biochim Biophys Acta* 2012;1826(1):53-70.
85. Henderson BW, Owczarczak B, Sweeney J, Gessner T. Effects of photodynamic treatment of platelets or endothelial cells in vitro on platelet aggregation. *Photochem Photobiol* 1992; 56(4):513-21.
86. Stasi K, Paccione J, Bianchi G, Friedman A, Danias J. Photodynamic treatment in a rabbit model of glaucoma surgery. *Acta Ophthalmol Scand* 2006;84(5):661-6.
87. Jordan JF, Diestelhorst M, Grisanti S, Krieglstein GK. Photodynamic modulation of wound healing in glaucoma filtration surgery. *Br J Ophthalmol* 2003;87(7):870-5.
88. Soong HK, Malta JB. Femtosecond lasers in ophthalmology. *Am J Ophthalmol* 2009; 147(2):189-197.e2.
89. Shi Y, Yang XB, Dai NL, Long H, Lu PX, Jin L, et al. External sclerostomy with the femtosecond laser versus a surgical knife in rabbits. *Int J Ophthalmol* 2012;5(3):258-65.
90. Anand N, Wechsler D. Deep sclerectomy with mitomycin C in eyes with failed glaucoma surgery and pseudophakia. *Eye (Lond)* 2012; 26(1):70-9.
91. Shaarawy T, Nguyen C, Schnyder C, Mermoud A. Comparative study between deep sclerectomy with and without collagen implant: long term follow up. *Br J Ophthalmol* 2004; 88(1):95-8.
92. Bissig A, Rivier D, Zaninetti M, Shaarawy T, Mermoud A, Roy S. Ten years follow-up after deep sclerectomy with collagen implant. *J Glaucoma* 2008;17(8):680-6.
93. Mansouri K, Shaarawy T, Wedrich A, Mermoud A. Comparing polymethylmethacrylate implant with collagen implant in deep sclerectomy: a randomized controlled trial. *J Glaucoma* 2006;15(3):264-70.
94. Galassi F, Giambene B. Deep sclerectomy with SkGel implant: 5-year results. *J Glaucoma* 2008;17(1):52-6.
95. Devloo S, Deghisilage C, Van Malderen L, Goethals M, Zeyen T. Non-penetrating deep sclerectomy without or with autologous scleral implant in open-angle glaucoma: medium-term results. *Graefes Arch Clin Exp Ophthalmol* 2005;243(12):1206-12.
96. Mousa AS. Preliminary evaluation of nonpenetrating deep sclerectomy with autologous scleral implant in open-angle glaucoma. *Eye (Lond)* 2007;21(9):1234-8.
97. Studený P, Koliášová L, Siveková D, Vránová J, Kuchynka P. [Long term efficiency of a deep sclerectomy with T-flux implant]. *Cesk Slov Oftalmol* 2011;67(1):7-11.
98. Bahar I, Kaiserman I, Trope GE, Rootman D. Non-penetrating deep sclerectomy for glaucoma surgery using the femtosecond laser: a laboratory model. *Br J Ophthalmol* 2007; 91(12):1713-4.
99. Yalvaç IS. [Seton surgery complications in glaucoma]. *Turkiye Klinikleri J Ophthalmol-Special Topics* 2012;5(1):109-14.
100. Costa VP, Azuara-Blanco A, Netland PA, Lesk MR, Arcieri ES. Efficacy and safety of adjunctive mitomycin C during Ahmed Glaucoma Valve implantation: a prospective randomized clinical trial. *Ophthalmology* 2004;111(6):1071-6.
101. Mahdy RA. Adjunctive use of bevacizumab versus mitomycin C with Ahmed valve implantation in treatment of pediatric glaucoma. *J Glaucoma* 2011;20(7):458-63.
102. Ma KT, Yang JY, Kim JH, Kim NR, Hong S, Lee ES, et al. Surgical results of Ahmed valve implantation with intraoperative bevacizumab injection in patients with neovascular glaucoma. *J Glaucoma* 2012;21(5):331-6.
103. Irak I, Moster MR, Fontanarosa J. Intermediate-term results of Baerveldt tube shunt surgery with mitomycin C use. *Ophthalmic Surg Lasers Imaging* 2004;35(3):189-96.
104. Taglia DP, Perkins TW, Gangnon R, Heatley GA, Kaufman PL. Comparison of the Ahmed Glaucoma Valve, the Krupin Eye Valve with Disk, and the double-plate Molteno implant. *J Glaucoma* 2002;11(4):347-53.
105. Jacob JT, Lacour OJ, Burgoyne CF. Slow release of the antimetabolite 5-fluorouracil (5-FU) from modified Baerveldt glaucoma drains to prolong drain function. *Biomaterials* 2001; 22(24):3329-35.