

A Modified Technique for Orientation of an Adhesive Retained Ear Prosthesis: Case Report

Adezif Yapıştırılan Kulak Protezinin Oryantasyonunda Modifiye Bir Teknik

Arzu ATAY, Dr., Assoc.Prof.,^a
Yumuşhan GÜNAY, Dr., Prof.,^a
Cem KURTOĞLU, Dr., Assoc.Prof.,^b
Banu KARAYAZGAN, Dr. Dt.,^c
Mustafa ERKAN, Dr., Assis.Prof.,^a
Şeniz KARAÇAY, Dr., Assoc.Prof.^a

^aDental Clinic,
GATA Haydarpaşa Training Hospital,
İstanbul

^bDepartment of Prosthetic Dentistry
Çukurova University Faculty of Dentistry,
Adana

^cDepartments of Maxillofacial Prosthetics,
İstanbul University, İstanbul

Geliş Tarihi/Received: 22.01.2010
Kabul Tarihi/Accepted: 08.10.2010

*This case report was presented as a poster in
55th American Academy of
Maxillofacial Prosthetics Annual Meeting,
27-30 October, 2007, Scottsdale, Arizona.*

Yazışma Adresi/Correspondence:
Arzu ATAY, Dr., Assoc.Prof.
GATA Haydarpaşa Training Hospital,
Dental Clinic, İstanbul,
TÜRKİYE/TURKEY
arzuatay@gmail.com

ABSTRACT Maxillofacial prostheses may be considered as a treatment alternative for congenital or traumatic defects. There are two orientation problems that should be considered during the planning of an ear prosthesis. One of the problems is to determine the right position of prostheses according to symmetric side on the head. The other problem is, if necessary, positioning the implants in reference to the healthy side. Different methods have been proposed in order to deal with these problems. The aim of this study was to introduce a modified method of orientation and to discuss the results with a previously presented investigation.

Key Words: Prostheses and implants; maxillofacial prosthesis implantation

ÖZET Çene-yüz protezleri, travmatik veya gelişimsel defektlerde alternatif bir tedavi yöntemi olarak kabul edilebilir. Kulak protezlerinin planlanması sürecinde iki uyumlama problemi ile karşılaşılır. Bu problemlerden bir tanesi başın simetrik tarafı ile ilişkili olarak göre doğru yerleşimi belirlemektir. Diğer problem ise eğer gerekli ise sağlam tarafa göre implantları pozisyonlandırmaktır. Bu problemlerin çözümü ile ilgili bir çok farklı yöntemler önerilmiştir. Bu çalışmada amaç modifiye edilmiş bir oryantasyon yöntemini sunmak ve önceki çalışmalar ile sonuçları tartışmaktır.

Anahtar Kelimeler: Protezler ve implantlar; çene-yüz protezi implantasyonu

Türkiye Klinikleri J Med Sci 2012;32(2):545-8

Facial prostheses act as alternatives and supplement for the surgical reconstruction of the patients with facial defects, regardless of their cause; congenital, traumatic or infectious.¹⁻³ Ear prosthesis are the most common treatment alternatives among the maxillofacial prostheses. Implants or tissue adhesives can be utilized for retaining these prostheses. There are two orientation issues that should be considered during the planning of an ear prosthesis; with and without implant retention. One of the problems is to determine the right position of prostheses according to symmetric side on the head while the other one is to determine the appropriate location of implants if an implant treatment is considered.

Determination of the correct position for the auricular prosthesis is the most important procedure for a successful prosthetic treatment. This procedure could be solved easily by the observation of external ear or utilization of the anatomical references. When there are no anatomical references,

orientation acts as a major issue. Generally there are irregular defect sides that create deviation in patients with extensive soft and hard tissue defects and congenital defects. Several options have been introduced for solving these problems. These alternatives are the application of face-bow, chin-cap and several instruments. X-ray methods serve as alternative methods in case the patient's economical status is fine.⁴⁻⁸ With the utilization of these methods, implant-retained or adhesive-retained prostheses can be properly orientated.

Another orientation problem is the determination of the correct positioning of implants, and subsequently the correct implant surgery. The surgical template fabricated preoperatively is used for a successful and verified implant surgery. The aim of using these surgical templates is to determine the right position of implants with the utilization of X-rays to transfer these verified localizations to the surgical procedure.

The first aim of this case report was to fabricate a guide to determine the implant positions for the retention of an auricular prosthesis. However, as a result of insufficient implant support, retention was performed with a medical adhesive a technique regarding proper positioning was introduced.

CASE REPORT

A 27-year-old male patient was referred to GATA Haydarpaşa Training Hospital Dental Service, Department of Prosthodontics. In his auricular inspection, the helix of right external ear, anatomical references and external auditory meatus was missing. After examination, an implant-retained silicone ear prosthesis was considered for reconstruction. A pre-prosthetic study was done in order to determine the right position of the prosthesis and the implant. The treatment procedure was explained to the patient and his oral and written permissions were obtained for such a procedure.

TECHNIQUE

A face-bow (AEB Face Bow, Dentatus USA Ltd., New York, USA) was oriented on the patient's face by using the references obtained from both of the

infraorbital points and external auditory meatus of the healthy side (Figure 1). The cusp tip of face-bow that contacted the skin was marked with a skin marking pen (Figure 2). This process was repeated five times, and the exact location was determined.

Irreversible hydrocolloid impressions (Jeltrate Plus; Dentsply Caulk, Milford, Del) of the defect and the opposite ear were made, and the cast was poured in dental stone (Glass Stone 3000 Type V; Dentsply Int Inc. York, PA). An auricular wax pattern (Neowax; Dentsply Trubyte, York, Pa) wax was sculpted to the final contours, acceptable to the patient. The wax model was oriented in the defect area and the margins of wax model was assigned on the tissue with an indelible pencil. Then the wax pattern was flaked, boiled out and processed in clear acrylic resin (Lucitone Clear; Dentsply Trubyte) with conventional techniques.

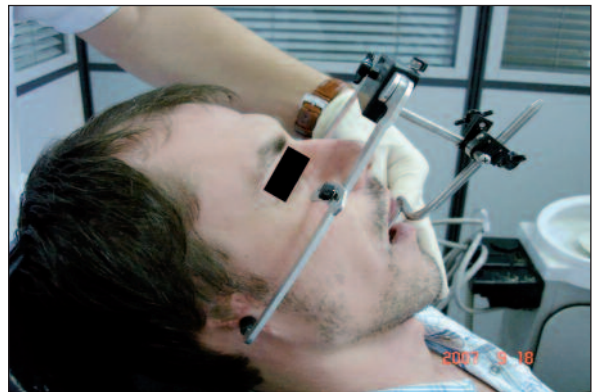

FIGURE 1: The orientation of face-bow.

(See for colored form <http://tipbilimleri.turkiyeklinikleri.com/>)

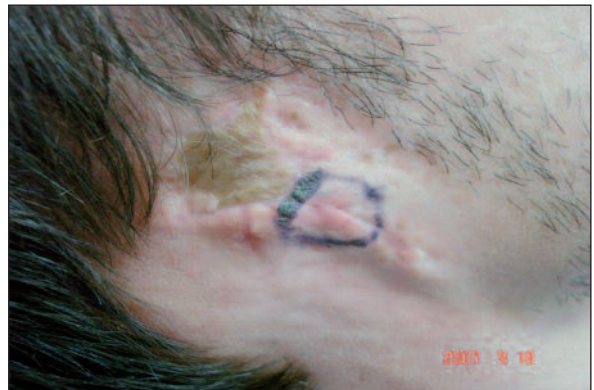

FIGURE 2: Face-bow cusp tip was marked with an indelible pencil on the defect side.

(See for colored form <http://tipbilimleri.turkiyeklinikleri.com/>)

An irreversible hydrocolloid impression (Jeltrate Plus; Dentsply Caulk, Milford, Del) of the maxillary arch was made and poured in dental stone. A maxillary acrylic resin splint was fabricated on the maxillary diagnostic cast (Lucitone Clear, Dentsply Trubyte) (Die Keen; Bayer, South Bend, Ind) providing sufficient retention by engaging undercuts on the maxillary teeth. While fabricating the splint, care was taken to provide complete occlusal coverage over the incisive edges and extension onto the palatal tissues for 6 mm. An acrylic resin projection (40 mm wide, 40 mm long, and 25 mm thick) was made at the maxillary central and lateral incisor areas. An extraoral acrylic resin bar, 30 mm in diameter, was fabricated to follow the contour of the face from the lips to the desired location of the reconstructed ear. Boxing wax (Boxing wax; Dentsply Trubyte) served as a mold for the acrylic resin bar. Then, the mold was packed with a clear autopolymerizing acrylic resin (Orthodontic acrylic; Great Lakes Orthodontics, Tonawanda, NY). The boxing wax was discarded and the excess flash was trimmed after the resin had polymerized (Figure 3).¹

A groove was made in the acrylic resin ear's antihelix region and a 1.2 mm messing wire was embedded in resin.

It was made sure to use this guide for computerized tomography. Radiologist was informed to scan including the radioopaque material and the area of 3 mm in both sides (Figure 4).



FIGURE 3: The clear acrylic diagnostic prosthesis and clear acrylic resin guide.

(See for colored form <http://tipbilimleri.turkiyeklinikleri.com/>)

The prosthesis was fabricated in silicone (A-2001 Platinum Silicone Elastomer; Factor 2, Lakeside, Ariz) The carrier part of the guide appliance was used for inserting the prosthesis in the right position. The patient was informed about using this appliance and sealing the prosthesis in the right position (Figure 5).

Fabrication of the surgical template is an important pre-prosthetic requirement.^{6,8,9} The surgical template ideally should be attached to fixed anatomical references to minimize any error that may result in incorrect implant placement.

DISCUSSION

Fabrication of a surgical template as a pre-surgical planning is one of the most important procedures and necessary for the ideal placement of implants to provide the best possible prosthetic rehabilitation for the patient. A radiologic study must always be performed in order to assess the patient's anatomy and the amount of bone before surgery. The diagnostic wax pattern is used in surgical planning and as a surgical template for mold creation. The wax pattern has been utilized for the definitive prosthesis, as well.¹⁻⁵

If there is lack of anatomical references, the determination of implant localization is generally difficult. In prosthodontics, the relationship of the occlusal plane with the other determinants of occlusion have been described by Hanau and Ercoli et al. who demonstrated an interocclusal record tech-

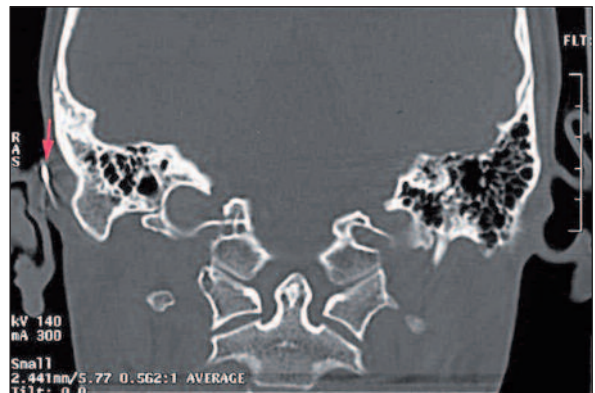


FIGURE 4: Coronal computerized tomography shows the wire arch marker on the defect side.

(See for colored form <http://tipbilimleri.turkiyeklinikleri.com/>)

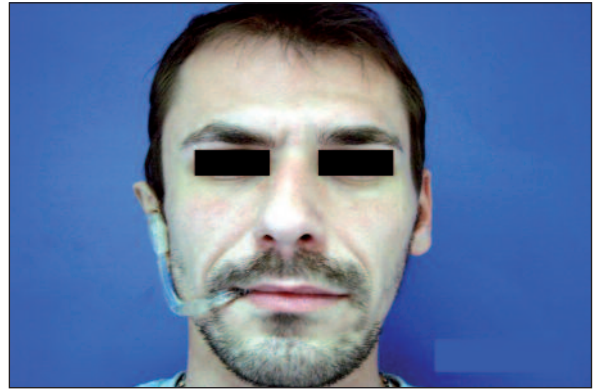
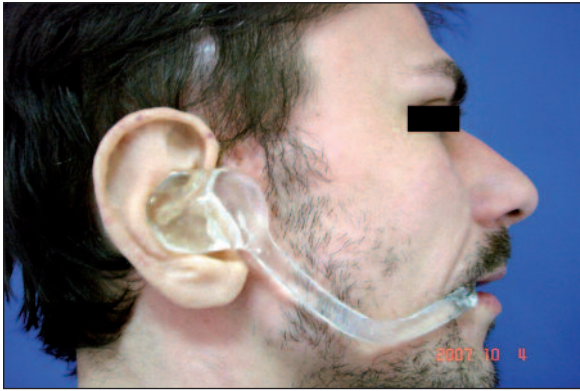
FIGURE 5: Silicone prosthesis and acrylic guide on patient.

(See for colored form <http://tipbilimleri.turkiyeklinikleri.com/>)

nique in order to record the angular relationship of the occlusal plane using a face-bow.^{4,10} This technique has been introduced to simplify the procedure during the evaluation of the location and transfer of references. Asher et al. demonstrated the use of a resin acrylic template for surgical planning and founded it easier to repose correctly during surgery due to its harmony with the patient's anatomy.⁹

According to our study, these techniques can be combined and applied, as in this case. The fabrication of a radiographic and surgical guide for craniofacial implant placement is presented in this case study. The use of the maxillary arch as a fixed reference allows the proper placement and repositioning of the device. The guide assists the radi-

ographic evaluation of the patient by placing radioopaque material over the planned implant placement locations. Another advantage of this guide was to assist the patient while positioning the ear prostheses in the correct position.

If there is inadequate bone, poor economical status and a long healing time, an adhesive-retained silicone prosthesis can be utilized. When there is a lack of anatomical references, the patient may experience orientation problems to insert the prosthesis in the right position.

This case report shows that utilization of the pre-prosthetic preparations prevent mistakes related to the insertion of implants, and simplify the placement of the prosthesis in the right position.

REFERENCES

1. Alfano SG, Robinson RF, Webber CM, Erickson KK. Fabrication of a craniofacial implant surgical and treatment planning guide. *J Prosthet Dent* 2005;93(1):91-4.
2. Serel S. [Reconstruction of tissue defects after maxillofacial trauma]. *Turkiye Klinikleri J E.N.T.-Special Topics* 2008;1(4):95-8.
3. Yüksel A, Uslu S. [Maxillofacial trauma]. *Turkiye Klinikleri J Surg Med Sci* 2006;2(28): 59-67.
4. Ercoli C, Graser GN, Tallents RH, Galindo D. Face-bow record without a third point of reference: theoretical considerations and an alternative technique. *J Prosthet Dent* 1999;82(2): 237-41.
5. Choi DG, Bowley JF, Marx DB, Lee S. Reliability of an ear-bow arbitrary face-bow transfer instrument. *J Prosthet Dent* 1999;82(2): 150-6.
6. Weinberg LA. An evaluation of the face-bow mounting. *J Prosthet Dent* 1961;11(1):32-42.
7. Zuckerman GR. The geometry of the arbitrary hinge axis as it relates to the occlusion. *J Prosthet Dent* 1982;48(6):725-33.
8. Wolfaardt JF, Troppmann R, Wilkes GH, Coss P. Surgical templates for auricular reconstruction. *J Facial Somato Prosthet* 1996; 2(1): 131-6.
9. Asher ES, Evans JH, Wright RF, Wazen JJ. Fabrication and use of a surgical template for placing implants to retain an auricular prosthesis. *J Prosthet Dent* 1999;81(2):228-33.
10. Hanau RL. Articulation defined, analyzed and formulated. *J Am Dent Assoc* 1926;13(8): 1694-707.