

Transient Posterior Urethral Valve: Sonographic Diagnosis (A Case Report)

* Turhan USLU
* Ahmet ERK

GEÇİCİ OSTERİOR ÜRETRAL VALV:
SONOGRAFİK TANI (BİR OLGU TAKDİMİ)

* Ankara Üniversitesi Tıp Fakültesi Kadın Hastalıkları ve
Doğum Anabilim Dalı

Geliş Tarihi : 10 Ağustos 1987

SUMMARY

The greatest yield of fetal anomalies discovered in utero by ultrasound has occurred in the genitourinary system. Several studies have documented striking increases in the bladder or upper collecting system, which liave spontaneously resolved and have not been felt to represent true and pemanent obstruction. In the present study a case of "transient posterior urethral valve" diagnosed by ultrasonography has been reported with a review of the literature.

Key Word*: Obstructive uropathy, posterior urethral valve, prenatal ultrasonographic diagnosis.

T J Research Med Sci V.7, N.1, 1*83, 58-60

The ability to image fetal anatomic parts and the understanding of ultrasonographic fetal anatomy have improved as the result of developments in instrumentation. This information is of value in determining fetal prognosis, in deciding the method of delivery and in alerting the pediatric staff to supportive and corrective measures which may need to be taken in the postnatal period. Recent developments allow antenatal therapeutic interventions such as the relief of urethral obstruction by the intrauterine insertion of a self-retaining suprapubic catheter which provides a bladder-amniotic fluid shunt. Since this is an invasive procedure with yet unproved clinical efficacy (1, 2, 4, 5, 7, 8,10,11,12).

The greatest yield of fetal anomalies discovered in utero by ultrasound has occurred in the genitourinary system. The most common condition encountered is obstructive uropathies. Since the side and extent of obstruction are so varied, it is difficult for caretakers to assess the prognosis and develop a plan of management for each patient (2, 5, 7, 8, 9, 10,11).

At present, stenosis of urethra is one of the congenital defects for which intrauterine intervention can

ÖZET

Genitoüriner sistemde görülen anomaliler, inutero olarak ultrasonografi ile en sık olarak tespit edilen fetal anomalilerdir. Çeşitli yayınlarda mesanede ve üst kollektör sistemde gösterilen belirgin genişlemenin aniden düzeldiği bildirilmiştir. Bu nedenle bir kısım vakada gerçek katta bir tıkanmanın olmadığı kanısına varılmıştır. Bu yazıda ultrasonografi ile teşhis ettiğimiz bir "geçici posterior üretral valv" olgusu anlatılarak literatür gözden geçirilmiştir.

Anahtar Kelimeler: Obstrüktif üropati, posterior üretral valv, prenatal ultrasonografik tanı.

T Kİ Tıp Bil Araş Dergisi C.7, S.1, 1989. 58*0

be considered. However the degree and the time of onset of the obstruction vary widely, and the optimal time of intervention is currently not known (2, 3, 6, 7, 8, 9, 10).

In this paper we described a fetus in which an obstruction of the urethra was diagnosed at 30 weeks of gestation. Subsequently we were able to monitor the pregnancy sonographically until birth at 36 weeks without interference.

CASE REPORT

Because of clinical suspicion of intrauterine growth retardation a sonographic examination was performed in a 25 years old primigravid woman at 30 weeks of gestation. A distended fetal bladder, bilateral hydronephrosis and bilateral hydroureters were found (Figure 1, 2, 3). Since amniotic fluid volume was found normal, so severe urethral obstruction could not be assumed. Therefore we decided to monitor the pregnancy without interference. Until 34 weeks the subsequent weekly scans showed gross alterations from the first scan and the amniotic fluid

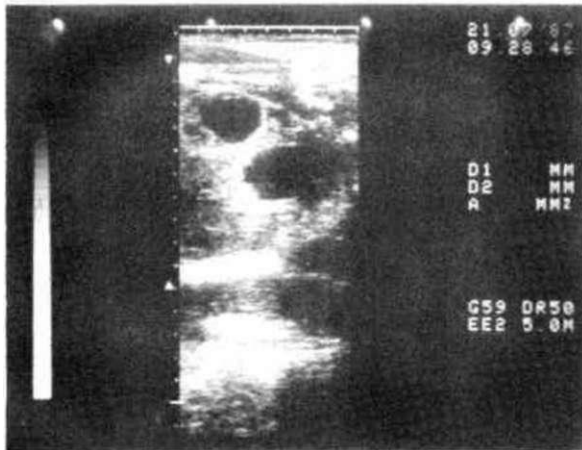


Figure 1. Sagittal section through fetal abdomen demonstrating hydronephrosis and distended bladder.

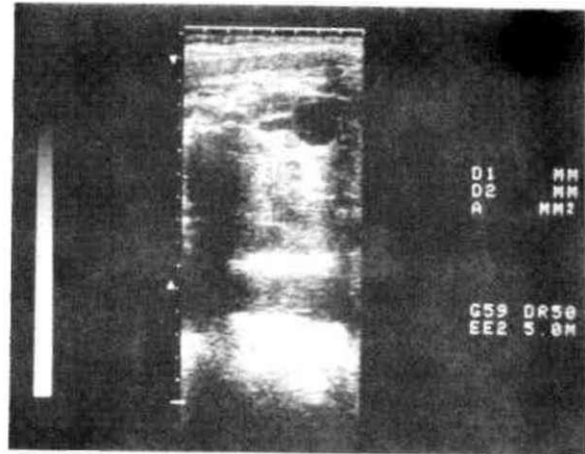


Figure 2. Ultrasonic appearance of left hydronephrotic kidney.

volume persisted to be normal. Eventually at 34 weeks of gestation we found out that hydronephrosis and hydroureters disappeared spontaneously. Labor ensued at 36 weeks and the patient was delivered of a 2250 gm. male infant without any deformities.

DISCUSSION

This case suggests that an obstruction due to an urethral valve may rupture spontaneously or the ball valve mechanism may be reserved by the change in dynamics associated with bladder drainage (3, 6, 7, 10, 11). This phenomenon may represent a fortuitous bonus to intra uterine shunting in some fetuses or may be an unrelated event. Moreover, spontaneous rupture could well occur in fetuses without surgical intervention (1, 3, 5, 6, 7, 10, 11, 12).

Since hydronephrosis be transient before contemplating interventional procedures in utero which could cause many complications, one should make sure that hydronephrosis is persistent and that there is a genuine reduction in amniotic fluid quantity. Obstruction can not be considered on all or nothing phenomenon and different grades of stenosis will give different appearances that vary from bladder dilatation alone to bladder dilatation with bilateral hydronephrosis.

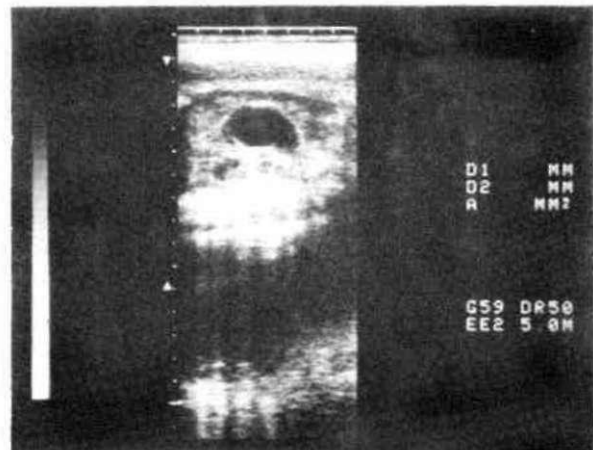


Figure 3. Oblique scan through fetal abdomen demonstrating hydronephrosis of right fetal kidney and hydroureter.

One is unable to determine from ultrasound appearance whether irreversible renal changes have already occurred. Rigid rules can not be made on the basis of available published data. For the present, however, some basic judgements can be made concerning the prognosis for some of these variations and the risks and benefits must be carefully assessed before a plan of management is chosen.

REFERENCES

1. Berkowitz RL., Glickman MG., Walker Smith GJ., et al.: Fetal urinary tract obstruction: What is the role of surgical intervention in utero. *Am. J. Obstet. Gynecol.* 144: 367, 1982.
2. Erk A., Uslu T.: Fetal renal anomalilerin intrauterin tanısında ultrasonografi. *MEDİCA.* 3: 20-22, 1987.
3. Farkas A., Eidelman AI., Gale R.: Transient perinatal urinary retention: A cautionary note for the fetal surgeon. *Am J. Obstet. Gynecol.* 147: 461-462, 1983.
4. Golbus MS., Harrison MR., Filly RA., et al.: In utero treatment of urinary tract obstruction. *Am. J. Obstet. Gynecol.* 142: 383-388, 1982.

5. Gruenewald SM., Crocker EF., Walker A G., et al.: Antenatal diagnosis of urinary tract abnormalities.: Correlation of ultrasound appearance with postnatal diagnosis. *Am. J. Obstet. Gynecol.* 148: 278-283, 1984.
6. Hellstrom WJG., Kogan BA., Jefferey RB., et al.: The natural history of prenatal hydronephrosis with normal amounts of amniotic fluid. *J. Urol.* 132: 947-950, 1984.
7. Hobbins J C , Remore R', Grannum P., et al.: Antenatal diagnosis of renal anomalies with ultrasound. 1. Obstructive uropathy. *Am. J. Obstet. Gynecol.* 148: 866-876., 1984.
8. Jeanty P., Romera R.: *Obstetrical ultrasound. First edition.* New York. Mc Graw-Hill. pp 143-149, 1984.
9. Karenromp M.J., Stassen MJP., Ertbruggen I., ?jek R.: The natural course of early intrauterine urethral obstruction. *Am. J. Obstet. Gynecol.* 147: 465-466, 1983.
10. Sanders R C , Graham D': Twelve cases of hydronephrosis in utero diagnosed by ultrasonography. *J. Ultrasound Med.* 1: 341-348, 1982.
11. Sanders R C , James A E. ; *The principles and practice of ultrasonography in obstetrics and gynecology. Third edition.* Norwalk-Connecticut. Appleton Century-Crofts, pp. 195-207, 1985.
12. Sard P., Bard H., Teasdale F., Grignon A.: The importance of an antenatal ultrasonographic diagnosis of correctable fetal malformations. *Am. J. Obstet. Gynecol.* 147: 443-445, 1983.