

# A Rare Presentation of Systemic Lupus Erythematosus with Leg Ulcers and Degos-Like Lesions

## Bacak Ülserleri ve Degos Benzeri Lezyonlar Bulunan Sistemik Lupus Eritematozusun Nadir Bir Sunumu

<sup>id</sup> Ayesha SHARMEEN<sup>a</sup>, <sup>id</sup> Hania Qamar KHAN<sup>a</sup>, <sup>id</sup> Syed Suhail AMIN<sup>a</sup>, <sup>id</sup> Mohammad ADIL<sup>a</sup>

<sup>a</sup>Department of Dermatology, Jawaharlal Nehru Medical College, Aligarh Muslim University, Aligarh, India

**ABSTRACT** Degos-like lesions (DLL) have been associated with connective tissue diseases. Till date only twelve cases of systemic lupus erythematosus (SLE) with DLL have been published. We describe a rare case of SLE with leg ulcers and DLL. A 23-year-old male presented with malar rash, photosensitivity, leg ulcers, joint pain, oral ulcers, altered sensorium and dyspnea. Cutaneous examination also revealed atrophic, porcelain-white scars over body previously unnoticed by patient. Dermoscopy of atrophic lesions was pathognomonic of Degos disease. Histopathology from various lesions were consistent with Degos disease and SLE. Patient was admitted in intensive care unit but succumbed to multiorgan failure two days later. This case highlights the importance of dermoscopy for immediate diagnosis of DLL. Appropriate investigations for early diagnosis and timely management can decrease mortality. Also a thorough examination in cases of connective tissue diseases may reveal uncommon lesions that can alter clinical course and outcome of patients.

**Keywords:** Systemic lupus erythematosus; degos disease; leg ulcers; dermoscopy

**ÖZET** Degos benzeri lezyonlar [Degos-like lesions (DLL)] bağ dokusu hastalıklarıyla ilişkilidir. Bugüne kadar yalnızca 12 DLL'li sistemik lupus eritematozus [systemic lupus erythematosus (SLE)] vakası yayınlanmıştır. Bu çalışmada bacak ülserleri ve DLL bulunan nadir bir SLE vakası tanımladık. 23 yaşında bir erkek, malar raş, fotosensitivite, bacak ülserleri, eklem ağrısı, oral ülserler, sensoryum değişikliği ve dispne ile başvurmuştur. Ayrıca, cilt muayenesinde, hastanın vücudunda daha önce fark etmediği atrofik, porselen beyazı yaralar olduğu ortaya çıkmıştır. Atrofik lezyonların dermoskopisi, Degos hastalığı için patognomiktir. Çeşitli lezyonlardan yapılan histopatoloji, Degos hastalığı ve SLE ile uyumluydu. Hasta yoğun bakım ünitesine kaldırıldı ancak 2 gün sonra çoklu organ yetmezliğine yenik düştü. Bu vaka DLL'nin hızlı tanısında dermoskopinin önemini vurgulamaktadır. Erken tanı ve zamanında müdahale için uygun araştırmalar mortaliteyi azaltabilir. Ayrıca bağ doku hastalıkları vakalarında kapsamlı bir muayene, hastaların klinik seyrini ve sonuçlarını değiştirebilecek nadir lezyonların ortaya çıkmasını sağlayabilir.

**Anahtar Kelimeler:** Sistemik lupus eritematozus; degos hastalığı; bacak ülserleri; dermoskopi

Degos disease (DD) also known as malignant atrophic papulosis was described by Köhlmeier and Degos in 1942.<sup>1</sup> It is a vaso-occlusive disorder affecting skin, central nervous system, and gastrointestinal tract. Degos-like lesions have been reported with many connective tissue diseases (CTD), mainly systemic lupus erythematosus (SLE).<sup>1</sup> Twelve cases of SLE with Degos-like lesions were found on literature search. We describe a case of SLE with leg ulcers and Degos-like lesions, not previously reported.

### CASE REPORT

A 23-year-old male presented with malar rash, photosensitivity, and leg ulcers for 2 years, joint pain and oral ulcers for 4 months, altered sensorium and dyspnea for 10 days. Two months back patient was diagnosed with SLE at another centre, and prescribed hydroxychloroquine (400 mg/day).

On examination, patient had tachycardia (124/min), hypotension (80/50 mm of Hg), tachyp-

**Correspondence:** Ayesha SHARMEEN

Department of Dermatology, Jawaharlal Nehru Medical College, Aligarh Muslim University, Aligarh, India

E-mail: haniaqamar@hotmail.com



Peer review under responsibility of Türkiye Klinikleri Journal of Dermatology.

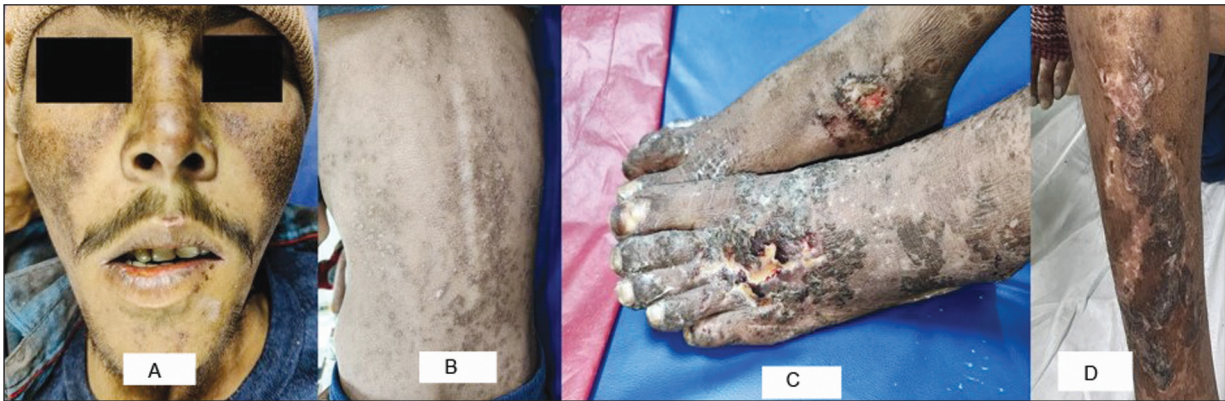Received: 29 Jun 2022

Received in revised form: 30 Sep 2022

Accepted: 03 Jan 2023

Available online: 10 Jan 2023

2146-9016 / Copyright © 2023 by Türkiye Klinikleri. This is an open access article under the CC BY-NC-ND license (<http://creativecommons.org/licenses/by-nc-nd/4.0/>).

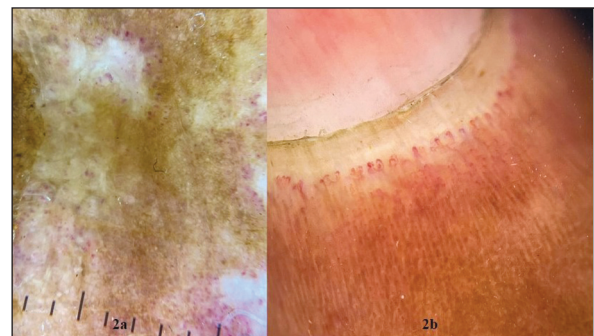


**FIGURE 1:** a) Erythema and scaling with hyperpigmentation seen over malar area and dorsum of nose. b) Multiple porcelain-white atrophic scars and hyperpigmented macules seen diffusely over back. c) Ulcers with necrotic slough seen over medial malleoli and dorsa of feet and legs along with porcelain-white scars. d) Multiple ulcers, few healing with porcelain-white scarring over extensor aspect of legs.

nea (24/min), 60% oxygen saturation and altered consciousness.

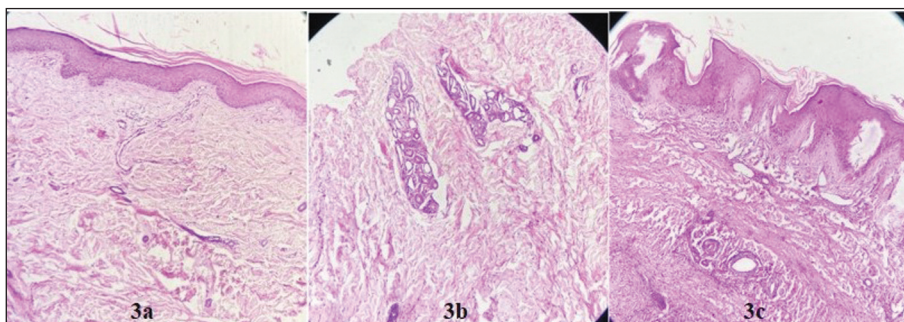
Cutaneous examination revealed malar rash (Figure 1a), palatal erosions, atrophic, porcelain-white scars over back and dorsum of hands (Figure 1b). Multiple petechiae and pinpoint necrotic ulcers were seen over palms and soles (Figure 1c). Multiple ulcers of variable sizes with necrotic slough, few healing with porcelain-white scarring were seen over medial malleoli and dorsa of feet and legs (Figure 1c, Figure 1d).

Dermoscopy of atrophic lesions showed central whitish structureless area with erythematous telangiectatic rim (Figure 2a). Nail fold capillaroscopy showed dilated and glomerulized blood vessels (Figure 2b).



**FIGURE 2:** a) Dermoscopy of atrophic lesions showing central whitish structureless area with erythematous telangiectatic rim (DermLite DL4 polarized mode 10x). b) Nail fold capillaroscopy showing dilated and glomerulized blood vessels (DermLite DL4 polarized mode 10x).

Investigations showed neutrophilic leukocytosis (23,700/mm<sup>3</sup>), raised urea nitrogen (77 mg/dL) and



**FIGURE 3:** a) Histopathology showing epidermal thinning with mild dermal perivascular lymphocytic infiltrate and dermal infarct (H&E, x400). b) Histopathology showing perivascular lymphocytic infiltrate with obliterated lumen of blood vessels by proliferation of endothelial cells (H&E, x400) c) Histopathology showing follicular plugging, edema, leukocytoclastic vasculitis and nuclear dust in subepithelial region, with dermal fibrinoid necrosis (H&E, x400).

serum creatinine (4.8 mg/dL), positive anti-nuclear antibody (1:1,280), and anti-ds-DNA antibody. Skin biopsy from atrophic-white lesion revealed epidermal thinning with mild dermal perivascular lymphocytic infiltrate and infarct (Figure 3a). Biopsy from ulcer edge revealed perivascular lymphocytic infiltrate with obliterated lumen of blood vessels by proliferation of endothelial cells (Figure 3b). Biopsy from a plaque showed follicular plugging, edema, leukocytoclastic vasculitis and nuclear dust in subepithelial region, with dermal fibrinoid necrosis (Figure 3c).

With these clinical, dermoscopic, and laboratory features, diagnosis of Degos-like lesions associated with SLE was made.

Patient was admitted in intensive care unit and was being treated with inotropes, intravenous dexamethasone, intravenous piperacillin-tazobactam, hydroxychloroquine 400 mg/day but succumbed to multiorgan failure two days later.

Appropriate written consent has been taken from patients parents for publication of patient's photographs in the journal.

## DISCUSSION

DD is of two types, isolated DD with or without internal organ involvement, and Degos-like lesions in association with CTD. Only upto 15% cases have isolated cutaneous involvement. Systemic involvement especially gastrointestinal and central nervous system, is associated with increased mortality (upto 50%).<sup>2</sup>

Degos-like lesions are associated with CTDs like SLE, dermatomyositis, systemic sclerosis, overlap syndromes. Many cases presenting with cutaneous DD have only laboratory findings suggestive of CTDs.<sup>3-5</sup> Till date 12 cases of DD with SLE have been reported, with majority in females.<sup>6</sup> Degos-like lesions have preceded other features of SLE by 2 years and 8 years in two cases.<sup>7</sup> One female presented with DD developed lupus nephritis during pregnancy 1-year later.<sup>3</sup> Others presented with concomitant or late-onset of Degos-like lesions by 1-7 years.<sup>6</sup> Malar erythema, photosensitivity, chronic cutaneous LE,

bullous SLE, and arthritis were the clinical features of SLE reported with Degos-like lesions.<sup>6</sup> Our patient had oral ulcers, palmoplantar and leg ulcers, malar rash, along with Degos-like lesions. One study described DD-like lesions and leg ulcers in SLE patient with Lupus Anticoagulant but concomitant leg ulcers and DD have not been previously reported.<sup>4</sup> Ulcers in our patient had features of livedoid vasculopathy, but tenderness could not be elicited due to his altered sensorium.

These classical lesions can be identified by naked eye in white skin, but are difficult to appreciate in skin of colour. Degos-like lesions were unnoticed by our patient and were seen on clinical examination in our Outpatient department confirmed immediately on dermoscopy. A previous report of DD with SLE showed similar white stellate structureless areas surrounded by telangiectasia on dermoscopy.<sup>8</sup> Dermoscopy of Degos-like lesions shows three different patterns, each one corresponds to a different evolution stage. Early stage papules show combination of a reddish-to-purple background and purpuric dots. In the second stage, targetoid pattern with yellowish, purple or necrotic centre surrounded by an erythematous halo is seen. Finally in the third stage, dermoscopy of healed lesions shows a white structureless centre surrounded by a rim of short, thin and slightly curved vessels.<sup>9</sup> In our patient, dermoscopic findings matched with the third stage.

Histopathological examination from the three sites revealed thrombotic, vasculitic process. Although mucin deposition is a characteristic feature in SLE, it was not detected in biopsy samples from our patient. Depending on duration, location and type of lesion, amount and distribution of mucin deposition varies.<sup>10</sup> Also being on hydroxychloroquine therapy for 2 months could result in decreased fibroblast product of mucin, which was not detected in the biopsy samples of our patient.

Thorough investigation could not be performed because the patient presented to us in late stage and succumbed to the complications. The required tests could have revealed if renal or neurological involvement was due to SLE or DD.

This case highlights the importance of dermoscopy for immediate diagnosis of DD. Degos-like lesions can be first presentation of underlying CTD. Appropriate investigations and regular follow-up would help in early diagnosis and timely management can decrease mortality. Also a thorough cutaneous examination in CTD may reveal uncommon lesions that can alter clinical course and outcome of patients as seen in our case.

### Acknowledgement

We acknowledge the valuable contribution of Dr. Murad Ahmed, Assistant Professor, Department of Pathology, Jawaharlal Nehru Medical College, AMU, Aligarh for providing us the histopathological analysis of the patient's biopsy samples.

### Source of Finance

During this study, no financial or spiritual support was received neither from any pharmaceutical company that has a direct connection with the research subject, nor from a company that pro-

vides or produces medical instruments and materials which may negatively affect the evaluation process of this study.

### Conflict of Interest

No conflicts of interest between the authors and / or family members of the scientific and medical committee members or members of the potential conflicts of interest, counseling, expertise, working conditions, share holding and similar situations in any firm.

### Authorship Contributions

**Idea/Concept:** Ayesha Sharmen, Hania Qamar Khan, Syed Suhail Amin; **Design:** Ayesha Sharmen, Mohammad Adil, Hania Qamar Khan; **Control/Supervision:** Hania Qamar Khan; **Data Collection and/or Processing:** Hania Qamar Khan, Ayesha Sharmen, Mohammad Adil, Syed Suhail Amin; **Analysis and/or Interpretation:** Ayesha Sharmen, Hania Qamar Khan; **Literature Review:** Ayesha Sharmen, Hania Qamar Khan; **Writing the Article:** Ayesha Sharmen, Hania Qamar Khan; **Critical Review:** Ayesha Sharmen, Mohammad Adil.

## REFERENCES

- Jang MS, Park JB, Yang MH, Jang JY, Kim JH, Lee KH, et al. Degos-like lesions associated with systemic lupus erythematosus. *Ann Dermatol*. 2017;29(2):215-8. [[Crossref](#)] [[PubMed](#)] [[PMC](#)]
- Tummidi S, Nagendran P, Gedela S, Ramani JR, Shankaralingappa A. Degos disease: a case report and review of the literature. *J Med Case Rep*. 2020;14(1):204. [[Crossref](#)] [[PubMed](#)] [[PMC](#)]
- Doutre MS, Beylot C, Bioulac P, Busquet M, Conte M. Skin lesion resembling malignant atrophic papulosis in lupus erythematosus. *Dermatologica*. 1987;175(1):45-6. [[Crossref](#)] [[PubMed](#)]
- Stephansson EA, Niemi KM, Jouhikainen T, Vaarala O, Palosuo T. Lupus anticoagulant and the skin. A longterm follow-up study of SLE patients with special reference to histopathological findings. *Acta Derm Venereol*. 1991;71(5):416-22. [[PubMed](#)]
- Lima Lde A, Haddad Nde C, Lima RB, D'Acri AM, Martins CJ. Case for diagnosis. *An Bras Dermatol*. 2014;89(3):521-2. [[Crossref](#)] [[PubMed](#)] [[PMC](#)]
- Stavorn T, Chanprapaph K. Degos-like lesions in association with connective tissue diseases: a report of three cases and literature review. *Clin Cosmet Investig Dermatol*. 2019;12:815-22. [[Crossref](#)] [[PubMed](#)] [[PMC](#)]
- Black MM, Hudson PM. Atrophic blanche lesions closely resembling malignant atrophic papulosis (Degos' disease) in systemic lupus erythematosus. *Br J Dermatol*. 1976;95(6):649-52. [[Crossref](#)] [[PubMed](#)]
- Vinay K, Sawatkar G, Dogra S, Saikia UN. Systemic lupus erythematosus with Degos disease: role of dermatoscopy in diagnosis. *Int J Dermatol*. 2017;56(7):770-2. [[Crossref](#)] [[PubMed](#)]
- Anker JP, Kaminska-Winciorek G, Lallas A, Nicoletti S, Januszewski K, Mazzei ME, et al. The dermoscopic variability of Degos disease at different stages of progression. *Dermatol Pract Concept*. 2014;4(3):59-61. [[Crossref](#)] [[PubMed](#)] [[PMC](#)]
- Hood AF, Farmer ER. Histopathology of cutaneous lupus erythematosus. *Clin Dermatol*. 1985;3(3):36-48. [[Crossref](#)] [[PubMed](#)]