

A Patient with VACTERL Association Complicated with Postoperative Lung Infection After Cardiac Surgery: Case Report

Bir Hastada Kardiyak Cerrahi Sonrası Postoperatif Akciğer Enfeksiyonu ile Komplike Olan VACTERL Birlikteliği

Murat ÖZEREN, MD,^a
M. Kerem KARACA, MD,^a
Olgu HALLIOĞLU, MD,^b
Barlas Naim AYTAÇOĞLU, MD,^a
Özden VEZİR, MD,^a
Nehir SUCU, MD^a

Departments of
^aCardiovascular Surgery,
^bPediatrics
Division of Pediatric Cardiology,
Mersin University Faculty of Medicine,
Mersin

Geliş Tarihi/Received: 28.12.2009
Kabul Tarihi/Accepted: 18.03.2010

Yazışma Adresi/Correspondence:
M. Kerem KARACA, MD
Mersin University Faculty of Medicine
Department of Cardiovascular Surgery,
Mersin,
TÜRKİYE/TURKEY
karacamk@yahoo.com

ABSTRACT VACTERL Association is a rare genetic disorder that involve multiple organ systems pathology. Musculoskeletal, gastrointestinal and cardiac anomalies association are the most common components of this syndrome. Cardiac anomalies are generally Ventricular Septal Defect (VSD), Atrial Septal Defect (ASD) and Tetralogy of Fallot. Cardiac components of VACTERL Association can be treated easily using open heart surgical techniques but noncardiac components of VACTERL Association can complicate operative and postoperative courses. Lung infection is not a common problem after repair of isolated ASD by open heart surgery. In this report, we present lung infection that complicated the postoperative course of a 14-year-old female patient with VACTERL Association operated for ASD that is a component of the disorder.

Key Words: Heart septal defects, atrial; digestive system abnormalities; musculoskeletal abnormalities; congenital abnormalities

ÖZET VACTERL birlikteliği, çoklu organ sistemi patolojilerini içeren ve nadir görülen, genetik bir hastalıktır. Bu sendromda en sık görülen bileşenler kas iskelet sistemi, gastrointestinal sistem ve kardiyak anomalilerin birlikteliğidir. Kardiyak anomaliler genellikle Ventriküler septal defekt (VSD), Atriyal septal defekt (ASD) ve Fallot Tetralojisi olmaktadır. VACTERL birlikteliğinin kardiyak bileşenleri, açık kalp cerrahisi tekniklerinin kullanımı ile kolayca tedavi edilebilmekte fakat VACTERL birlikteliğinin kardiyak dışı bileşenleri operatif ve postoperatif seyri komplike edebilmektedir. Açık kalp cerrahisi teknikleri kullanılarak yapılan izole ASD onarımı sonrası akciğer enfeksiyonu, çok yaygın görülen bir problem değildir. Bu yazıda, VACTERL birlikteliği olan ve ASD nedeniyle opere edilen 14 yaşındaki kız çocuğunda, postoperatif seyri komplike hale getiren akciğer enfeksiyonu sunulmuştur.

Anahtar Kelimeler: Kalp septum kusurları, atriyal; sindirim sistemi anomalileri; kas iskelet anomalileri; doğumsal anomaliler

Türkiye Klinikleri J Cardiovasc Sci 2011;23(3):296-8

VACTERL Association is a rare genetic disorder that involves multiple organ systems, including the Vertebral defects, Anorectal atresia, Cardiac defects, Tracheo-oesophageal fistulae with or without Esophageal atresia, Renal anomalies and Limb defects. Cardiac components of the syndrome are generally Ventricular Septal Defect (VSD), Atrial Septal Defect (ASD) and Tetralogy of Fallot. VSD is the most common cardiac component of the syndrome with an incidence of 30%.¹ In this case report, we are presenting a successful surgical repair which was complicated by lung infection deteriorating the postoperative course of ASD.

CASE REPORT

A 14-year-old female patient with VACTERL Association was referred to our department with the diagnosis of ASD. In her postnatal medical history; esophageal atresia and anal atresia were diagnosed on the 1st day of life when she was a neonate; at the institution where she was born. She had an emergency end-to-end anastomosis and a colostomy to correct the esophageal and anal atresia following her diagnosis. Echocardiographic examination at the time of these interventions revealed an ostium secundum type ASD and clinical follow up was recommended.

In her physical examination, she had anomalies on her right limb (Figure 1). Her cardiac examination put forward a grade 2-3/6 systolic murmur that was heard best along the left parasternal border. Respiratory system was normal. Her pulse rate was 84 beats per min, respiratory rate was 16 breaths per min and blood pressure was 110/70 mmHg. Her recent transthoracic echocardiography showed a large ASD, a prolapsed mitral valve with minimal insufficiency. Laboratory data were normal.

The patient was informed about the anomaly and a written consent was obtained from the patient before the treatment both for the operation and for the publication of her situation.

The patient was operated electively, under standard cardiopulmonary bypass with the use of two separate venous cannulae. Secundum type ASD was closed by using a pericardial patch. Early

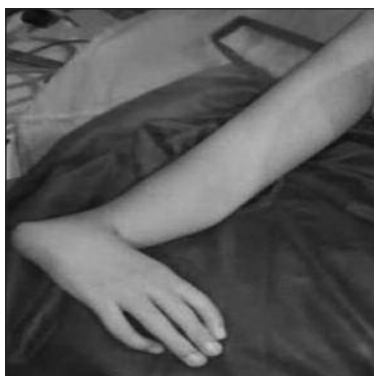

FIGURE 1: Limb defect on her right arm.

postoperative course was uneventful until the fifth postoperative day when her body temperature was raised and productive coughing started. Her chest examination revealed bilateral rales by auscultation. White-blood-cell count and C-reactive protein values indicated higher levels and then the prophylactic antibiotic cefamezine was replaced by sulperazone with the recommendation of the pediatric infectious disease clinic which diagnosed the patient to have pneumonia. Posteroanterior chest X-ray and computerized tomography of the chest confirmed pneumonia and displayed diffuse pericardial effusion (Figure 2). Postoperative echocardiography revealed 1.5 cm at the right and 0.5 cm at the left pericardial effusion. Postpericardiotomy syndrome was considered and naproxen sodium as an anti-inflammatory agent was prescribed. Blood cultures were negative. The patient was transferred to the Department of Pediatric's and her treatment continued for 10 more days with the same antibiotic regimen until her clinical condition and laboratory values became normal.

DISCUSSION

VACTERL Association was first reported by Corcoran and Entwistle in 1975.² This non random association has a birth prevalence varying from 1:3.500 to 1.6:10.000 births.³ Babies who have been diagnosed to have VACTERL Association usually have at least three or more of these anomalies, only 1.0% of such cases present with the full range of anomalies. Our patient had a full presentation of the defined anomalies including; vertebral defects, imperforate anus, cardiac anomalies, esophageal atresia, renal defects, and limb defects.

Weaver et al. published the distribution of VACTERL Association components in 46 patients as follows; 60.4% vertebral defects, 55.9% anorectal atresia, 73.2% cardiac defects, 59.6% tracheo-oesophageal fistulae, 73.9% renal anomalies and 44.2% limb defects.³

Seventy five percent of patients with VACTERL Association have tracheomalacia at the early ages and 10-20% of these patients present with clinically important symptoms such as stridor at

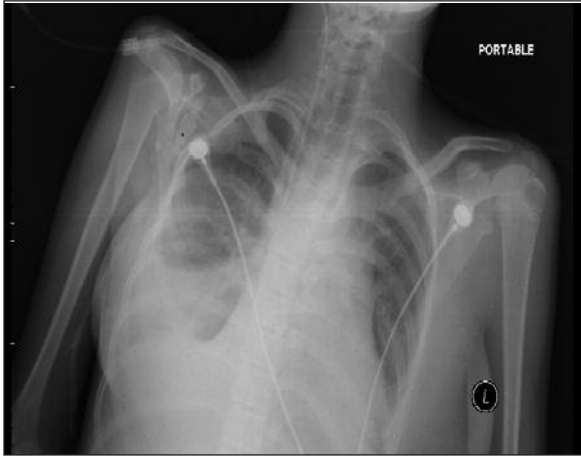


FIGURE 2: Postoperative radiography showing pneumonia and pericardial effusion.

rest, dyspnea during feeding and expiratory wheezing. Sputum retention due to impaired secretion clearance and ineffective cough can lead to tracheal mucosal metaplasia, cilia reduction, atelectasis, and recurrent pneumonia.⁴⁻⁶ Aspiration of secretions from the blind pouch of the former esophageal atresic site can also lead to infection. Pneumonia that developed postoperatively leading to a deterioration in the postoperative course of our patient might be explained with the above reasons. Hattori

et al. emphasized the tracheobronchial anomalies and reported a patient who presented with recurrent wheezing and atelectasis.⁷ Hatemi et al. forwarded postoperative lung problems after the closure of a VSD in their VACTERL patient.⁵

Postoperative lung infections in our patient's age group are not expected to accompany following a routine ASD closure. We thought that probable etiology of the lung infection was decreased cilia activity.

CONCLUSION

Although, cardiac defects in VACTERL Association are generally surgically correctable, cardiac surgeons and postoperative care givers should be aware of the tendency to infections due to the nature of this genetic disorder.

In the literature, primary treatment method of cardiac defects of VACTERL is surgery but transcatheter closure should be considered as an alternative approach in suitable cases with VACTERL Association having ASD, PDA and VSD.⁸ In our case, a transcatheter closure was not appropriate due to the presence of a large ASD.

REFERENCES

1. Khoury MJ, Cordero JF, Greenberg F, James LM, Erickson JD. A population study of the VACTERL association: evidence for its etiologic heterogeneity. *Pediatrics* 1983;71(5): 815-20.
2. Corcoran R, Entwistle GD. Letter: Polycystic ovarian disease and oral contraception. *Lancet* 1975;1(7921):1386-7.
3. Weaver DD, Mapstone CL, Yu PL. The VATER association. Analysis of 46 patients. *Am J Dis Child* 1986;140(3):225-9.
4. Günel E, Abasıyanık A, Gündoğan AH, Çağlayan F. [VACTERL syndrome (report of four cases)]. *Türkiye Klinikleri J Pediatr* 1997;6(3):132-8.
5. Hatemi AC, GURSOY M, CEVİKER K, TONGUT A, CETİN G, CELEBİ S, et al. Ventricular septal defect closure in a patient with VACTERL syndrome: anticipating sequelae in a rare genetic disorder. *Tex Heart Inst J* 2008;35(2):203-5.
6. Delius RE, Wheatley MJ, Coran AG. Etiology and management of respiratory complications after repair of esophageal atresia with tracheoesophageal fistula. *Surgery* 1992;112(3): 527-32.
7. Hattori H, Okazaki S, Higuchi Y, Yoshiyoshi M, Yamamoto T. Ectopic bronchus: an insufficiently recognized malformation causing respiratory morbidity in VATER association. *Am J Med Genet* 1999;82(2): 140-2.
8. Zaqout M, Suys B, De Wilde H, De Wolf D. Transthoracic echocardiography guidance of transcatheter atrial septal defect closure in children. *Pediatr Cardiol* 2009;30(7):992-4.