

# Correlations Between Fundus Autofluorescence and Spectral-Domain Optical Coherence Tomography Measures in Patients with Diabetic Macular Edema

## Diyabetik Makula Ödemi Olgularında Fundus Otofloresans ile Spektral Optik Koherens Tomografi Bulguları Arasındaki İlişki

Elif AKSOY GÜZELLER,<sup>a</sup>  
Faruk ÖZTÜRK,<sup>b</sup>  
Emrullah BEYAZILDIZ,<sup>c</sup>  
Mehmet Hakan TIRHIŞ<sup>d</sup>

<sup>a</sup>Clinic of Ophthalmology,  
Tokat State Hospital, Tokat

<sup>b</sup>Clinic of Ophthalmology,  
Atatürk Research and Training Hospital,  
Ankara

<sup>c</sup>Clinic of Ophthalmology,  
Samsun Research and Training Hospital,  
Samsun

<sup>d</sup>Clinic of Ophthalmology,  
Ulucanlar Research and Training Hospital,  
Ankara

Geliş Tarihi/Received: 11.10.2015

Kabul Tarihi/Accepted: 03.02.2016

Yazışma Adresi/Correspondence:

Emrullah BEYAZILDIZ  
Samsun Research and Training Hospital,  
Clinic of Ophthalmology, Samsun,  
TÜRKİYE/TURKEY  
dremrullah@hotmail.com

**ABSTRACT Objective:** The aim of this study was to investigate the correlation between short-wave fundus autofluorescence (FAF) and spectral-domain optical coherence tomography (SD-OCT) measures in patients with diabetic cystoid macular edema. **Material and Methods:** FAF and SD-OCT measurements were recorded from 123 eyes of 84 patients. The patients were grouped and compared according to their FAF grades as follows: grade 1 (group 1, n=27), grade 2 (group 2, n=27), grade 3 (group 3, n=32), and grade 4 (group 4, n=37). FAF graded manually by single grader. The groups were compared in terms of OCT findings (central macular thickness (CMT), total macular volume (TMV), and IS/OS band integrity) with FAF type (single lobule, multi-lobular or mixed) and FAF grade. **Results:** Group 1 and 2 patients primarily had single lobule FAF patterns, and groups 3 and 4 had multi-lobular and mixed FAF patterns (p<0.001). Difference between FAF grade and central macular thickness and inner and outer segment (IS/OS) band disruption were statistically significant (p<0.001). IS/OS band disruption was primarily observed in patients with multi-lobular and mixed FAF patterns (p<0.041). **Conclusion:** Increased FAF grade and a mixed FAF pattern have statistically significant relation with the IS/OS band disruption ratio.

**Key Words:** Tomography, optical coherence; macular edema; diabetes mellitus

**ÖZET Amaç:** Bu çalışmanın amacı diyabetik kistoid makula ödemi olgularında kısa dalga boyulu fundus otofloresans (FAF) ile spektral optik koherens tomografi (SD-OCT) bulguları arasındaki ilişkiyi saptamaktır. **Gereç ve Yöntemler:** Seksen dört olgunun 123 gözü çalışmaya dahil edilerek FAF ve OCT ölçümleri kaydedildi. Olgular FAF derecesine göre evre 1 (grup 1, n=27), evre 2 (grup 2, n=27), evre 3 (grup 3, n=32) ve evre 4 (grup 4, n=37) olarak dört gruba ayrıldı. FAF evrelemesi manuel olarak tek kişi tarafından yapıldı. Bu gruplar ve FAF paternleri (multi-lobuler, mikst ve tek-lobül) OCT bulguları (Santral maküler kalınlık, Total maküler kalınlık ve IS/OS bant düzensizliği) ile karşılaştırıldı. **Bulgular:** Grup 1 ve 2 olguları sıklıkla tek lobül FAF paternine sahiplerken grup 3 ve 4 olguları sıklıkla multi-lobüler ve mikst FAF paternine sahip idi (p<0,001). Santral makula kalınlığı ve iç-dış segment (IS/OS) bant bütünlüğü bozukluğu ile FAF evresi arasında anlamlı ilişki mevcuttu (p<0,001). IS/OS bant bozukluğu primer olarak multi-lobüler ve mikst FAF paternine sahip olgularda izlendi (p<0,041). **Sonuç:** Artmış FAF evresi ile mikst FAF paterni, IS/OS bütünlüğü bozukluğu arasında anlamlı ilişki mevcuttu.

**Anahtar Kelimeler:** Tomografi, optik koherens; makula ödemi; diabetes mellitus

Türkiye Klinikleri J Ophthalmol 2016;25(2):105-11

**D** iabetes mellitus (DM) is a serious disorder that affects nearly 350 million individuals worldwide.<sup>1</sup> Visual impairment in diabetic patients is primarily due to diabetic macular edema (DME), which is defined as the accumulation of fluid in or under the macula of the retina.<sup>2,3</sup> Diagnoses of DME can be made by biomicroscopic examination and fluo-

rescein angiography (FA). However, optical coherence tomography (OCT) is the most frequently used diagnostic test for DME in daily ophthalmologic practice. OCT is a noninvasive, noncontact diagnostic method. It is well tolerated by patients and uses light waves to take cross-sectional images of retinal structures to provide important information about the anatomic layers of the retina and quantitative measurements of retinal thickness.<sup>4</sup> Fundus autofluorescence (FAF) imaging is a novel imaging technique that can be used, along with other diagnostic tools, to track various retinal pathologies.<sup>5-7</sup> FAF is derived mainly from lipofuscin, a waste byproduct of phagocytosed photoreceptor outer segments, which accumulate in the retinal pigment epithelium (RPE) and autofluoresces between 500 and 750 nm (the peak emission is at 630 nm).<sup>8</sup> FAF is a rapid, noninvasive imaging method with 69% specificity and 81% sensitivity for cystoid macular edema (ME).<sup>9</sup> There are currently only a few studies that have correlated OCT findings with FAF characteristics in DME. Therefore, the aim of the current study was to investigate the relationships between FAF and spectral domain optical coherence tomography (SD-OCT) findings in patients with diagnoses of DME.

## MATERIAL AND METHODS

One hundred twenty-three eyes of 84 patients with diagnoses of DME were included in this study and were followed at the Retina unit of the Ulucanlar Eye Training and Research Hospital. Complete ophthalmologic examinations were performed on all patients. The best corrected visual acuity (BCVA) was measured, and OCT and short-wave length FAF were conducted. Patients with corneal leukoma, cataract, vitreous hemorrhage, senile macular degeneration, a history of uveitis, vitreomacular traction, glaucoma, or areas of intense, hard exudate in the foveal region were not included the study. FAF imaging was performed using a confocal scanning laser ophthalmoscope (cSLO, Heidelberg Retina Angiograph 2, Heidelberg, Germany), and the patients were grouped according to hyperautofluorescence (hyperaf) measurements of the total area (1.5 mm diameter)

on 5° manually of FAF results. Patients with <25% total hyperaf area were placed in group 1 (n = 27), patients with 50% to 25% total hyperaf area were placed in group 2 (n = 27), patients with 50% to 75% total hyperaf area were placed in group 3 (n = 32), and patients with >75% total hyperaf area were placed in group 4 (n = 37). The patients were also evaluated according to the FAF type (single lobule, multi-lobular or mixed). OCT was measured with the aid of Heidelberg Spectralis HRA + OCT (software version 5.4.6). The groups were compared in terms of OCT findings (central macular thickness (CMT), total macular volume (TMV), and IS/OS band integrity), FAF type (single lobule, multi-lobular or mixed), and visual acuity. Grading of results and evaluation of results was not blinded and results were evaluated by single grader.

## STATISTICAL ANALYSIS

The data analyses were performed using the SPSS for Windows 11.5 package program. Continuous variables were evaluated with the nonparametric Kruskal-Wallis, Conover's multiple comparison. Nominal variables were evaluated with Pearson's chi-square or Fisher's exact chi-square tests.  $p < 0.05$  was considered statistically significant.

## RESULTS

There were no significant differences between the groups in terms of age or gender distribution ( $p > 0.05$ , see Table 1). The mean visual acuities were  $0.22 \pm 0.13$  logMAR (range: 0.05 to 0.7) in the group 1 patients,  $0.40 \pm 0.19$  (range: 0.05 to 1.0) in the group 2 patients,  $0.68 \pm 0.24$  (range: 0.3 to 1.3) in the group 3 patients, and  $1.05 \pm 0.29$  logMAR (range: 0.4-1.8) in the group 4 patients. Statistically significant differences in VA were detected between the groups ( $p < 0.001$ ). These results suggested a negative correlation between VA and FAF grade.

We next categorized the FAF patterns within each group of patients. For the patients in group 1, 20 (74%) had one lobule, and 7 (26%) had multiple lobules (the mixed type was not observed). For the patients in group 2, 8 (29.6%) had one lobule, 15 (56%) had multiple lobules, and 4 (14.8%) had mixed type lobules. In the group 3 patients, 7

**TABLE 1:** Patient demographic characteristics.

|               | Group 1   | Group 2   | Group 3   | Group 4   | P      |
|---------------|-----------|-----------|-----------|-----------|--------|
| Age (year)    | 64.2      | 64.1      | 63.3      | 61.3      | >0.05  |
| BCVA (logMAR) | 0.22±0.13 | 0.40±0.19 | 0.68±0.24 | 1.05±0.29 | <0.001 |
| Gender, n (%) |           |           |           |           |        |
| Female        | 16 (59.3) | 15 (55.6) | 19 (59.4) | 20 (54.1) | >0.05  |
| Male          | 11 (40.7) | 12 (44.4) | 13 (40.6) | 17 (45.9) |        |

BCVA : Best corrected visual acuity.

(21.9%) had one lobule, 15 (46.9%) had multiple lobules, and 10 (31.2%) had mixed type lobules. Lastly, in the group 4 patients, 5 (13.5%) had one lobule, 17 (46%) had multiple lobules, and 15 (40.5%) had mixed type lobules. These results suggest that single lobule FAFs were more likely to be observed among the patients of groups 1 and 2 and that mixed and multiple lobule FAFs were most often observed groups 3 and 4 ( $p < 0.001$ , Table 2 and Figure 1).

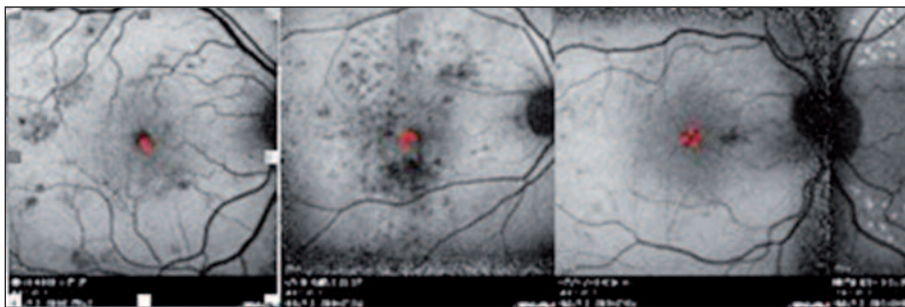
Spectral-domain optical coherence tomography (SD-OCT) was utilized to measure central macular thickness, total macular volume, and inner and outer photoreceptor segment (IS/OS) integrities in each patient, which were then compared across the groups. The average CMT was  $301.03 \pm 32.27 \mu\text{m}$  (range: 240-389  $\mu\text{m}$ ) in group 1,  $365.55 \pm 69.89 \mu\text{m}$  (range: 240-559  $\mu\text{m}$ ) in group 2,  $479.18 \pm 102.46 \mu\text{m}$  (range: 312-707  $\mu\text{m}$ ) on group 3, and  $597.29 \pm 140.97 \mu\text{m}$  (range: 334-964  $\mu\text{m}$ ) in group 4. The average TMV was  $3.26 \pm 0.27 \text{ mm}^3$  (range: 2.85 to 4.15  $\text{mm}^3$ ) in group 1,  $3.58 \pm 0.44 \text{ mm}^3$  (range: 3.06 to 4.76  $\text{mm}^3$ ) in group 2,  $4.22 \pm 1.28 \text{ mm}^3$  (range: 3.00 to 10.62  $\text{mm}^3$ ) in group 3,

**TABLE 2:** Comparison of the groups based on FAF classification.

|         | One lobule | Multi-lobule | Mix |
|---------|------------|--------------|-----|
| Group 1 | 20         | 7            | 0   |
| Group 2 | 8          | 15           | 4   |
| Group 3 | 7          | 15           | 10  |
| Group 4 | 5          | 17           | 15  |
| P<0.001 |            |              |     |

and  $5.07 \pm 1.46 \text{ mm}^3$  (range: 3.40 to 11.73  $\text{mm}^3$ ) in group 4. IS/OS band disruptions were detected in 2 patients in group 1 (7.5%), 5 patients in group 2 (18.6%), 14 patients in group 3 (43.8%), and 26 patients in group 4 (70.3%). There were significant differences in CMT, TMV and IS/OS band integrity between the groups ( $p < 0.001$ , Table 3). In addition to CMT, TMV and IS/OS band distortion appeared to be positively correlated with FAF (Figure 2).

We lastly sought to correlate our SD-OCT findings with the FAF patterns observed in each patient. The FAF results were therefore used to divide patients into three populations: i.e., a single lobule group, a multiple lobule group, and a mixed

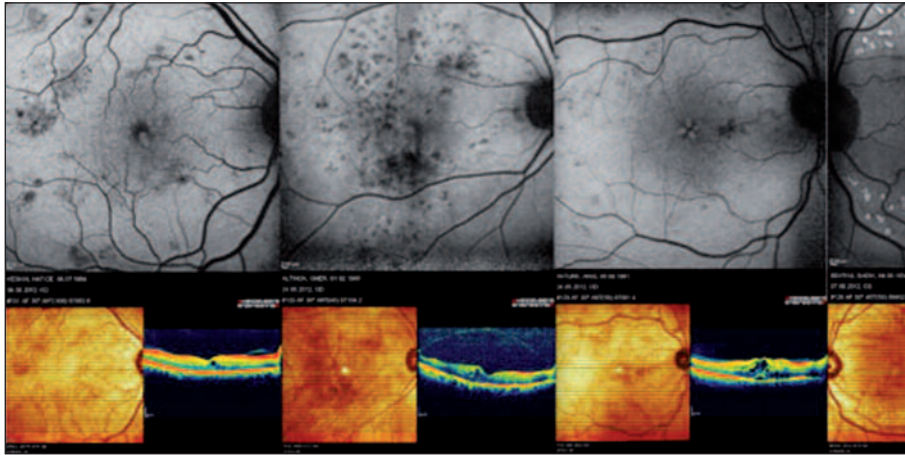
**FIGURE 1:** Representative images for the FAF grades of the patients. Grade 1, Grade 2, Grade 3 and Grade 4 (from left to right).

(See color figure at <http://www.turkiyeklinikleri.com/journal/oftalmoloji-dergisi/1300-0365/>)

**TABLE 3:** Comparison of groups based on SD-OCT analysis.

|                           | Group 1 | Group 2  | Group 3   | Group 4   | P      |
|---------------------------|---------|----------|-----------|-----------|--------|
| CMT, $\mu\text{m}$        | 301     | 365      | 479       | 597       | <0.001 |
| TMV, $\text{mm}^3$        | 3.26    | 3.58     | 4.22      | 5.07      | <0.001 |
| IS/OS band distortion (%) | 2 (7.5) | 5 (18.6) | 14 (43.8) | 26 (70.3) | <0.001 |

CMT: Central Macula Thickness; TMV: Total Macular Volume.

**FIGURE 2:** Corresponding FAF and OCT images of the patients.

(See color figure at <http://www.turkiyeklinikleri.com/journal/oftalmoloji-dergisi/1300-0365/>)

type lobule group. The average CMTs were  $388.25 \pm 149.20 \mu\text{m}$  (245-823  $\mu\text{m}$ ) among the single lobule patients,  $466.77 \pm 143.18 \mu\text{m}$  (240-860  $\mu\text{m}$ ) among the multiple lobule group, and  $506.75 \pm 146.48 \mu\text{m}$  (312-964  $\mu\text{m}$ ) among the mixed type group. The average TMVs were  $3.77 \pm 0.94 \text{ mm}^3$  (2.85 to 7.34  $\text{mm}^3$ ) in the single lobule group,  $4.21 \pm 1.21 \text{ mm}^3$  (3.00 to 10.62  $\text{mm}^3$ ) in the multiple lobule patients, and  $4.46 \pm 1.63 \text{ mm}^3$  (3.09 to 11.73  $\text{mm}^3$ ) in the mixed type group. Average visual acuity (VA) was  $0.45 \pm 0.38 \text{ logMAR}$  in the single lobule patients,  $0.66 \pm 0.37 \text{ logMAR}$  in the multiple lobule group, and  $0.81 \pm 0.36 \text{ logMAR}$  in the mixed type patients. We found significant differences in the average

CMTs, Vs and VAs in the patients with a single lobule compared to the patients with multiple lobules or mixed type FAFs ( $p < 0.001$ ,  $p < 0.005$ , and  $p < 0.005$ , respectively). There was no significant difference in CMT, V, or VA between the multi-lobule and mixed type patients ( $p = 0.200$ ,  $p = 0.389$ , and  $p = 0.065$ , respectively, Table 4).

IS/OS band disruption was detected in 11 single lobule patients (27.5%), 21 multiple lobule patients (50%), and 15 mixed type patients (51.7%). Multi-lobular and mixed type FAFs were detected more often in patients with IS/OS band disruptions than in the patients with single lobule FAFs ( $p < 0.041$ ).

**TABLE 4:** Comparison of SD-OCT data based on patients' FAF pattern.

|                              | One lobule                    | Multi-Lobule                  | Mix                           | P      |
|------------------------------|-------------------------------|-------------------------------|-------------------------------|--------|
| CMT, $\mu\text{m}$           | $388.25 \pm 149.20$ (245-823) | $466.77 \pm 143.18$ (240-860) | $506.75 \pm 146.48$ (312-964) | <0.001 |
| TMV, $\text{mm}^3$           | $3.77 \pm 0.94$ (2.85-7.34)   | $4.21 \pm 1.21$ (3.00-10.62)  | $4.46 \pm 1.63$ (3.09-11.73)  | 0.005  |
| IS/OS band disruption, n (%) | 11 (27.5)                     | 21 (50)                       | 15 (51.7)                     | 0.041  |
| BCVA, logMAR                 | 0.5                           | 0.7                           | 0.8                           | <0.001 |

CMT: Central Macula Thickness; TMV: Total Macular Volume; BCVA: Best corrected visual acuity.



## DISCUSSION

The results of our study suggest that FAF and SD-OCT measurements are significantly correlated in patients with DME. We found that increased FAF grade was positively correlated with IS/OS band disruption and that increased CMT was positively correlated with total macular volume. We observed that patients with mixed type FAF patterns exhibited the greatest IS/OS band disruptions and the highest TMV and CMT levels. In contrast, in the patients with single lobule FAF patterns, we observed the lowest percentage of IS/OS band disruption and the lowest levels of TMV and CMT.

The most common cause of vision loss in patients with DME is macular edema.<sup>2</sup> Fluorescein angiography (FA) and OCT are two of the main methods used in the diagnosis of DME.<sup>10</sup> OCT provides information regarding the localization of the macular edema and the interface with the vitreoretinal morphology.<sup>4</sup> OCT can also provide quantitative measurements, including central foveal thickness and macular volume.<sup>4</sup> FA is an invasive procedure and can thus cause technical complications.<sup>4</sup> While macular perfusion and dynamic leakage can be shown with FA, detailed morphological information like that provided by OCT is unobtainable.<sup>11</sup> Additionally, FA is a subjective, qualitative and time-consuming method. Good correlations between diagnoses made with OCT and FA have been reported in previous studies, which suggests that both methods can be used to diagnose DME.<sup>11</sup> FAF is a diagnostic procedure that was introduced recently and can be a useful diagnostic tool for many retinal diseases such as macular degeneration, macular dystrophy and macular edema. However, the correlation between OCT measurements and FAF patterns is currently a controversial issue in this field.<sup>11-13</sup> FAF is known to be helpful in the diagnosis of diseases in which lipofuscin and other fluorophores accumulate in RPE cells.<sup>5-7</sup> Studies are also available that suggest FAF might be used in the diagnosis of macular edema.<sup>9,14,15</sup>

McBain et al. evaluated 34 patients who developed ME and determined that, when compared with FAF, FA has an 81% sensitivity and a 69% speci-

ficity.<sup>9</sup> It has also been reported that, based on FA values, all patients with fluoride permanent macula edema (PME) could be identified with FAF. Bessho et al. studied 3 cases of diabetic ME and 11 cases of ME due to central retinal vein occlusion and detected petaloid patterns in the FAFs that were analogous to images acquired with FA.<sup>16</sup> In a study by Dinc et al., diagnoses of ME with FAF were confirmed in most of the patients, and the areas with dark septa within the petaloid leakage on FA were shown as decreased autofluorescence image areas on FAF.<sup>17</sup> Lipofuscin involves the intense peroxidation of both lipids and proteins.<sup>18</sup> Thus, it is thought that lipofuscin can be used as a surrogate measure for oxidative damage in the retina. A recent study found that lipofuscin accumulates in the RPE and microglia.<sup>18</sup> Increased microglia activity is a known condition in diabetes.<sup>19</sup> It is possible that the hyperautofluorescent areas observed on FAF in DME patients might be due to increased levels of oxidative substances in the microglia.

Peca et al. identified three main patterns associated with cystoid macular edema in diabetes: lobular, multilobulated and mixed.<sup>20</sup> In our study, similar FAF patterns were observed. As we found here, Peca et al. found that multi-lobule FAF patterns were most common in patients with ME due to diabetes. In their study, there were no significant differences in CMT between FAF groups.<sup>20</sup> We found that single lobule FAF patients had significantly lower CMT values but did not find differences between the other groups. TMV was also lower in the single lobule patients in our study. Pece et al. found reduced visual acuity in single lobule patients compared to multiple lobule patients.<sup>20</sup> Our results are consistent with this finding. Vujosevic et al. divided pathological FAFs into two types: single-spot and multi-spot.<sup>12</sup> In their study, the mean visual acuity was significantly greater in patients with single-spots than in those with multi-spots. These authors found no significant differences in average macular volume or mean CMT.

The mechanical effects generated by cysts might be another factor that influences the increased FAF observed in DMO patients. Cysts are

generally more localized to the inner nuclear layer and outer plexiform, such as luteal pigments, and can cause lateralized luteal pigments.<sup>9</sup> Thus, cysts can produce a blocking effect of the luteal pigments by eliminating the absorption of blue light in the fovea.

Bessho et al. detected hyperfluorescence at 488 nm but not at 580 nm in the ME and therefore defined the images as pseudo-hyperautofluorescent.<sup>16</sup> The increased FAF was not due to accumulation of lipofuscin and was linked to increased visibility on RPE due to window defects in FA.<sup>9</sup> Chung et al. demonstrated increased hyperfluorescence in diabetic patients with ME.<sup>14</sup> Our study also confirms these findings. Significant relationships were found between decreases in visual acuity and IS/OS band disruption with increased FAF grade. Mixed and multi-lobular FAF patterns were found more frequently in patients who exhibited IS/OS band damage. Pece et al. showed reduced visual acuity in patients with increased FAF and DME.<sup>20</sup> Additionally, Vujosevic et al. showed significant relationships between functional and morphological disorders of the macula and increased FAF.<sup>12</sup> Significant relationships were found between increased FAF in the retinal area and decreased

retinal sensitivity.<sup>12</sup> Our current study found that increased FAF might be useful as a prognostic marker that reveals IS/OS band integrity and visual acuity and that FAF patterns might be an important diagnostic tool for patients with DME. Currently, FAF is not used as standard diagnostic method for retinal pigment epithelium diseases. The FAF method could also be utilized in unexplained or unresolved cases with macular disease and for patients with DME.

Characteristics of FAF may help to evaluate the extent of retinal injury however information about retinal architecture and integrity is limited, so FAF rarely used alone for the diagnosis of DME.

In the current study, a greater incidence of IS/OS band disruption was observed among patients with mixed type FAF patterns, and a lower incidence was observed in patients with single lobules. Greater macular thickness and lower visual acuity were primarily related to the mixed type FAF pattern. FAF degree and the total area of hyperfluorescence might be used as prognostic tools for visual acuity and IS/OS integrity. Therefore, FAF is a promising method than can be utilized in patients with diabetic macular edema and other retinal diseases.

## REFERENCES

1. Danaei G, Finucane MM, Lu Y, Singh GM, Cowan MJ, Paciorek GJ, et al; Global Burden of Metabolic Risk Factors of Chronic Diseases Collaborating Group (Blood Glucose). National, regional, and global trends in fasting plasma glucose and diabetes prevalence since 1980: systematic analysis of health examination surveys and epidemiological studies with 370 country-years and 2.7 million participants. *Lancet* 2011;378(9785):31-40.
2. Antcliff RJ, Marshall J. The pathogenesis of edema in diabetic maculopathy. *Semin Ophthalmol* 1999;14(4):223-32.
3. Arend O, Remky A, Harris A, Bertram B, Reim M, Wolf S. Macular microcirculation in cystoid maculopathy of diabetic patients. *Br J Ophthalmol* 1995;79(7):628-32.
4. Wojtkowski M, Srinivasan V, Fujimoto JG, Ko T, Schuman JS, Kowalczyk A, et al. Three-dimensional retinal imaging with high-speed ultrahigh-resolution optical coherence tomography. *Ophthalmology* 2005;112(10):1734-46.
5. Spaide RF, Klancnik JM Jr. Fundus autofluorescence and central serous chorioretinopathy. *Ophthalmology* 2005;112(5):825-33.
6. Teke MY, Elgin U, Ozdal P, Ozturk F. Autofluorescence and optical coherence tomography findings in optic disc pit-associated maculopathy: case series. *Int Ophthalmol* 2011;31(6):485-91.
7. Holz FG, Bellman C, Staudt S, Schütt F, Völcker HE. Fundus autofluorescence and development of geographic atrophy in age-related macular degeneration. *Invest Ophthalmol Vis Sci* 2001;42(5):1051-6.
8. Weinberger AW, Lappas A, Kirschkamp T, Maziani BA, Huth JK, Mohammadi B, et al. Fundus near infrared fluorescence correlates with fundus near infrared reflectance. *Invest Ophthalmol Vis Sci* 2006;47(7):3098-108.
9. McBain VA, Forrester JV, Lois N. Fundus autofluorescence in the diagnosis of cystoid macular oedema. *Br J Ophthalmol* 2008;92(7):946-9.
10. Wu L, Fernandez-Loaiza P, Sauma J, Hernandez-Bogantes E, Masis M. Classification of diabetic retinopathy and diabetic macular edema. *World J Diabetes* 2013;4(6):290-4.
11. Kang SW, Park CY, Ham DI. The correlation between fluorescein angiographic and optical coherence tomographic features in clinically significant diabetic macular edema. *Am J Ophthalmol* 2004;137(2):313-22.
12. Vujosevic S, Casciano M, Pilotto E, Boccassini B, Varano M, Midena E. Diabetic macular edema: fundus autofluorescence and functional correlations. *Invest Ophthalmol Vis Sci* 2011;52(1):442-8.

13. Shen Y, Xu X, Liu K. Fundus autofluorescence characteristics in patients with diabetic macular edema. *Chin Med J (Engl)* 2014;127(8):1423-8.
14. Chung H, Park B, Shin HJ, Kim HC. Correlation of fundus autofluorescence with spectral-domain optical coherence tomography and vision in diabetic macular edema. *Ophthalmology* 2012;119(5):1056-65.
15. Peng XJ, Su LP. Characteristics of fundus autofluorescence in cystoid macular edema. *Chin Med J (Engl)* 2011;124(2):253-7.
16. Bessho K, Gomi F, Harino S, Sawa M, Sayanagi K, Tsujikawa M, et al. Macular autofluorescence in eyes with cystoid macula edema, detected with 488 nm-excitation but not with 580 nm-excitation. *Graefes Arch Clin Exp Ophthalmol* 2009;247(6):729-34.
17. Dinç UA, Tatlıpınar S, Yenerel M, Görgün E, Çiftçi F. Fundus autofluorescence in cystoid macular edema: can it be an ancillary test? *Ret-Vit* 2010;18(1):12-7.
18. Schmitz-Valckenberg S, Holz FG, Bird AC, Spaide RF. Fundus autofluorescence imaging: review and perspectives. *Retina* 2008 Mar;28(3):385-409.
19. Xu H, Chen M, Manivannan A, Lois N, Forrester JV. Age-dependent accumulation of lipofuscin in perivascular and subretinal microglia in experimental mice. *Aging Cell* 2008;7(1):58-68.
20. Pece A, Isola V, Holz F, Milani P, Brancato R. Autofluorescence imaging of cystoid macular edema in diabetic retinopathy. *Ophthalmologica* 2010;224(4):230-5.