

Solitary Metastasis to the Contralateral Adrenal Gland After Radical Nephrectomy for Renal Cell Carcinoma: Report of a New Case

Renal Hücreli Kanserde Radikal Nefrektomi Son- rası Kontralateral Adrenal Metastaz: Yeni Bir Olgu Sunumu

Nurettin Cem SÖNMEZ, MD,^a
Soner GÜNEY, MD,^a
Serdar ARISAN, MD,^a
Murat Can KİREMİT, MD^a

^aDepartment of 1st Urology,
Şişli Etfal Research and
Training Hospital, İstanbul

Geliş Tarihi/Received: 13.11.2008
Kabul Tarihi/Accepted: 27.04.2009

Yazışma Adresi/Correspondence:
Nurettin Cem SÖNMEZ, MD
Şişli Etfal Research and
Training Hospital,
Department of 1st Urology, İstanbul,
TÜRKİYE/TURKEY
urologturk@yahoo.com

ABSTRACT Renal cell carcinoma (RCC) frequently presents with distant metastasis. Distant metastatic disease occurs in approximately 30% of the patients in RCC by the initial diagnosis. The most common sites for metastases of RCC are the lung, liver, bone, lymph node, contralateral kidney and to a lesser extent, the adrenal gland. Adrenal metastasis is frequently silent in the clinical conditions. Malignant involvement of the ipsilateral adrenal gland occurs in approximately 2-10% of cases. Solitary metachronous metastatic involvement of the contralateral adrenal gland from RCC is rarely diagnosed during life. Clinical signs and symptoms of adrenal insufficiency are rare in these patients. Metastectomy is advocated and probably beneficial for limited metastatic renal cell cancer. Adrenalectomy is the treatment modality of almost every metachronous contralateral adrenal metastases in the literature. We report a case of RCC with solitary contralateral adrenal metastasis which was demonstrated 6 months after radical nephrectomy. This case is one of the earliest contralateral adrenal metastasis after radical nephrectomy in the literature. The patient was treated with contralateral adrenalectomy. The patient died of brain metastasis, six months after adrenalectomy.

Key Words: Renal cell carcinoma, adrenal gland neoplasm, kidney neoplasms, neoplasm metastasis

ÖZET Renal hücreli kanser (RHK) sıklıkla uzak metastazla görülür. İlk tanı sırasında, RHK'li hastaların yaklaşık üçte birinde uzak metastatik hastalığa rastlanır. RHK'nin en sık metastaz yaptığı yerler; akciğer, karaciğer, kemik, lenf nodları, kontralateral böbrek ve daha az olarak adrenal bezdir. Adrenal metastaz sıklıkla klinik ve fonksiyonel olarak sessiz seyreder. Olguların yaklaşık %2-10'unda ipsilateral adrenal bezin malign tutulumuna rastlanır. RHK'de, kontralateral adrenal bezin soliter metakranöz metastatik tutulumuna çok seyrek olarak rastlanır. Bu hastalarda adrenal yetmezliğin klinik belirti ve semptomları çok azdır. Metastektomi tavsiye edilir ve muhtemelen sınırlı metastatik RHK'de faydalıdır. Literatürde hemen her metakranöz kontralateral adrenal metastaz olgusunda tedavi modalitesi adrenalectomidir. Biz burada, radikal nefrektomiden altı ay sonra görülen RHK'nin soliter kontralateral adrenal metastazı olgusu yayınıyoruz. Bu, literatürde radikal nefrektomi sonrası en erken görülen kontralateral adrenal metastaz olgularından biridir. Hasta kontralateral adrenalectomi ile tedavi edildi. Hasta adrenalectomiden altı ay sonra beyin metastazı nedeni ile kaybedildi.

Anahtar Kelimeler: Renal hücreli karsinom, böbrek neoplazmları; adrenal bez metastazı, neoplazm metastazı

Türkiye Klinikleri J Nephrol 2009;4(2):86-9

Renal cell carcinoma (RCC) frequently presents with distant metastasis. Distant metastatic disease occurs in approximately 30% of the patients in renal cell carcinoma by the initial diagnosis. The most common sites for metastases of RCC are; the lung, liver, bone, lymph node,

contralateral kidney and to a lesser extent, the adrenal gland.¹ Malignant involvement of the ipsilateral adrenal gland occurs in approximately 2 -10% of cases. Contralateral adrenal involvement by RCC is uncommon and may be synchronous or metachronous to the primary renal tumor. Almost all of these metastatic lesions in the literature were smaller than the primary RCC tumor.^{1,2} Here, we present a case of renal cell carcinoma with solitary contralateral adrenal metastasis which was demonstrated 6 months after radical nephrectomy that was treated surgically.

CASE REPORT

A 48-year-old male with 60 pack/year history of cigarette smoking was admitted with macroscopic hematuria and left flank pain. Computerized Tomography (CT) revealed a nonhomogenous 8 x 6 x 7 cm solid mass in the upper and middle pole of the left kidney (Figure 1). The left renal vein and vena cava inferior was found to be patent. Physical examination was normal. Anemia was detected and corrected by transfusion, preoperatively. Serum blood urea nitrogen, creatinine, cortisol were within normal limits while alkaline phosphatase and ferritin were elevated. A bone scan and chest radiographs revealed no metastasis. Via a left thoracoabdominal approach, left radical nephrectomy was performed and as the tumor was located at the upper pole of the left kidney, left adrenalectomy was also performed. The patholo-

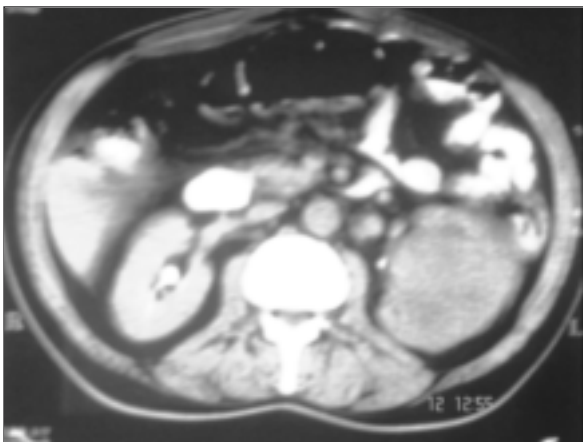


FIGURE 1: Nonhomogenous 8 x 6 x 7 cm solid mass in the upper and middle pole of the left kidney.

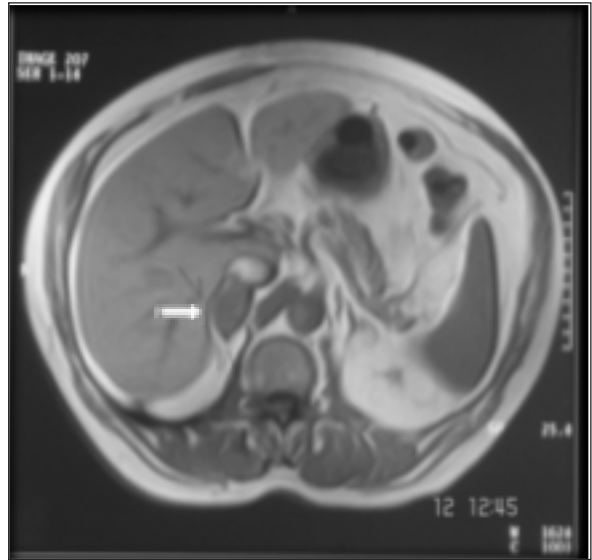


FIGURE 2: 2 cm diameter right adrenal mass.

gical examination showed a clear cell type renal cell carcinoma with sarcomatoid differentiation. Nuclear grade was 3 and the tumor was encapsulated. The largest diameter of the tumor was 14 cm and no renal vein invasion was detected. No tumor was detected in surgical margins or in renal nodes. 30 x 20 mm solid mass in the upper half of the right surrenal gland was detected in abdominopelvic CT for routine evaluation of metastasis, 6 months after radical nephrectomy. A tru-cut biopsy by magnetic resonance imaging was performed and in pathological examination, strong staining with cyokeratin and EMA and metastasis of RCC was shown (Figure 2). Right adrenalectomy was performed and pathologically the tumor was identical to the left renal cell carcinoma. Six months after adrenalectomy, brain metastasis was detected. Three months after the diagnosis, the patient died.

DISCUSSION

Distant metastatic disease occurs in approximately a third of the patients in renal cell carcinoma by the initial diagnosis.³ The most common sites for metastases of RRC are the lung, liver, bone, lymph node, contralateral kidney and to a lesser extent, the adrenal gland.¹ Adrenal metastasis frequently being clinically and functionally silent, it is really

hard to detect in the routine follow-up cases without abdominal visualization procedures.⁴

At autopsy, ipsilateral and contralateral adrenal metastasis of renal cell carcinoma revealed in 17% and 11% respectively.⁵ The risk of ipsilateral adrenal metastasis is correlated to advanced T stage tumor of the upper pole, but the risk factors for contralateral involvement are not known. A solitary contralateral adrenal metastasis of RCC is thought to occur via the hematogenous route as other organ metastases and adrenal gland is suggested to have a higher affinity for the spread of RCC than other organs. Contralateral adrenal metastasis suggests that the adrenal is a fertile soil conducive to the dissemination of renal cell carcinoma.⁶

Solitary metachronous contralateral adrenal metastasis from a renal carcinoma are very uncommon and may be detected after the primary renal tumor and should be treated with aggressive surgical approach.⁷ Surgical removal of metastatic adrenal gland was performed in 55 cases in the literature. The mean duration time from radical nephrectomy to detection of the metachronous adrenal metastasis was 49.8 months (range 6 to 276 months). The mean survival time was 27.3 months (range 1 to 87 months) for metachronous adrenal metastasis. Kessler et al. reported that the prognosis was better when the interval was longer.⁸ Yamasaki et al reported no correlation between the prognosis and the interval time between radical nephrectomy and adrenal metastasis.⁹ In our case, 6 months interval might be a sign of bad prognosis. A better prognosis has been established in patients who had a solitary metastasis removed and when solitary adrenal metastasis appears more than eighteen months after radical nephrectomy.^{7,10} We have reported a case of metachronous, contralateral adrenal metastasis from renal cell carcinoma appearing 6 months after radical nephrectomy and at the time of adrenalectomy had no evidence of metastatic disease. Patient died of metastatic disease

ten months later. This is the earliest metastatic appearance and death after adrenalectomy in the literature and the metachronous contralateral adrenal metastasis was one of the shortest, occurring six months after radical nephrectomy.

Neal et al reported a case with renal cell carcinoma and synchronous solitary contralateral adrenal metastasis who survived three years after resection of primary and metastatic lesions.⁵ Previte et al. reported two cases; who survived twenty months and twentyfour months following surgery, respectively. Hasegawa et al reported two patients, one of them with pulmonary metastases six months after adrenalectomy and the other has survived twenty-two months without any evidence of the metastases.¹¹

The histological type of primary renal tumor was clear cell type in all cases with metachronous contralateral adrenal metastases in the literature and this finding implies the importance of determining histological type of primary renal tumor. The risk of metastasis in papillary and chromophobic renal cell cancer is low. Clear cell type with sarcomatoid differentiation might be a reason for early metastasis in our case.

Adrenalectomy is the treatment modality of almost every metachronous contralateral adrenal metastases' cases in the literature.¹² Recently, laparoscopic adrenalectomy for an isolated adrenal metastasis has been accepted as minimally invasive surgery.¹³ Interferon alpha and steroid replacement were used in selected cases. Since the majority of these patients will suffer from adrenal insufficiency owing to previous contralateral radical nephrectomy, adrenal steroid replacement is required.

In conclusion, solitary metachronous contralateral adrenal metastases are rarely diagnosed and may occur very early and be treated with surgical removal of the adrenal. Long-term follow-up of these patients will be necessary to evaluate new metastatic disease.

REFERENCES

1. Lau WK, Zincke H, Lohse CM, Cheville JC, Weaver AL, Blute ML. Contralateral adrenal metastasis of renal cell carcinoma: treatment, outcome and a review. *BJU Int* 2003;91(9): 775-9.
2. Kuczyk M, Wegener G, Jonas U. The therapeutic value of adrenalectomy in case of solitary metastatic spread originating from primary renal cell cancer. *Eur Urol* 2005;48(2):252-7.
3. Middleton RG. Surgery for metastatic renal cell carcinoma. *J Urol* 1967;97(6):973-7.
4. Hajdu SI, Thomas AG. Renal cell carcinoma at autopsy. *J Urol* 1967;97(6):978-82.
5. Skinner DG, Colvin RB, Vermillion CD, Pfister RC, Leadbetter WF. Diagnosis and management of renal cell carcinoma. A clinical and pathologic study of 309 cases. *Cancer* 1971;28(5):1165-77.
6. Sagalowsky AI, Kadesky KT, Ewalt DM, Kennedy TJ. Factors influencing adrenal metastasis in renal cell carcinoma. *J Urol* 1994;151(5):1181-4.
7. O'dea MJ, Zincke H, Utz DC, Bernatz PE. The treatment of renal cell carcinoma with solitary metastasis. *J Urol* 1978;120(5):540-2.
8. Kessler OJ, Mukamel E, Weinstein R, Gayer E, Konichezky M, Servadio C. Metachronous renal cell carcinoma metastasis to the contralateral adrenal gland. *Urology* 1998;51(4):539-43.
9. Yamasaki Y, Koga S, Nishikido M, Noguchi M, Kanetake H, Saito Y. The role of surgery in renal cell carcinoma with solitary metachronous metastasis to contralateral adrenal gland. *Anticancer Res* 1999;19(6C): 5575-6.
10. Huisman TK, Sands JP Jr. Renal cell carcinoma with solitary metachronous contralateral adrenal metastasis. Experience with 2 cases and review of the literature. *Urology* 1991; 38(4):364-8.
11. Hasegawa J, Okumura S, Abe H, Kanamori S, Yoshida K, Akimoto M. Renal cell carcinoma with solitary contralateral adrenal metastasis. *Urology* 1988;32(1):52-3.
12. DeLellis RA. The adrenal glands. In: Sternberg SS, ed. *Diagnostic Surgical Pathology*. 2nd ed. New York: Raven Press; 1994. p.571-98.
13. Utsumi T, Suzuki H, Nakamura K, Kim W, Kamijima S, Awa Y, et al. Renal cell carcinoma with a huge solitary metastasis to the contralateral adrenal gland: a case report. *Int J Urol* 2008;15(12):1077-9.