

# Coexistence of Coronary Artery Disease with Anomalous Origin of the Left Main Coronary Artery From the Right Coronary Artery Ostium: Case Report and Literature Review

*SOL ANA-KORONER ARTERİN SAĞ KORONER OSTİUMUNDAN ÇIKIŞI VE ATEROSKLEROTİK KORONER KALP HASTALIĞININ BİRLİKTELİĞİ: OLGU SUNUMU VE LİTERATÜR DERLEMESİ*

Mehmet KABUKÇU, MD,<sup>a</sup> Özgür AVŞAR, MD,<sup>a</sup> Kenan MİNARECİ, MD<sup>a</sup>

<sup>a</sup>Department of Cardiology, Akdeniz University, Faculty of Medicine, ANTALYA

## Abstract

Left main coronary artery arising from the right coronary ostium is a rare congenital coronary anomaly. This anomaly is either benign or serious depending on the course of the left main coronary artery. If the left main coronary artery travels between the aorta and pulmonary arteries, it may be a cause of sudden cardiac death in young males especially during or immediately after heavy physical exercise.

In this paper, a rare case with the coexistence of atherosclerotic coronary artery disease with an anomalous origin of the left main coronary artery from the right coronary artery ostium was reported and was discussed in the light of the literature.

**Key Words:** Coronary vessel anomalies, coronary arteriosclerosis

**Türkiye Klinikleri J Med Sci 2005, 25:867-870**

## Özet

Sol ana koroner arterin sağ koroner ostiumundan çıkması nadir saptanan koroner anomalilerdendir. Bu anomali, sol ana koronerin seyrine göre çeşitli şekillerde olabilmektedir. Eğer ana-koroner arter aort ve pulmoner arterler arasından seyredirse; genç erişkinlerde ağır egzersiz sonrası ani kardiyak ölümlerle seyretmektedir.

Bu olguda, nadir görülen bu sol ana koroner arterin sağ koroner arter ostiumundan anormal çıkışına aterosklerotik koroner arter hastalığı bildirilmekte ve literatür gözden geçirilmektedir.

**Anahtar Kelimeler:** Koroner anomali, koroner arter hastalığı

**C**ongenital anomalies in the origin, course or distribution of the epicardial coronary arteries are found in 1 to 2 percent of the population.<sup>1</sup> Anomalous left coronary artery arising from the right coronary ostium is a very rare congenital anomaly.<sup>2,3</sup> This anomaly is either benign or serious depending on the course of left main coronary artery.<sup>4</sup> We present a case of a 45 years old man in whom the evaluation of acute coronary syndrome revealed an anomalous origin of the left main coronary artery and occlusive

coronary artery disease. We discuss the clinical significance of this abnormality.

## Case Report

In February 2003, a 45-year-old man presented with a 12 hours onset of retrosternal chest pain at rest and tiredness. Previously there was no relevant medical history such as chest pain or shortness of breath on exertion. He had a history of smoking (20 package-years), hypertension and a family history of premature coronary artery disease. In the physical examination, the blood pressure was 112/68 mmHg, and the pulse was 92/min; he had a normal first and second heart sound and a soft S<sub>4</sub>. No murmurs were present. Electrocardiogram (ECG) revealed Q waves in D III and aVF derivations and tall R waves in V1 chest derivation. The patient was hospitalized with a diagnosis

**Geliş Tarihi/Received:** 20.04.2004 **Kabul Tarihi/Accepted:** 04.11.2004

**Yazışma Adresi/Correspondence:** Mehmet KABUKÇU, MD  
Akdeniz University, Faculty of Medicine,  
Department of Cardiology, 07070 ANTALYA  
kabukcu@akdeniz.edu.tr

Copyright © 2005 by Türkiye Klinikleri

of evolving infero-posterior myocardial infarct. Treatment with acetylsalicylic acid 300 mg/day, ticlopidine 500 mg/day, metoprolol-tartarate 100 mg/day, intravenous nitrate, atorvastatin calcium 40 mg/day and enoxaparin sodium 120 mg/day was initiated. In the follow-up no adverse event occurred with medical treatment. Coronary angiography was performed due to the patient's young age.

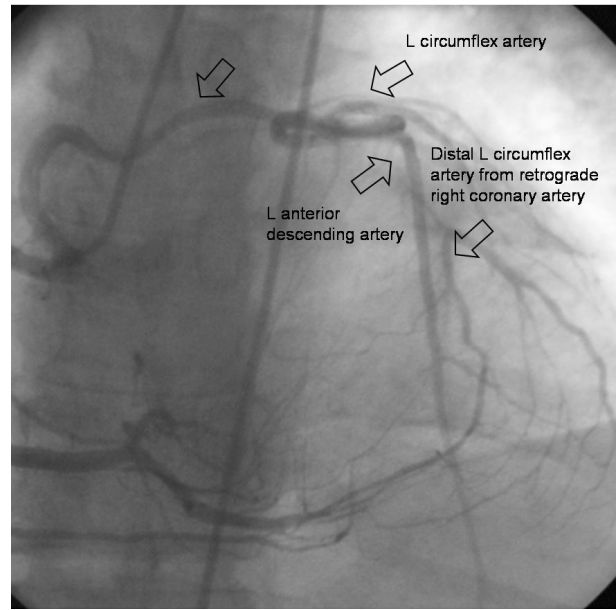
Left ventriculography revealed a normal-sized left ventricle with normal systolic function and no mitral regurgitation.

Following left ventriculography, intervention to detect left coronary artery ostium with Judkins coronary catheter in left sinus Valsalva was not successful. Right coronary artery originated from the normal anatomic position and did not have obstructive disease. The left-main coronary artery (LMCA) arose from the right coronary ostium and transversed anterior aorta (Picture 1). Left main coronary artery was selectively catheterized with internal mamarian artery catheter (Picture 2). It took a safer course at the anterior of the aorta. Left anterior descending coronary artery was in normal position and had a non-occlusive coronary artery disease. Left circumflex artery was obstructed in the middle portion. The distal left circumflex artery filled through collateral vessels from the right coronary artery.

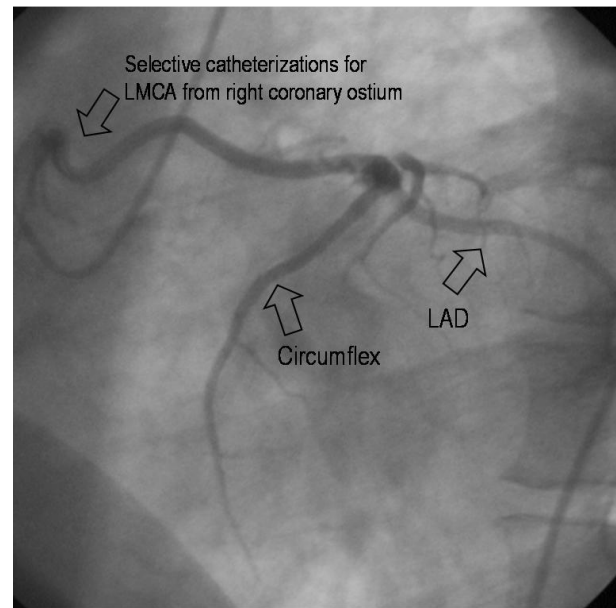
Aortic root angiography confirmed that a single coronary artery originated from the aortic trunk by a single coronary ostium. It took a safer course anterior the aorta (Picture 3).

Surgery was not performed due to the benign course of this anomaly and one vessel coronary artery disease. The patient was treated with acetylsalicylic acid 300 mg/day, metoprolol-tartarate 100 mg/day and atorvastatin calcium 40 mg/day. A subsequent Holter study revealed no arrhythmias. A treadmill exercise test revealed no angina and no ST depression with exercise. The patient experienced no episodes of chest pain since then.

Medical treatment and secondary prevention for atherosclerosis was recommended after coroner angiography, since the congenital anomaly was benign and symptoms due to coronary atheroscle-



**Resim 1.** LMCA from right coronary ostium and distal L circumflex artery from retrograde right coronary artery.

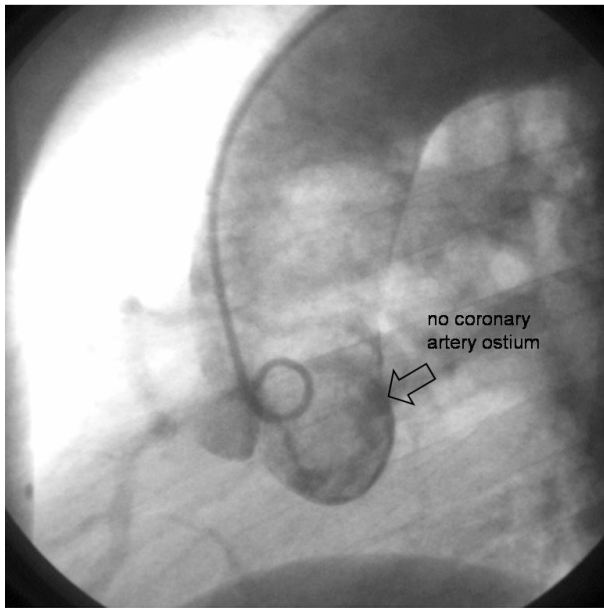


**Resim 2.** Selective catheterizations for LMCA from right coronary ostium.

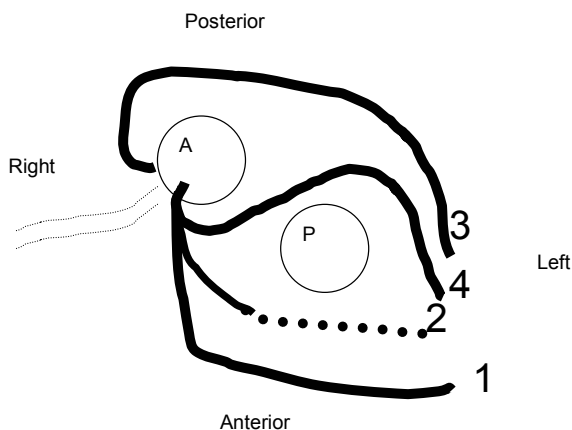
rosis were not present. Prophylactic surgery was not performed.

## Discussion

Left main coronary artery originating from the right sinus of Valsalva is a very rare but potentially



**Resim 3.** Aortography of the left sinus of Valsalva displays no coronary orifices.



**Figure 1.** Possible courses of an anomalous left main coronary artery arising from right aortic sinus of Valsalva. 1) Anterior free wall course, 2) Anterior intramyocardial course within the muscular septum beneath the right ventricular outflow tract, 3) Posterior free wall course and 4) Interarterial course between the aorta and pulmonary trunk.

serious congenital anomaly. The first ante-mortem diagnosis of a single coronary artery by coronary angiography was reported by Halperin et al.<sup>5</sup> Autopsy studies revealed a high coincidence of sudden cardiac death due to this anomaly in young males during or immediately after vigorous physical exercise.<sup>6,7</sup>

The severity of the condition depends on the relation of the anomalous left main artery to the aorta and the pulmonary artery. This anomaly has been classified into four subtypes according to the relation of the anomalous left main artery to the aorta and the pulmonary artery (Figure 1). Left main coronary artery may follow;

1-Anterior free wall course,

2-Anterior intra-myocardial course within the muscular septum beneath the right ventricular outflow tract,

3-Posterior free wall course and,

4-Inter-arterial course between the aorta and pulmonary trunk.<sup>3,4</sup>

If the left main coronary artery lies anterior or posterior to the left ventricular outflow tract and supplies its normal area of distribution, the condition is benign. In contrast, if it lies between the aorta and the right ventricular outflow tract (inter-arterial course), the outlook is different and is associated with sudden cardiac death and warrants prophylactic coronary bypass surgery.<sup>8</sup> Patients may also present with syncope, angina pectoris, myocardial infarction or ventricular tachycardia.<sup>9,10</sup>

Mechanisms proposed to explain the coronary events are as follows:

1-Compression of the left main coronary artery between the aorta and the pulmonary artery trunk during vigorous exercise as these vessels dilate,

2-Angulations of origin from right sinus Valsalva creating a slit like orifice rather than oval shape, combined with exercise induced aortic distension may produce further narrowing of the orifice,

3-Spasm, kinking and torsion of left main coronary artery and

4-Congenitally small left coronary system.<sup>11</sup>

The gold standard for the diagnosis of anomalous coronary vessels and defining its course is still coronary angiography.<sup>12</sup> Selective anomalous coronary angiography can usually determine the course of the left main coronary artery. Selective angiography of anomalous LMCA in the right anterior

oblique and lateral view and aortography was suggested to aid in the determination of the course of the anomalous LMCA. If the anomalous left main coronary artery lies between the aorta and the right ventricular infundibulum, it forms a cranial-posterior loop. In our case, selective angiography of the anomalous coronary artery in the right anterior oblique view showed a rightward, cranial and anterior course, which suggests the anterior free wall subtype. In addition, total occlusion of the middle circumflex artery and atherosclerotic changes in the left anterior descending coronary artery were determined by coronary arteriography. Information on the development of atherosclerosis in patients with coronary anomalies is limited. Click RL et al reported that, anomalous circumflex coronary arteries had a significantly greater degree of stenosis than that in non-anomalous arteries in age and gender matched control patients.<sup>13</sup> In our case, the circumflex artery was obstructed at the middle portion. The distal circumflex artery was filled through collateral vessels originating from the right coronary artery. Mild atherosclerosis was also present in the left anterior descending coronary artery.

In summary, anomalous origin of the left main coronary artery from the right coronary artery ostium is a very rare congenital anomaly of coronary arteries. Course of the anomalous artery is an important indication for prognosis. We report and discuss the clinical significance of a case with atherosclerotic coronary artery disease and anomalous origin of the left main coronary artery from the right coronary artery ostium.

#### REFERENCES

1. Yamanaka O, Hobbs RE. Coronary artery anomalies in 126,595 patients undergoing coronary arteriography. *Cathet Cardiovasc Diagn* 1990;21:28-40.
2. Lipton MJ, Barry WH, Obrez I, Silverman JF, Wexler L. Isolated single coronary artery: Diagnosis, angiographic classification, and clinical significance. *Radiology* 1979; 130:39-47.
3. Angelini P. Coronary artery anomalies-current clinical issues: Definitions, classification, incidence, clinical relevance, and treatment guidelines. *Tex Heart Inst J* 2002; 29:271-8.
4. Ishikawa T, Brandt PW. Anomalous origin of the left main coronary artery from the right anterior aortic sinus: Angiographic definition of anomalous course. *Am J Cardiol* 1985;55:770-6.
5. Halperin IC, Penny JL, Kennedy RJ. Single coronary artery. Antemortem diagnosis in a patient with congestive heart failure. *Am J Cardiol* 1967;19:424-7.
6. Roberts WC, Kragel AH. Anomalous origin of either the right or left main coronary artery from the aorta without coursing of the anomalistically arising artery between aorta and pulmonary trunk: *Am J Cardiol* 1988;62:1263-7.
7. Cheitlin MD, De Castro CM, McAllister HA. Sudden death as a complication of anomalous left coronary origin from the anterior sinus of Valsalva: A not so minor congenital anomaly. *Circulation* 1974;50:780-7.
8. Reul RM, Cooley DA, Hallman GL, Reul GJ. Surgical treatment of coronary artery anomalies report of a 37 year experience at the Texas Heart Institute. *Tex Heart Inst J* 2002;29:299-307.
9. Safi AM, Rachko M, Tang A, Ketosugbo A, Kwan T, Afflu E. Anomalous origin of the left main coronary artery from the right sinus of Valsalva: Disabling angina and syncope with noninterarterial courses case report of two patients. *Heart Dis* 2001;3:24-7.
10. Liberthson RR, Dinsmore RE, Fallon JT. Aberrant coronary artery origin from the aorta. Report of 18 patients, review of literature and delineation of natural history and management. *Circulation* 1979;59:748-54.
11. Barth CW 3<sup>rd</sup>, Roberts WC. Left main coronary artery originating from the right sinus of Valsalva and coursing between the aorta and pulmonary trunk. *J Am Coll Cardiol* 1986;7:366-73.
12. Garg N, Tevari S, Kapoor A, Gupta DK, Sinha N. Primary congenital anomalies of the coronary arteries: A coronary arteriographic study. *Int J Cardiol* 2000;74:39-46.
13. Click RL, Holmes DR Jr, Vlietstra RE, Kosinski AS, Kronmal RA. Anomalous coronary arteries: Location, degree of atherosclerosis and effect on survival: A report from the Coronary Artery Surgery Study. *J Am Coll Cardiol* 1989;13:531-7.