

Eyelid Nodular Hidradenoma: Case Report

Göz Kapağında Nodular Hidradenoma

Meydan TURAN,^a
Gülay TURAN,^b
Alparslan ŞAHİN^c

Clinics of
^aOphthalmology,
^bPathology,
Atatürk State Hospital, Balıkesir
^cDepartment of Ophthalmology,
Dicle University Faculty of Medicine,
Diyarbakır

Geliş Tarihi/Received: 18.12.2013
Kabul Tarihi/Accepted: 08.05.2014

Yazışma Adresi/Correspondence:
Meydan TURAN
Atatürk State Hospital,
Clinic of Ophthalmology, Balıkesir,
TÜRKİYE/TURKEY
meydanturan@gmail.com

ABSTRACT Nodular hidradenoma is a benign cutaneous neoplasm originated from ducts of eccrine sweat glands. It usually presents as slowly enlarging, solitary, freely movable, solid or cystic swelling. It present most instances measure between 0.5 and 2.0 cm in diameter, although they may be larger. A nodular hidradenoma has been referred to as a clear cell hidradenoma, an eccrine sweat gland adenoma of the clear cell type, a solid cystic hidradenoma, and an eccrine acrospiroma. We report a case of a nodular hidradenoma in a 23-year-old woman who presented with a nodular swelling in the left lower eyelid. The examination revealed a solitary 6 mmx4 mm sized mass in the lid margin of the left lower eyelid. It was firm to hard in consistency, painless, and did not appear to extend to the deeper underlying tissues. There was no ulceration on the surface. The nodular hidradenoma was diagnosed by excisional biopsy.

Key Words: Eyelids; acrospiroma; sweat gland neoplasms

ÖZET Nodüler hidradenoma ekrin ter bezlerinin duktuslarından köken alan iyi huylu bir cilt tümörüdür. Genellikle yavaş büyüme gösterir. Tek, hareketli, solid veya kistik şişlik şeklinde görülür. Ölçüleri olguların büyük bir bölümünde 0,5 cm ile 2,0 cm arasında değişir ancak daha büyük olabilirler. Nodular hidradenoma clear cell hidradenoma, ekrin sweat gland adenoma clear cell tip, solid kistik tip, ve ekrine akrospiroma isimleri ile de adlandırılmaktadır. Bu makalede yirmiüç yaşında sol alt göz kapağında şişlik ile gelen kadın olgudaki nodüler hidradenomu sunuyoruz. Muayenede sol alt göz kapağında 6 mmx4 mm boyutlarında kitle tespit edildi. Sert yoğunlukta, ağrısız ve cilt altına doğru uzanmaktaydı. Yüzeyinde ülserasyon yoktu. Eksizyonel biyopsi ile nodüler hidradenoma tanısı konuldu.

Anahtar Kelimeler: Göz kapakları; akrospirom; terbezi tümörleri

Türkiye Klinikleri J Case Rep 2015;23(3):279-81

Nodular hidradenomas arise as intradermal nodules in a variety of anatomical sites from eccrine sweat glands.¹ However, sweat gland tumors are extremely rare in the eyelids.² Ultrastructural and enzyme histochemical studies have shown nodular hidradenomas to be intermediate between eccrine poroma and eccrine spiradenoma.² The tumor is usually solitary. However, on rare occasions, multiple lesions have been reported.¹ In most instances, the intradermal nodules measure between 5 and 20 mm in diameter, although they may be larger. They are usually covered by intact skin, but some tumors show superficial ulceration and discharge serous material.¹ The histology of a malignant hidradenoma resembles that

of its benign counterpart. The criteria for malignancy include poor circumscription, presence of nuclear atypia, mitotic activity, presence of predominantly solid cell islands, an infiltrative growth pattern, necrosis, and angio-lymphatic permeation.³⁻⁵ Sweat gland tumors of the eyelid are extremely rare, but the possibility of sweat gland tumors should be considered during a differential diagnosis of eyelid tumors.

CASE REPORT

A 23-year-old woman presented to our clinic with an enlarged, painless, nodular mass in the left lower lid that had appeared 6 months earlier. The patient have noticed that the mass grew in. The patient during this time and have not had prior trauma or infection. Physical examination revealed a solitary mass 6 mmx4 mm in size in the lid margin of the left lower eyelid. It was firm to hard in consistency, painless, and did not appear to extend to the deeper underlying tissues. The mass grossly was oval in shape, covered by skin. A complete, wide excision of the nodular mass with a 3 mm clear margin of healthy surrounding tissue was performed, together with primary closure. A biopsy was sent to the pathology clinic. The pathology clinic identified a nodular hidradenoma.

PATHOLOGICAL FINDINGS

Gross description: The specimen submitted to the pathology department comprised a nodular mass 0.8 cm in diameter. The cut surface was yellowish.

Microscopic description: Histopathological examination showed closely arranged tumor cells, some of which were round, fusiform, or polygonal in shape, with a biphasic cytoplasmic architecture. The first type cell contained eosinophilic cytoplasm, and the second type cell had clear cytoplasm (Figure 1). Duct-like structures and the stroma between the lobules varied from thin delicate vascularized cords were present in the tumor (Figure 2). No nuclear atypia necrosis or abnormal mitoses was present. There was positive immunohistochemical reactivity to epithelial membrane antigen, the S-100 protein, and vimentin. There was negative im-

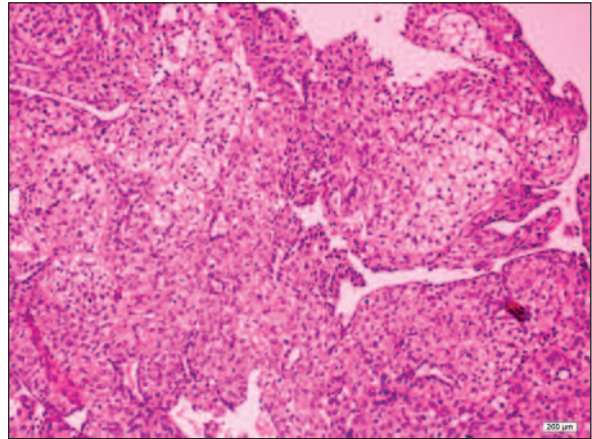


FIGURE 1: Round, polygonal-shaped tumor cells with clear cytoplasm (H and E, X200).

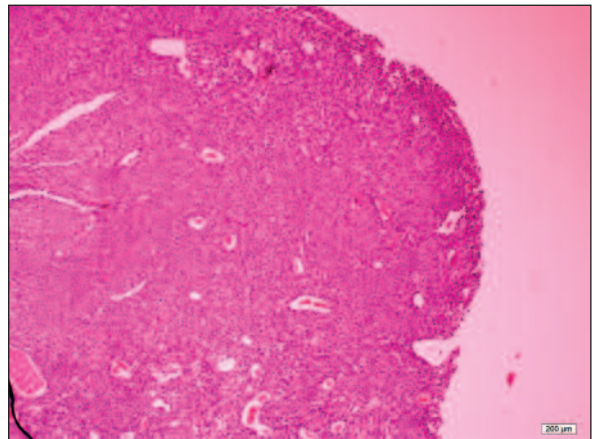


FIGURE 2: Tumor cells formed duct-like structures (H and E X100).

munohistochemical reactivity to smooth muscle actin and CD34.

The patient's informed consent has been obtained.

DISCUSSION

Histologically, sweat glands may be either eccrine or apocrine in nature. Eccrine glands are present throughout the skin but are most abundant in the palms, soles, and axillae. In the eyelid, eccrine glands are present at the lid margin and in the surface dermis. Apocrine glands are found in relatively fewer regions of the body, mainly the axillae, around the nipples, and the anogenital region. A small number have been reported on the

abdomen and chest.⁶ Nodular hidradenomas may occur at any age.¹ Nodular hidradenoma of the eyelid is very rare, and few cases have been reported.^{2,7}

Some of the reported case such a lesion in the eyelid; the 1st was reported in 1964.⁸ One case had indurated lesions of both lower lids, initially diagnosed as a basal cell carcinoma.⁹ In a study Baghli et al., a 51-year-old man presented with an enlarging, painless, nodular mass in the right upper lid that began 4 months prior with rapid increase in size over the last 3 months.⁷ After a wide excision in patient diagnosed malign nodular hidradenoma. In a study by Jagannath et al. a female patient aged 70 years presented with an ulcerative mass of the right lower lid of 8 months duration.¹⁰ Previously was diagnosed glandular carcinoma. Nodular mass occurs 3 months after the excision was diagnosed with nodular hidradenoma.

The incidence of recurrence after inadequate excision is 20% of cases.¹¹ Our case has no recurrences. In another study Alkatan et al. a female 46-year-old who presented with an enlarging painless mass of her right lower eyelid over a period of 18 months.¹²

In the present case, the tumor was benign and there was no surface ulceration. Our patient was younger than those in the literature. Immunohistochemical reactivity for keratin, epithelial membrane antigen, carcinoembryonic antigen, the S-100 protein, and vimentin has been reported.¹³ The tumor in the present case showed immunohistochemical reactivity for epithelial membrane antigen, the S-100 protein, and vimentin. The possibility of sweat gland tumors should be considered in the differential diagnosis of eyelid tumors to ensure early detection. Management involves complete excision of the lesion. At the last visit, 6 months after the excision, there was no recurrence of the lesion.

REFERENCES

1. Klein W, Chan E, Seykora JT. Tumors of the epidermal appendages. In: Elder DE, ed. *Lever's Histopathology of the Skin*. 9th ed. Philadelphia, PA: Lippincott, Williams and Wilkins; 2005. p.906-8.
2. Agarwala NS, Rane TM, Bhaduri AS. Clear cell hidradenoma of the eyelid: a case report. *Indian J Pathol Microbiol* 1999;42(3): 361-3.
3. Headington JT, Niederhuber JE, Beals TF. Malignant clear cell acrospiroma. *Cancer* 1978;41(2):641-7.
4. Mehregan AH, Hashimoto K, Rahbari H. Eccrine adenocarcinoma. A clinicopathologic study of 35 cases. *Arch Dermatol* 1983; 119(2):104-14.
5. Volmar KE, Cummings TJ, Wang WH, Creager AJ, Tyler DS, Xie HB. Clear cell hidradenoma: a mimic of metastatic clear cell tumors. *Arch Pathol Lab Med* 2005;129(5):e113-6.
6. Ahluwalia BK, Khurana AK, Chugh AD, Mehtani VG. Eccrine spiradenoma of eyelid: case report. *Br J Ophthalmol* 1986;70(8):580-3.
7. Al Baghli A, Reddy SS, Reddy MA. Malignant nodular hidradenoma of the eyelid: a rare sweat gland tumor. *Middle East Afr J Ophthalmol* 2010;17(4):374-6.
8. Boniuk M, Halpert B. Clear cell hidradenoma or myoepithelioma of the eyelid. *Arch Ophthalmol* 1964;72:59-63.
9. Greer CH. Clear cell hidradenoma of the eyelid. *Arch Ophthalmol* 1968;80(2):220-2.
10. Jagannath C, Sandhya CS, Venugopalachari K. Eccrine acrospiroma of eye lid--a case report. *Indian J Ophthalmol* 1990;38(4):182.
11. Duke Elder S. *System of Ophthalmology*, Vol. XII, part I. 2nd ed. London: Henry Kimpton; 1964. p.1-458.
12. Alkatan HM. Nodular hidradenoma of the lower eyelid. *Can J Ophthalmol* 2007;42(1): 149-50.
13. Elder D, Elenitsas R, Ragsdale BD. Tumors of the epidermal appendages. In: Elder D, Elenitsas R, Jaworsky C, Johnson Jr B, eds. *Lever's Histopathology of the Skin*. 8th ed. Philadelphia, New York: Lippincott Raven; 1997. p.786-9.