

Leptospiral Lymphadenopathy: Case Report

Leptospiral Lenfadenopati

Özgür EKİNCİ, MD,^a
Vedat TURHAN, MD,^b
Aptullah HAHOLU, MD,^c
Erdal POLAT,^d
Nuri YİĞİT, MD,^c
Hüseyin BALOĞLU, MD^c

^aDepartment of Pathology,
Gazi University Faculty of Medicine,
Ankara

Departments of
^bInfectious Diseases and
Clinical Microbiology,

^cPathology,
Gülhane Military Academy
Haydarpaşa Training Hospital,

^dDepartment of Clinical Microbiology,
İstanbul University
Cerrahpaşa Faculty of Medicine,
İstanbul

Geliş Tarihi/Received: 27.04.2009
Kabul Tarihi/Accepted: 13.02.2010

Yazışma Adresi/Correspondence:

Nuri YİĞİT, MD
Gülhane Military Academy
Haydarpaşa Training Hospital,
Department of Pathology, İstanbul,
TÜRKYE/TURKEY
nyigitsum@gmail.com

ABSTRACT Leptospirosis is a zoonotic infectious disease that can involve many organs and it has variable manifestations. In this paper, we describe epitrochlear lymph node involvement as an isolated finding in a case of anicteric leptospirosis, that, to our knowledge, has not been previously reported. The lymph node was excised and light microscopy showed enlarged secondary follicles with prominent germinal centers, some with bizarre shapes along with an increase in high endothelial venules. A Warthin-Starry stain revealed spirochetal organisms which were cork-screw shaped with hooked ends. Serology for leptospira confirmed this bacterium as the etiology of the reactive lymphadenopathy while tests for syphilis and borreliosis were negative.

Key Words: Leptospirosis; lymphadenitis

ÖZET Leptospiroz birçok organı tutabilen zoonotik enfeksiyöz bir hastalıktır ve değişken belirtileri vardır. Bu yazıda biz, bildiğimiz kadarıyla daha önce bildirilmemiş anikterik leptospirozlu bir olguda izole bulgu olarak epitrochlear lenf nodu tutulumu tanımlamaktayız. Lenf nodu eksize edildi ve ışık mikroskobu yüksek endotelial venüllerde bir artış ve bazıları garip şekilli belirgin germinal merkezleri olan büyümüş sekonder folikülleri gösterdi. Warthin-Starry boyası kanca uçlu mantar vidası şekilli spiroketal organizmaları ortaya koydu. Sifiliz ve borelyoz için testler negatif iken leptospira serolojisi ise reaktif lenfadenopati nedeninin bu bakteri olduğunu doğruladı.

Anahtar Kelimeler: Leptospirozis; lenfadenit

Türkiye Klinikleri J Med Sci 2011;31(3):744-7

Leptospirosis is presumed to be the most widespread zoonosis in the world.¹ The disease can affect many organ systems by its capability of extensive vascular damage. Lymph node involvement is recognized. We report a case of leptospirosis with epitrochlear lymphadenopathy as its predominant finding, which is an unexpected presentation.

CASE REPORT

A 21-year-old male patient, a military personnel working in the radiator department, was admitted to the clinic with complaints of fever, chills, headache, dizziness, malaise and myalgias of sudden onset, and he was administered cefuroxime 500 mg bid for five days with a diagnosis of upper respiratory infection in the local infirmary. He had a bruise with a crusted surface of 0.5

cm at the tip of the third digit of the right hand, but he could not tell exactly when and how it had formed. His complaints resolved partially over the next week while a swelling developed in the epitrochlear region of his right arm. His physical examination was otherwise normal. There was no history of suspicious sexual intercourse, insect or animal bite. He was referred to our center and the epitrochlear mass was excised. At this time, three weeks after the appearance of the symptoms, his sole complaint was mild malaise and serum biochemistry and complete blood cell counts were in the normal range. To rule out syphilis, we ordered Venereal Disease Research Laboratory (VDRL) and Treponema Pallidum Hemagglutination (TPH) tests which were negative. Enzyme-linked immunosorbent assay (ELISA) test for leptospira IgM (Leptospira IVD Research Inc. Carlsbad CA 92008, USA) was positive. ELISA for *Borrelia burgdorferi* IgM and IgG (Ridascreen, Germany) as well as antibodies against human immunodeficiency virus (HIV) were negative. In the light of these findings, a diagnosis of leptospirosis was established and the patient was administered a seven-day therapy of doxycycline 200 mg/day. When this report was written, he was well and the complaints were resolved in the fourth month of the disease.

Macroscopic examination showed an 1.5 cm diametered encapsulated oval mass. The tissue was fixed in 10% formaldehyde overnight. Samples were processed and embedded in paraffin blocks which were sectioned and stained with hematoxylin and eosin, Warthin-Starry and Giemsa stains.

Light microscopy showed a reactive lymph node structure with intact fibrous capsule, subcapsular sinuses, trabeculae and medullary sinuses. Cortical secondary follicles were enlarged with prominent germinal centers. Some of the follicles had bizarre shapes with irregular outlines (Figure 1). A polymorphic population of lymphocytes and increased number of high endothelial venules were observed in the paracortex (Figure 2). Germinal centers contained a reactive population of centrocytes, centroblasts and tingible body macrophages. Neutrophils and eosinophils were absent and no significant number of plasma cells was found. The-

re were no necrosis, fibrosis, granulomatous reaction or evidence of a neoplastic process. Giemsa slides were negative for an infectious agent, whereas Warthin-Starry stain revealed, though few, spirochetal microorganisms in various foci in the node. These black stained bacteria were about 15-20 μm in length and about 1-2 μm in thickness, with spiral morphology reminiscent of the shape of a corkscrew (Figures 3, 4). Importantly there were bendings at the edges. This morphology was found consistent with leptospira.

DISCUSSION

In the past decade, leptospirosis has emerged as a globally important infectious disease with significant mortality rates in both industrialized and developing countries.¹⁻⁵ Humans contract the disease via direct or indirect contact of the urine of the infected animals. Rodents are the main maintenance hosts.⁶ Leptospire are tightly coiled spirochetes, usually 0.1 μm x 6-20 μm and are very motile.^{6,7} They are unique among spirochetes as usually their one or both ends are bent or hooked, but straight forms also occur.^{8,9} Two species of leptospire are recognized, the saprophytic *Leptospira biflexa* and pathogenic *Leptospira interrogans*.^{3,5,8}

Clinically, the disease has two forms: anicteric and icteric. The anicteric form is mostly asymptomatic. Icteric leptospirosis (Weil's syndrome) is a severe, rapidly progressive disease with high mortality rates. Multiple organs are affected, including liver, kidney, lung, heart, eye and many others.^{1,4,6} Our patient was consistent with symptomatic anicteric leptospirosis.

Leptospire gain systemic access to humans through abraded skin or lacerations, intact mucous membranes and even intact skin. A contact of the finger wound with rat urine might have been the route of entry in our patient who worked in the radiator department.

After entry, leptospire can cause a severe vasculitis with endothelial damage in capillaries and medium and large arteries like other spirochetal diseases.^{8,9} This diffuse and extensive vasculitis lies at the heart of various clinical manifestations of lep-

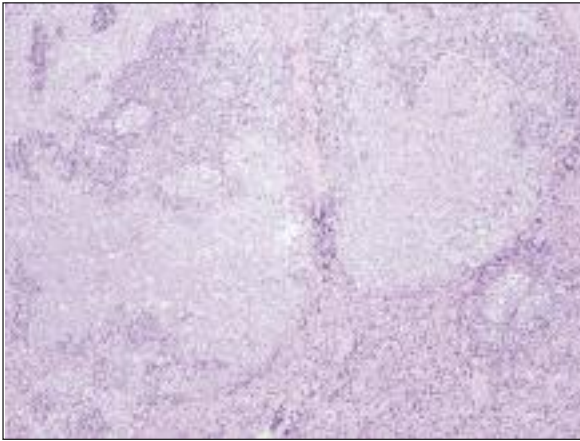


FIGURE 1: Prominent germinal centers with a bizarre outline (HE, x100).

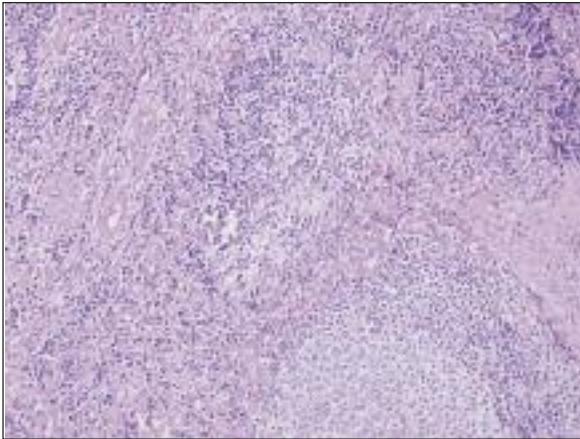


FIGURE 2: Increased and hyperplastic endothelial venules in the interfollicular area (HE, x200).

tospirosis. Involved tissues exhibit inflammatory infiltrates composed of plasma cells, histiocytes and neutrophils.^{6,8}

Epitrochlear lymphadenopathy is notorious for its association with certain infectious and neoplastic diseases. The finding of enlarged epitrochlear lymph nodes in the absence of any upper extremity pathology is considered to be highly suspicious for secondary syphilis which should be ruled out.¹⁰ Specific morphological criteria have not been defined for lymph node involvement in leptospirosis. In our case, follicular hyperplasia was the most prominent finding. Bizarre shapes of these enlarged follicles and vascular hyperplasia reminded of syphilis. Luetic lymphadenopathy is characterized by hyperplasia of follicles with bizar-

re shapes, epithelioid granulomas, isolated multinucleated giant cells, presence of large numbers of plasma cells, proliferation of blood vessels with endothelial hyperplasia, phlebitis, endarteritis, and inflammation and fibrosis of the capsule.⁹ The organism is positive by Warthin-Starry staining in almost all of the cases and does not have the hooked-end morphology of leptospire.⁹ In our patient, VDRL and TPH tests were negative.

Lyme disease by *Borrelia burgdorferi* can involve the lymph nodes.¹¹ In the lymph nodes of dogs with experimental Lyme disease, multiple follicles with large germinal centers, expansion of pa-

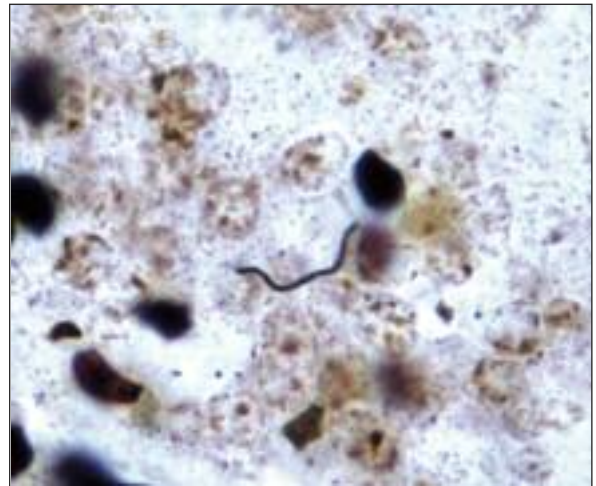


FIGURE 3: Spirochete with hooked ends (Warthin-Starry, oil immersion, x1000).

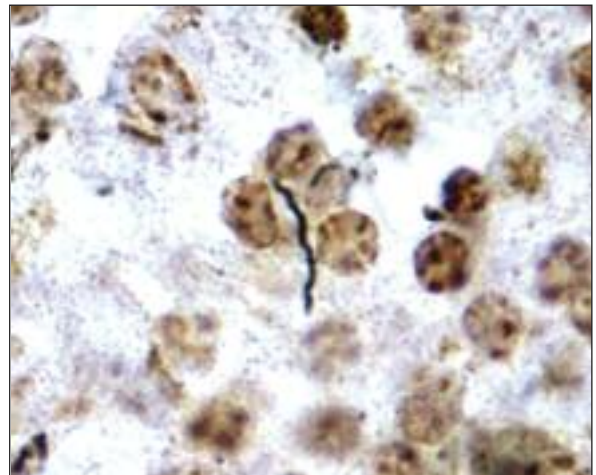


FIGURE 4: Cork-screw morphology of a spirochete (Warthin-Starry, oil immersion, x1000).

rafollicular zones with dense sheets of small lymphocytes, occasional deep follicles in the medulla and plasma cells in medullary cords were reported.¹² This morphology is similar to the present case except for the plasma cells. Lyme disease was ruled out as ELISA test for borrelia IgM was negative and both the history of a tick bite and the characteristic clinical findings of early Lyme disease were absent.

Rat-bite fever was also considered in the differential diagnosis. Transmission is by rat bite in this disease. Of the two causative agents *Streptobacillus moniliformis* was ruled out based on, in addition to the serological evidence for leptospirosis, the following: (1) *S.moniliformis* is smaller than leptospires with a width of 0.3-0.7 µm and length of 1 to 5 µm; and (2) regional lymphadenitis is not a usual feature of *S.moniliformis* - related rat-bite fever. The other agent, *Spirillum minus*, causes a significant portion of the cases of rat-bite fever in Asia. *S. minus* is a gram-negative, tightly coiled spiral rod that is also shorter and thicker than the leptospire (with a size of 0.2 to 0.5 x 3 to 5 µm).¹³ *S. minus*-related rat-bite fever may be accompanied by hyperplastic regional lymphadenitis and a

blotchy rash. *S. minus* cannot be cultured in vivo and no specific serologic tests are available. For these reasons *S. minus* was a strong consideration in the patient. Nevertheless, the exclusion of this agent was based on the microbic morphology in the Warthin-Starry-stained slides which showed the structure, size, number of folds and a hooked end compatible with leptospires, in addition to the positive serological result for this infection.

Microscopic demonstration of leptospires is possible by silver staining, immunofluorescence or immunohistochemistry.^{1,6,7} Warthin Starry's method for staining is based on chemically reducing surface properties of spirochetes and is widely used for histological examination.⁷ Definitive diagnosis rests on culture, immunohistochemistry or PCR to show leptospiral DNA.¹ ELISA for leptospira IgM can detect antibodies during the first week of the illness, allowing an early diagnosis.^{4,6}

We conclude that leptospirosis can involve a lymph node as its predominant physical finding and cause a reactive lymphadenopathy with enlarged bizarre-shaped follicles along with increased high endothelial venules, and a simple histochemical stain can demonstrate the microorganisms.

REFERENCES

- Bharti AR, Nally JE, Ricaldi JN, Matthias MA, Diaz MM, Lovett MA, et al.; Peru-United States Leptospirosis Consortium. Leptospirosis: a zoonotic disease of global importance. *Lancet Infect Dis* 2003;3(12):757-71.
- McBride AJ, Athanazio DA, Reis MG, Ko AI. Leptospirosis. *Curr Opin Infect Dis* 2005; 18(5):376-86.
- Palaniappan RU, Ramanujam S, Chang YF. Leptospirosis: pathogenesis, immunity, and diagnosis. *Curr Opin Infect Dis* 2007;20(3):284-92.
- Turhan V, Ardiç N. [Leptospirosis]. *Turkiye Klinikleri J Microbiol-Infec* 2004;3(3):107-15.
- Vijayachari P, Sugunan AP, Shriram AN. Leptospirosis: an emerging global public health problem. *J Biosci* 2008;33(4):557-69.
- Levett PN. Leptospirosis. *Clin Microbiol Rev* 2001;14(2):296-326.
- Samsiava RR, Naveen G, PB, Agarwal SK. Leptospirosis in India and the rest of the world. *Braz J Infect Dis* 2003;7(3):178-93.
- Binder WD, Mermel LA. Leptospirosis in an urban setting: case report and review of an emerging infectious disease. *J Emerg Med* 1998;16(6):851-6.
- Hartsock RJ, Halling LW, King FM. Luetic lymphadenitis: a clinical and histologic study of 20 cases. *Am J Clin Pathol* 1970;53(3):304-14.
- Tramont EC. *Treponema pallidum* (Syphilis). In: Mandell GL, Bennett JE, Dolin R, eds. *Mandell, Douglas, and Bennett's Principles and Practices of Infectious Diseases*. 7th ed. Philadelphia: Churchill Livingstone; 2010. p.2768-83.
- Duray PH. Histopathology of clinical phases of human Lyme disease. *Rheum Dis Clin North Am* 1989;15(4):691-710.
- Summers BA, Straubinger AF, Jacobson RH, Chang YF, Appel MJ, Straubinger RK. Histopathological studies of experimental lyme disease in the dog. *J Comp Pathol* 2005;133(1):1-13.
- Washburn RG. Rat-bite fever: *Streptobacillus moniliformis* and *Spirillum minus*. In: Mandell GL, Bennett JE, Dolin R, eds. *Principles and Practice of Infectious Diseases*. 7th ed. Philadelphia: Elsevier Churchill Livingstone; 2010. p.2965-7.