

Preeruptive Intracoronal Resorption in Multiple Teeth: An Unusual Case Series

Birden Fazla Dişte Erüpsiyon Öncesi İntrakoronal Rezorpsiyon: Sıra Dışı Bir Vaka Serisi

İlkay PEKER^a, Arzu Zeynep YILDIRIM BİÇER^b, Nuray BAĞCI^a, Senem ÜNVER^b,
Zeynep Fatma ZOR^c

^aDepartment of Oral and Maxillofacial Radiology, Gazi University Faculty of Dentistry, Ankara, TÜRKİYE

^bDepartment of Prosthetic Dental Treatment, Gazi University Faculty of Dentistry, Ankara, TÜRKİYE

^cDepartment of Oral and Maxillofacial Surgery, Gazi University Faculty of Dentistry, Ankara, TÜRKİYE

ABSTRACT Pre-eruptive intracoronal resorption (PIR) is characterized by radiolucent lesion within coronal dental tissue and rarely seen in unerupted permanent teeth. The affected teeth are generally asymptomatic and detected during routine dental radiographic examination. Amelogenesis imperfecta (AI) is a group of relatively rare inherited abnormalities in enamel formation and/or calcification. A history of consanguineous marriage should be considered in individuals with the type of autosomal recessive AI (ARAI). Several dental alterations especially intracoronal resorption of unerupted teeth and failure or delayed eruption are more common in AI patients than in unaffected individuals. This report presents the clinical and radiographic findings of ARAI and PIR cases simultaneously seen in three generations of a family and oral rehabilitation of an unusual member of the same family.

ÖZET Erüpsiyon-öncesi intrakoronal rezorpsiyon (EİR), koronal dentin dokusunda radyolüsent lezyonla karakterizedir ve nadiren gömülü daimi dişlerde görülür. Etkilenen dişler genellikle asemptomatiktir ve rutin radyografik diş muayenesinde tespit edilir. Amelogenesis imperfekta (AI), mine oluşumu ve/veya kalsifikasyonunda görülen nispeten nadir kalıtsal anormallikler grubudur. Otozomal resesif AI (ORAI) tipi olan bireylerde akraba evliliği öyküsü düşünülmelidir. Farklı dişsel değişiklikler, özellikle gömülü dişlerin intrakoronal rezorpsiyonu ve sürme gecikmesi veya sürememe, etkilanmemiş bireylere göre AI hastalarında daha yaygındır. Bu rapor, bir ailenin 3 neslinde aynı anda görülen ORAI ve EİR vakalarının klinik ve radyografik bulgularını ve aynı ailenin sıra dışı bir üyesinin oral rehabilitasyonunu sunmaktadır.

Keywords: Tooth resorption; tooth unerupted; radiography

Anahtar Kelimeler: Diş rezorpsiyonu; gömülü diş; radyografi

The term “intracoronal resorption” has been described as an abnormal, well-circumscribed radiolucent area within the coronal dentin tissue occurring close to the dentin-enamel junction in occlusal surfaces of unerupted teeth.¹ These lesions have been called by various names such as “pre-eruptive intracoronal resorption (PIR)”, “pre-eruptive caries”, “PIR or defect or radiolucency”, “intra-follicular caries”, and “idiopathic coronal resorption”.¹⁻³ In this article, the term “PIR” was preferred. In the literature, this condition was first described by Skillen in 1941 and several theories have been put forward for its etiology.⁴ Some authors suggested that it was associated

with chronic apical inflammation in primary precursors and ectopic eruption of affected teeth or systemic factors, such as herpes zoster.^{5,6}

Amelogenesis imperfecta (AI) is a group of relatively rare inherited abnormalities in enamel formation or calcification.⁷ Especially intracoronal resorption of unerupted teeth and failure eruption were found to be more common in AI patients than in unaffected individuals.⁸ Previous studies reported that autosomal recessive AI (ARAI) should be considered for AI in individuals with a history of consanguineous marriage.^{9,10} Therefore, ARAI is more common in societies where family marriages are common.¹⁰

Correspondence: Nuray BAĞCI

Department of Oral and Maxillofacial Radiology, Gazi University Faculty of Dentistry, Ankara, TÜRKİYE/TÜRKİYE

E-mail: dtnuraybagci@gmail.com



Peer review under responsibility of Türkiye Klinikleri Journal of Dental Sciences.

Received: 25 Dec 2020

Received in revised form: 15 Mar 2021

Accepted: 16 Mar 2021

Available online: 31 Mar 2021

2146-8966 / Copyright © 2022 by Türkiye Klinikleri. This is an open access article under the CC BY-NC-ND license (<http://creativecommons.org/licenses/by-nc-nd/4.0/>).

To the best of our knowledge, except for single published articles to date, no family type of PIR has been mentioned in the literature. In 2011, Miloglu et al. showed the case of two sisters with generalized familial PIR.¹¹ This report presents the clinical and radiographic findings of ARAI and PIR cases simultaneously seen in three generations of an unusual family and oral rehabilitation of an unusual member of the same family.

CASE REPORTS

CASE 1

A 35-years-old male was referred to our clinic for replacement of his prosthesis. Medical history revealed that he had feverish illness twice in infancy and splenectomy surgery two years ago. Extraoral examination revealed hypertrichosis in his hair and eyebrows. In intraoral examination, incompatible fixed partial dentures in the maxilla and mandible were observed. Panoramic radiography examination revealed unerupted teeth; six in the maxilla and 10 in the mandible and PIR was noticed in 10 of them ([Figure 1](#)). The cone beam computed tomography (CBCT) scan showed that maxillary unerupted posterior teeth were related with bilateral maxillary sinuses and bi-

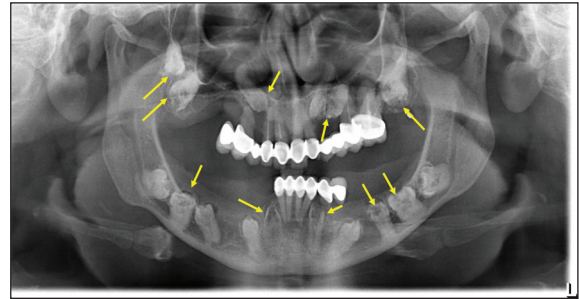


FIGURE 1: Unerupted 16 teeth; six in the maxilla and 10 in the mandible and pre-eruptive intracoronal resorption in 10 of them in panoramic radiography image (yellow arrow; various pre-eruptive intracoronal resorption defects).

lateral maxillary canines were related with floor of nasal cavity and bilateral mandibular unerupted posterior teeth were related with inferior alveolar canals. CBCT images verified the presence of PIR in 10 teeth: five in each jaw ([Figure 2](#)). PIR is classified according to the size of the defect: in PIR 1 defect, the resorption is less than one-third of the dentin thickness; in PIR 2 defect, it is between one-third and two-thirds of the dentin thickness and in PIR 3 defect, the resorption extends to more than two-thirds of the dentin thickness.¹² PIR 1 defect and PIR 2 defect were each found in one tooth, and PIR 3 defect was found in eight teeth ([Table 1](#)).

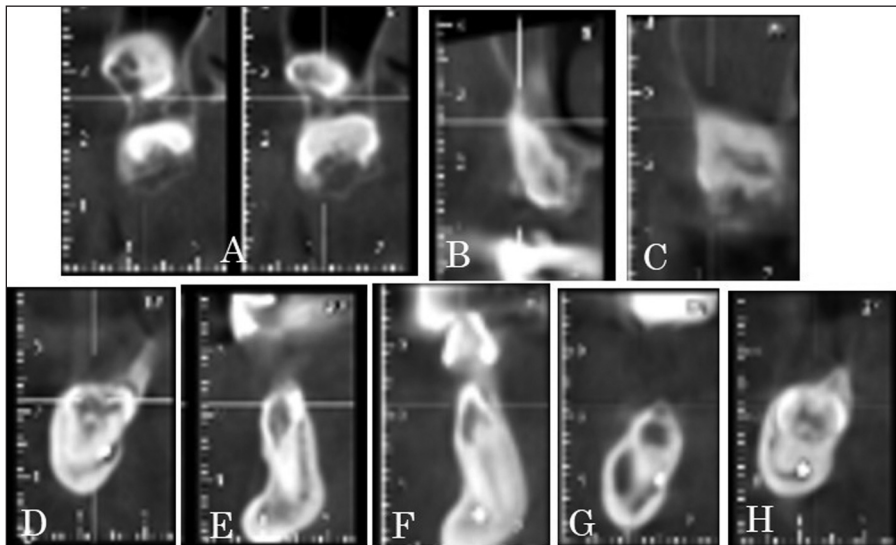


FIGURE 2: The image of cone-beam computed tomography; **A:** Maxillary right first and second molar teeth, **B:** Maxillary left first premolar tooth, **C:** Maxillary left second molar tooth, **D:** Mandibular right first molar tooth, **E:** Mandibular right canine tooth, **F:** Mandibular left canine tooth, **G:** Mandibular left second premolar tooth, **H:** Mandibular left first molar tooth.

TABLE 1: Dental examinations of the case and consanguinity relatives.

Cases	Consanguinity with the patient	Age/Sex	The characteristics of unerupted teeth in the cases			Other dental findings	
			Unerupted teeth	PIR defects			
				PIR 1	PIR 2		PIR 3
Case 1	The patient (His parents are second cousin consanguineous marriage)	35/Male	18, 17, 13, 23, 24, 27, 33, 34, 35, 36, 38, 43, 44, 45, 46, 48	23	18, 46	17, 24, 27, 33, 35, 36, 43	Cannot determined
Case 2	The patient's mother (Her parents are second cousin consanguineous marriage)	58/Female	18, 13, 38, 43	38	-	18, 13, 43	Cannot determined
Case 3	The patient's sister	39/Female	27, 38, 47, 48	-	-	27, 38, 47	ARAI
Case 4	The patient's wife (The daughter of the patient's aunt)	37/Female	18, 13, 23, 28, 48	-	48	18, 13, 23	ARAI, dens in dent, internal root resorption
Case 5	The patient's brother	37/Male	16, 26, 37, 38, 47, 48	-	-	-	Enamel hypoplasia
Case 6	The patient's first boy	10/Male	26	-	26	-	Abrasion, enamel hypoplasia
Case 7	The patient's second boy	5/Male					Enamel hypoplasia
Case 8	The patient's daughter	3/Female					Enamel hypoplasia

Teeth were named according to the FDI system; ARAI: Autosomal recessive amelogenesis imperfecta; PIR: Pre-eruptive intracoronal resorption.

■ Familial History of the Patient

Detailed familial anamnesis was taken to analyze hereditary characteristics. It was learned that his father and mother were second cousin consanguineous marriage, and he has got a sister, and a brother. He is married to his aunt's daughter (first cousin consanguineous marriage) and has two boys, and a daughter. The pedigree of the family is shown in [Figure 3](#).

■ Dental Findings of the Patient and Consanguinity Relatives

We noted similar findings in his mother (Case 2), his sister (Case 3), his wife (Case 4), his brother (Case 5), and his boy (Case 6). Their detailed consanguinity relatives and dental findings have been shown in [Table 1](#). During intraoral examination, the enamel hypoplasia and missing of enamel in incisal and occlusal surfaces of many teeth in Case 3, Case 4, and Case 6 have been shown ([Figure 4](#)). Their panoramic radiographies have been shown in [Figure 5](#).

The status of dental enamel of the patient cannot be observed due to his fixed prosthesis on the available teeth. Similarly, her mother's dental enamel cannot be assessed. Based on anamnestic, clinical, and radiographic findings, his wife was diagnosed as ARAI (hypocalcified type) and his sister was diagnosed as ARAI (hypoplastic type).

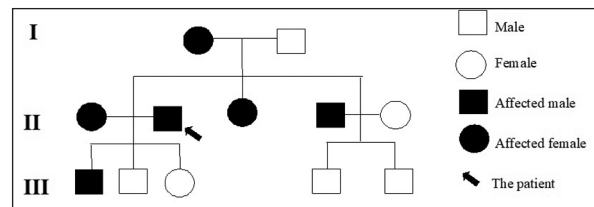


FIGURE 3: The family pedigree of the patients.

■ Treatment Planning and Oral Rehabilitation

Several complicated surgical approaches might be necessary for extraction of the impacted teeth and implant-supported prosthetic restorations. Therefore, a comparatively conservative approach was planned, and fixed partial dentures were prepared instead of former prosthesis to the supported teeth and then removable partial dentures were fabricated. It was decided to follow the impacted teeth with PIR defects of the patient periodically with panoramic radiography.

The patient received all the necessary treatments for prosthetic dental treatment. At the beginning of the treatment, the patient was given oral hygiene training. The maxillary left first molar tooth was extracted. Root-canal treatment was applied to the mandibular right-left central, and right lateral incisor teeth ([Figure 6a](#)). Re-treatment root canal was applied

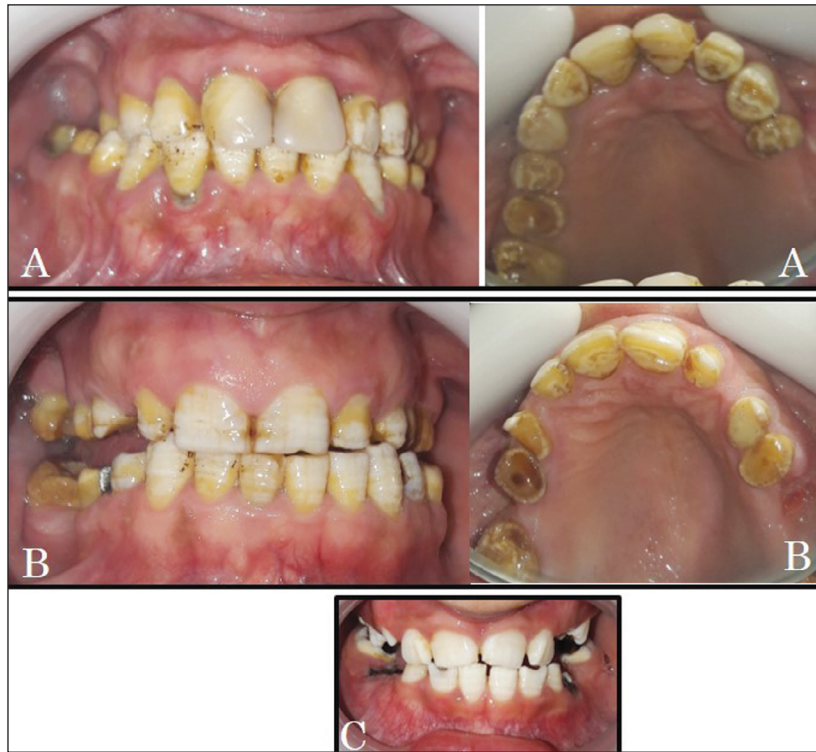

FIGURE 4: The enamel hypoplasia and missing of enamel in incisal and occlusal surfaces of many teeth in intraoral image; A: Case 3, B: Case 4, and C: Case 6.

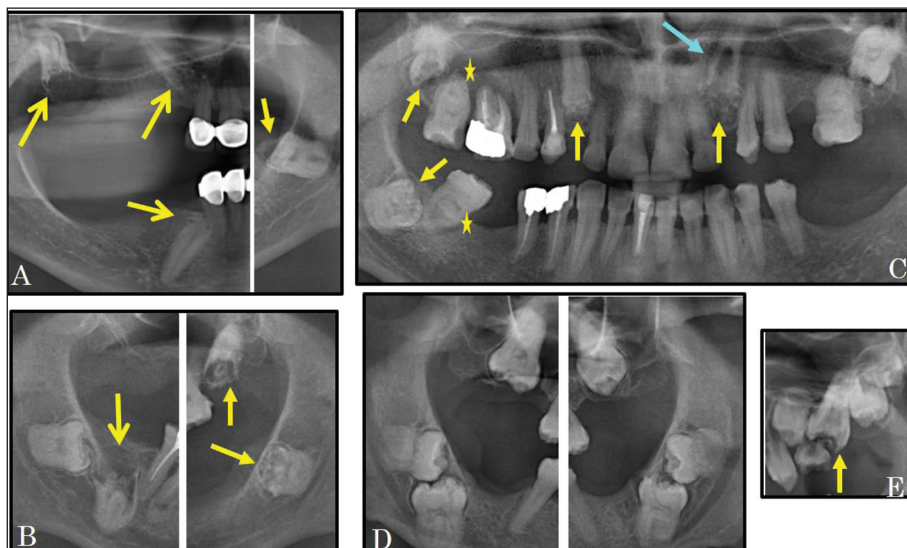


FIGURE 5: The image of cropped panoramic radiography; A: Case 2, B: Case 3, C: Case 4, D: Case 5, E: Case 6 (yellow arrow: various pre-eruptive intracoronal resorption defect, blue arrow: internal root resorption, yellow astral: dens in dent).

to the maxillary right central incisor (Figure 6b) and left second premolar teeth (Figure 6c). After sufficient recovery time, prosthetic dental treatment was started. The former fixed partial dentures of patient

were removed. Temporary crowns were fabricated and cemented with provisional cement (Cavex Temporary, Cavex BV, Haarlem, Netherlands). Maxillary left second premolar was extracted because of mo-

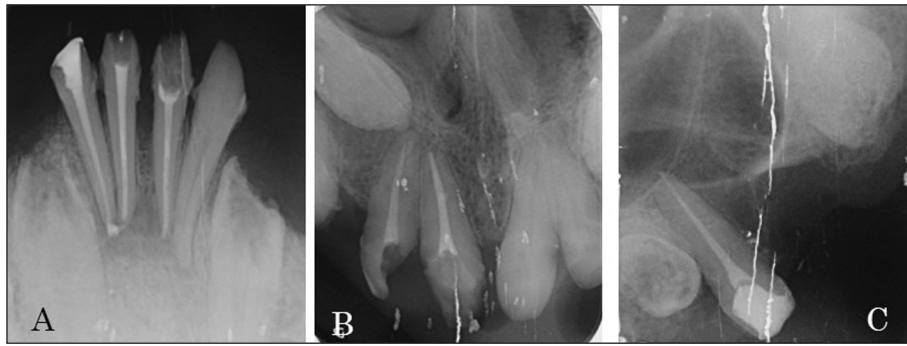


FIGURE 6: The image of periapical radiography after root canal treatment; **A:** Mandibular right-left central and right lateral incisor teeth, **B:** Maxillary right central incisor tooth, **C:** Maxillary second premolar tooth.

bility. Porcelain-fused-to metal fixed partial dentures and removable partial dentures were planned for both maxilla and mandible since unerupted teeth prevented implant placement. Temporary crowns were removed, and conventional impression was made with silicone impression material (Zetaplus, Zhermack, Badia Polesine, Italy). The occlusal vertical dimension was recorded to be three mm less than vertical dimension at rest with using record bases and occlusion rims. Porcelain-fused-to metal restorations were fabricated and cemented with zinc polycarboxylate cement (Adhesor Carbofine, Spofa Dental, Praha, Czechia). After, removable partial dentures were made. Vertical dimension, occlusion, function, aesthetics were evaluated, and the prosthesis were finished.

Written and verbal consent was obtained from all patients and parents of children patients that the treatment procedures and relevant data could be used in scientific studies.

DISCUSSION

In this article, we present an unusual case in which several dental abnormalities coexist simultaneously and dental alterations seen in himself and his relatives. Six individuals from the same family were evaluated.

In the literature, various number of cases have been reported in AI individuals with multiple unerupted teeth.^{8,13,14} In this article, a pedigree was made in the case of AI with multiple unerupted teeth and three generations of family members were ex-

amined clinically and radiographically. ARAI with multiple unerupted teeth including PIR was observed in two generations of the family.

The dental treatment approaches of AI and PIR patients are affected by many factors. In this case, was observed multiple impacted teeth. A comparatively conservative approach was planned. Similarly, it was decided to fabricate overlay complete denture over the remaining teeth of a 20-year-old female patient, who had multiple unerupted impacted permanent teeth, as it was thought to be a more conservative treatment.¹⁵

Multidisciplinary assessment is important for diagnosis and treatment of PIR and AI. Early detection of dental anomalies can ensure to save affected teeth from further resorption. Prosthetic treatments may be required to protect teeth and provide both aesthetic appearance and function. Clinical and radiographic follow-up is recommended to control abnormal teeth and restorations.

Source of Finance

During this study, no financial or spiritual support was received neither from any pharmaceutical company that has a direct connection with the research subject, nor from a company that provides or produces medical instruments and materials which may negatively affect the evaluation process of this study.

Conflict of Interest

No conflicts of interest between the authors and / or family members of the scientific and medical committee members or members of the potential conflicts of interest, counseling, expertise, working conditions, share holding and similar situations in any firm.

Authorship Contributions

Idea/Concept: İlkay Peker; **Design:** İlkay Peker, Arzu Zeynep Yıldırım Biçer, Zeynep Fatma Zor; **Control/Supervision:** İlkay Peker; **Data Collection and/or Processing:** Nuray Bağcı, Senem Ünver; **Analysis and/or Interpretation:** İlkay Peker, Arzu Zeynep Yıldırım Biçer,

Zeynep Fatma Zor; **Literature Review:** İlkay Peker, Nuray Bağcı, Arzu Zeynep Yıldırım Biçer; **Writing the Article:** İlkay Peker, Nuray Bağcı, Arzu Zeynep Yıldırım Biçer; **Critical Review:** İlkay Peker; **References and Findings:** İlkay Peker, Arzu Zeynep Yıldırım Biçer; **Materials:** Nuray Bağcı, Senem Ünver, Zeynep Fatma Zor.

REFERENCES

- O'Neal KM, Gound TG, Cohen DM. Preeruptive idiopathic coronal resorption: a case report. J Endod. 1997;23(1):58-9. [Crossref] [PubMed]
- Demirtas O, Dane A, Yıldırım E. A comparison of the use of cone-beam computed tomography and panoramic radiography in the assessment of pre-eruptive intracoronal resorption. Acta Odontol Scand. 2016;74(8):636-41. [Crossref] [PubMed]
- Baab DA, Morton TH, Page RC. Caries and periodontitis associated with an unerupted third molar. Oral Surg Oral Med Oral Pathol. 1984;58(4):428-30. [Crossref] [PubMed]
- Skillen W. So-called intra-follicular caries. Ill Dent J. 1941;10:307-8. [Link]
- Özden B, Acikgoz A. Prevalence and characteristics of intracoronal resorption in unerupted teeth in the permanent dentition: a retrospective study. Oral Radiol. 2009;25(1):6-13. [Crossref]
- Uzun I, Gunduz K, Canitezzer G, Avsever H, Orhan K. A retrospective analysis of prevalence and characteristics of pre-eruptive intracoronal resorption in unerupted teeth of the permanent dentition: a multicentre study. Int Endod J. 2015;48(11):1069-76. [Crossref] [PubMed]
- Bhatia SK, Hunter ML, Ashley PF. Amelogenesis imperfecta with coronal resorption: report of three cases. Dent Update. 2015;42(10):945-8,950. [Crossref] [PubMed]
- Korbmacher HM, Lemke R, Kahl-Nieke B. Progressive pre-eruptive crown resorption in autosomal recessive generalized hypoplastic amelogenesis imperfecta. Oral Surg Oral Med Oral Pathol Oral Radiol Endod. 2007;104(4):540-4. [Crossref] [PubMed]
- Jalili IK, Smith NJ. A progressive cone-rod dystrophy and amelogenesis imperfecta: a new syndrome. J Med Genet. 1988;25(11):738-40. [Crossref] [PubMed] [PMC]
- Michaelides M, Bloch-Zupan A, Holder GE, Hunt DM, Moore AT. An autosomal recessive cone-rod dystrophy associated with amelogenesis imperfecta. J Med Genet. 2004;41(6):468-73. [Crossref] [PubMed] [PMC]
- Miloglu O, Goregen M, Akgul HM, Harorli A. Generalized familial crown resorptions in unerupted teeth. Eur J Dent. 2011;5(2):206-9. [Crossref] [PubMed] [PMC]
- Seow WK, Lu PC, McAllan LH. Prevalence of pre-eruptive intracoronal dentin defects from panoramic radiographs. Pediatr Dent. 1999;21(6):332-9. [PubMed]
- Patil PG, Patil SP. Amelogenesis imperfecta with multiple impacted teeth and skeletal class III malocclusion: complete mouth rehabilitation of a young adult. J Prosthet Dent. 2014;111(1):11-5. [Crossref] [PubMed]
- Hegde S. Multiple unerupted teeth with amelogenesis imperfecta in siblings. N Am J Med Sci. 2012;4(5):235-7. [Crossref] [PubMed] [PMC]
- Shetty K, Kumar M, Amanna S, Sridharan S, Reddy S. Management of a rare case of idiopathic multiple unerupted impacted permanent teeth in an adult female patient. J Indian Prosthodont Soc. 2016;16(3):303-6. [PubMed] [PMC]