

Posterior Dislocation of Both Crystalline Lenses in a Patient with High Myopia: 40 Years Duration Without Complication: Case Report

Yüksek Miyop Hastada Her İki Kristal Göz Merceğinin Göz İçine Dislokasyonu: Komplikasyonsuz 40 Yıl

Müge ÇOBAN KARATAŞ,^a
Aysel PELİT^a

^aDepartment of Ophthalmology,
Başkent University Adana
Dr. Turgut Noyan Training and
Medical Research Center,
Adana

Geliş Tarihi/Received: 01.06.2015
Kabul Tarihi/Accepted: 15.08.2015

*This case report was presented at
2012 ASCRS-ASOA Annual Symposium &
Congress, 20-24 April 2012, Chicago, USA.*

Yazışma Adresi/Correspondence:
Müge ÇOBAN KARATAŞ
Başkent University Adana
Dr. Turgut Noyan Training and
Medical Research Center,
Department of Ophthalmology, Adana,
TÜRKİYE/TURKEY
bkaratas99@hotmail.com

ABSTRACT We report of 50-year-old woman referred to our clinic for routine ophthalmic examination. She did not report any ocular trauma and surgery. Her anterior segment examination revealed bilateral aphakia and iridodonesis. Her intraocular pressures were in normal ranges in both eyes. Fundoscopic examination revealed bilateral posteriorly dislocated lenses into the vitreous body. In addition, her fundoscopic examination revealed tilted disk, peripapillary atrophy and degenerative myopic changes. There was no lens induced posterior uveitis in either eye. Axial length in the right eye was 26.90 mm and in the left eye 27.95 mm. Her physical and cardiologic examination revealed no pathology. Our patient did not accept any surgical intervention.

Keywords: Myopia, degenerative; lens subluxation

ÖZET Olgumuz, 50 yaşında kadın hasta göz muayenesi için kliniğimize başvurdu. Oküler travma ve cerrahi hikayesi yoktu. Ön segment muayenesinde her iki gözde afaki ve iridodonesis gözlemlendi. Göz içi basıncı her iki gözde normal sınırlardaydı. Göz dibi muayenesinde her iki göz merceğinin, herhangi bir inflamasyon bulgusu olmadan göz içine vitreusa disloke olduğu tespit edildi. Göz dibi muayenesinde ayrıca, eğik optik sinirler, optik sinir çevresinde atrofik değişiklikler, dejeneratif miyopik değişiklikler mevcuttu. Her iki gözde de kristal merceğe bağlı arka üveit bulgusu gözlenmedi. Sağ gözün aksiyel uzunluğu 26,90 mm, sol gözün ise 27,95 mm idi. Hastamızın fizik ve kardiyolojik muayenesinde herhangi bir patoloji gözlenmedi. Hastamız herhangi bir cerrahi müdahaleyi kabul etmedi.

Anahtar Kelimeler: Miyopi, dejeneratif; lens kayması

Trauma is the leading cause of dislocation or subluxation of the crystalline lens.¹ Blunt trauma is believed to lead to equatorial expansion, which may disrupt the zonules and lead to lens dislocation or subluxation.² Patients with some systemic conditions like Marfan syndrome, Ehler-Danlos syndrome and high myopia may be prone to lens dislocation or subluxation even with minor ocular trauma.

We present a high myopic patient with posterior dislocation of crystalline lens into the vitreous cavity for a long duration without vitreous inflammation. To the best of our knowledge this is the first case of high myopia with bilateral posterior lens luxation without complication for 40 years duration.

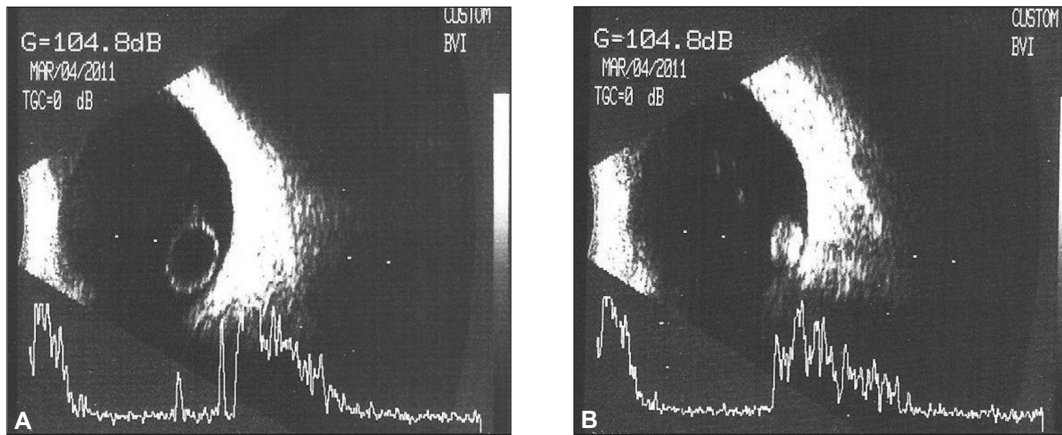


FIGURE 1A, B: b-mode ultrasonography revealed bilateral posteriorly dislocated lenses into the vitreous body in both eyes.

CASE REPORT

A 50-year-old woman referred to our clinic for routine ophthalmic examination. There was no history of pain, trauma and ocular surgery.

Ophthalmologic examination revealed best corrected visual acuity of 20/200 (-3.0, -1.50 175) in her right eye and 20/100 (-4.5, -2.0 160) in her left eye. Intraocular pressure was 12 mmHg in both eyes. Slit-lamp examination revealed bilateral aphakia and iridodonesis. There were no cells or flare in anterior chamber. Fundus examination and b-mode ultrasonography revealed bilateral posteriorly dislocated lenses into the vitreous body (Figure 1A, 1B, 2). Fundus photography revealed tilted disks, peripapillary atrophy and degenerative myopic changes without vitreous inflammation (Figure 3A, 3B). There was no lens induced posterior uveitis in either eye. Axial length in the right eye was 26.90 mm and in the left eye 27.95 mm. Her physical and cardiologic examination revealed no pathology.

In her anamnesis she mentioned that she was wearing thick spectacles until she was 10-years-old. Then her spectacles changed and became a lot more thinner and comfortable. We assumed that posterior lens dislocation occurred 40 years ago. However no sign of lens induced uveitis was observed. Our patient did not accept any surgical intervention.

DISCUSSION

Dislocation of the crystalline lens into the vitreous cavity or into the anterior chamber rarely may occur. It usually occurs following trauma, but may be spontaneous.

Trauma is the leading cause of dislocation or subluxation of the crystalline lens.¹ Lens dislocation may less frequently be due to hereditary, systemic conditions (Marfan syndrome, Weil-Marchesani syndrome) acquired cases such as pseudoexfoliation syndrome, myopia, following severe uveitis or even spontaneously.³⁻⁷

El Gendy et al., reported a patient with high myopia who, after minor forehead trauma, developed an isolated rupture of the posterior capsule with probable complete prolapse of the crystalline

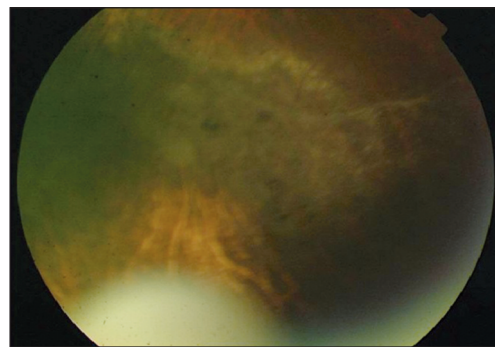


FIGURE 2: Fundus examination revealed posteriorly dislocated lens into the vitreous body.

(See color figure at <http://www.turkiyeklinikleri.com/journal/oftalmoloji-dergisi/1300-0365/>)

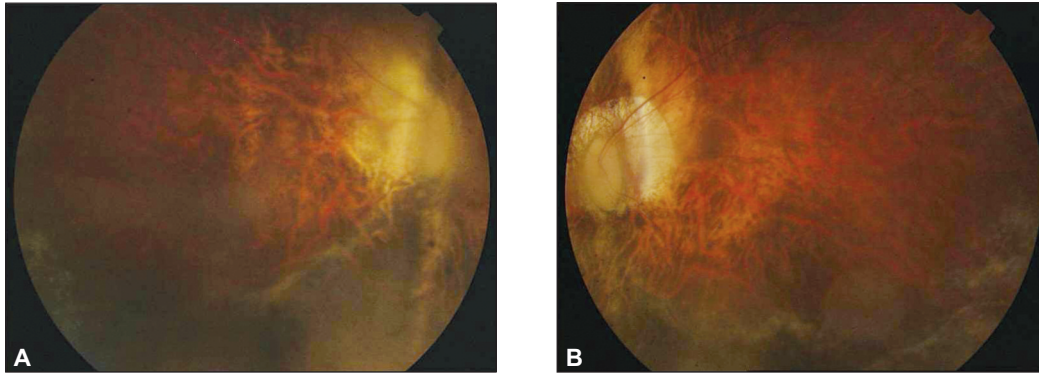


FIGURE 3A, B: Fundus photography revealed tilted disk, peripapillary atrophy and degenerative mopic changes without vitreous inflammation.

(See color figure at <http://www.turkiyeklinikleri.com/journal/oftalmoloji-dergisi/1300-0365/>)

lens into the vitreous cavity, leading to spontaneous correction of the patient's high axial myopia.⁸

Several previous reports have been documented spontaneous dislocation of the lens to the anterior chamber or into the vitreous body in patients with Marfan Syndrome and blunt ocular trauma.^{5,9,10} Lens induced uveitis is triggered by an immune response to lens proteins following rupture of the lens capsule, which may be due to trauma or incomplete cataract extraction.¹¹

Our patient had none of the known systemic conditions. She suffered from high myopia. She

mentioned that her vision improved when she was 10-years-old. We assumed that she might have a blunt trauma when she was a child which may be the cause of dislocation of both crystalline lenses into the vitreous body. Interestingly until now she did not suffer from lens induced uveitis.

Conflict of Interest

Authors declared no conflict of interest or financial support.

Authorship Contributions

Both authors contributed in the concept, design, data collection, interpretation, literature search and writing of the article.

REFERENCES

- Jarrett WH II. Dislocation of the lens. A study of 166 hospitalized cases. *Arch Ophthalmol* 1967;78(3):289-96.
- Marcus DM, Topping TM, Jr Frederick AR Jr. Vitreoretinal management of traumatic dislocation of crystalline lens. *Int Ophthalmol Clin* 1995;35(1):139-50.
- Malbran ES, Croxatto O, D'Alessandro C, Charles DE. Genetic spontaneous late subluxation of the lens-a study of two families. *Ophthalmology* 1989;96(2):223-9.
- Nelson LB, Maumenee IH. Ectopia lentis. *Surv Ophthalmol* 1982;27(3):143-60.
- Pelit A, Akova YA. Spontaneous posterior dislocation of both lenses in a patient with Marfan's syndrome: 17 years without complication. *Int Ophthalmol* 2005;26(1-2):49-51.
- Belfort R Jr, Nussenblatt RB, Lottemberg C, Kwitko S, Chamon W, de Smet M, et al. Spontaneous lens subluxation in uveitis. *Am J Ophthalmol* 1990;110(6):714-6.
- Bass LJ, Potter JW. A case of spontaneous dislocated lenses. *Am J Optom Physiol Opt* 1985;62(5):352-6.
- El-Gendy A, Rahman I, Mahmood U, Nyländer A. Traumatic rupture of the posterior capsule resulting in complete posterior prolapse of the lens with subsequent resolution of high myopia. *J Cataract Refract Surg* 2006;32(5):893-4.
- Garza-Leon M, de la Parra-Colin P. Medical treatment of crystalline lens dislocation into the anterior chamber in a patient with Marfan syndrome. *Int Ophthalmol* 2012;32(6):585-7.
- Schäfer S, Spraul CW, Lang GK. [Spontaneous dislocation to the anterior chamber of lens luxated in the vitreous body: two cases]. *Klin Monbl Augenheilkd* 2003;220(6):411-3.
- Kanski J, Bowling B. *Uveitis. Clinical Ophthalmology: A Systemic Approach*. 7th ed. Edinburgh; New York : Elsevier/Saunders, 2011. p.469-71.