

# A Fistula Laying Between Left Coronary Artery and Pulmonary Vein as a Rare Congenital Cardiovascular Malformation: Case Report

## Nadir Bir Doğumsal Kalp Anomalisi Olarak Sol Koroner Arter ile Pulmoner Ven Arasında Bulunan Fistül

Ayhan PEKTAŞ,<sup>a</sup>  
Ayhan ÇEVİK,<sup>b</sup>  
Erman ÇİLSAL,<sup>c</sup>  
Serdar KULA,<sup>c</sup>  
Ayşe Deniz OĞUZ<sup>c</sup>

<sup>a</sup>Department of Pediatric Cardiology,  
Afyon Kocatepe University

Faculty of Medicine, Afyonkarahisar

<sup>b</sup>Clinic of Pediatric Cardiology,

Dr. Siyami Ersek Chest, Heart and  
Cardiovascular Surgery Training and  
Research Hospital, İstanbul

<sup>c</sup>Department of Pediatric Cardiology,  
Gazi University Faculty of Medicine,  
Ankara

Geliş Tarihi/Received: 27.01.2013

Kabul Tarihi/Accepted: 31.10.2013

Yazışma Adresi/Correspondence:

Ayhan PEKTAŞ

Afyon Kocatepe University

Faculty of Medicine,

Department of Pediatric Cardiology,

Afyonkarahisar,

TÜRKİYE/TURKEY

drayhanpektas@hotmail.com

**ABSTRACT** This case report aimed to describe a child who is incidentally diagnosed with a coronary artery fistula. Transthoracic echocardiography showed that the left coronary artery outlet was wider than normal (4.4 mm) and a diastolic flow with a maximum velocity of 2.5 m/sec existed at the parasternal short axis in an asymptomatic 12-year-old boy who was referred to the study center due to a continuous aortic murmur. Coronary angiography confirmed that a fistula originating from the main left coronary artery opened into the left upper pulmonary vein. Close clinical follow up was recommended for the patient since his cardiac enzymes and treadmill testing were within the normal range. Coronary artery fistulas should be considered in differential diagnosis of childhood cardiac murmurs.

**Key Words:** Arteriovenous fistula; coronary vessels; pulmonary veins

**ÖZET** Bu yazıda, nadir görülen ve sessiz seyredabilen bir doğumsal damar anomalisi olan koroner arter fistülü tanımlanmıştır. Herhangi bir yakınması olmayan 12 yaşındaki erkek hastanın aort odağında devamlı üfürüm duyuldu. Transtorasik ekokardiyografi incelemesinde, sol ana koroner arter çıkışının geniş olduğu (4,4 mm), sol koroner arter ile sol superior pulmoner ven arasında belirgin bir mozaiklenme olduğu ve hızı 2,5 m/sn'ye ulaşan diastolik bir akımın bulunduğu saptandı. Koroner anjiyografide ise sol ana koroner arterden köken alan fistülün sol üst pulmoner vene açıldığı gözlemlendi. Kardiyak enzimleri ve egzersiz stres testi normal olarak değerlendirilen hastaya düzenli klinik takip önerildi. Üfürüm dışında herhangi bir klinik belirtisi olmayan çocuklarda, ekokardiyografi incelemesi yapılırken koroner arter fistül açısından dikkatli olunması gerektiği vurgulanmıştır.

**Anahtar Kelimeler:** Arteriyovenöz fistül; koroner damarlar; akciğer venleri

**Türkiye Klinikleri J Pediatr 2014;23(3):116-9**

Coronary artery fistulas are the rarely encountered anomalies of the coronary arteries. They may be either congenital or acquired. Coronary artery fistulas are mostly situated between the coronary arteries and either cardiac chambers or prominent vascular structures. More than 90% of these fistulas originate from the right coronary artery and the remaining 10% start from the left coronary artery. As coronary artery fistulas seldom rarely cause clinical symptoms, they usually remain undefined.<sup>1,2</sup>

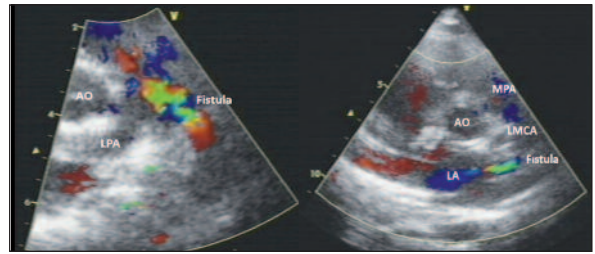
This case report describes a 12 year old boy who was diagnosed with a fistula lying between the main left coronary artery and left upper pulmonary vein. To the best of our knowledge, this manuscript is the first

documentation of a child with a congenital fistula lying between coronary artery and pulmonary vein.<sup>3</sup> The present case report aimed to point out that coronary artery fistulas should be considered in the differential diagnosis of cardiac murmurs. Another purpose is to remind that echocardiographic assessment should be a part of clinical work up in children with cardiac murmurs even if there were no clinical symptoms and/or signs.

## CASE REPORT

An asymptomatic 12-year-old boy was admitted to the department of pediatric cardiology at the study center for routine checkup. It was revealed that the child had been admitted to another tertiary health care center due to an upper respiratory tract infection when he was four years old. At that time, a cardiac murmur had been auscultated during the physical examination and echocardiography was performed. A dilated left coronary artery had been visualized by echocardiography, and subsequently, tomography coronary angiography had been accomplished. It had been reported that there was a fistula extending between the left coronary artery and the pulmonary vein. It was also learnt that the patient then had been put under close clinical surveillance and neither medical nor surgical treatment had been administered.

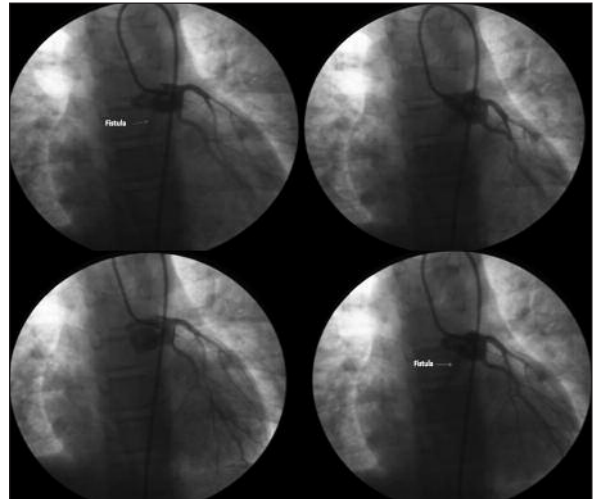
Physical examination at the study center indicated a continuous cardiac murmur at the aortic focus. Transthoracic echocardiography was unable to demonstrate any systolic dysfunction at the left ventricle. Moreover echocardiographic assessment of the cardiac walls and chambers was considered to be normal. However, the diameter of the left coronary artery outlet was measured to be wider than normal (4.4 mm). In addition, a diastolic flow with a maximum velocity of 2.5 m/sec was detected by echocardiography at the parasternal short axis (Figure 1). Multidetector computed tomography (CT) coronary angiography showed that a 15 mm long and a 4.9 mm large (at its widest point) fistula extended between the left coronary artery and the pulmonary vein. Three-dimensional CT angiography could not be performed due to technical inadequacy of the study center.



**FIGURE 1:** Echocardiography showed a diastolic flow with a maximum velocity of 2.5 m/sec at the parasternal short axis.

(See color figure at <http://www.turkiyeklinikleri.com/journal/pediatri-dergisi/1300-0381/>)

AO: Aorta; LA: Left atrium; LMCA: Left major coronary artery; LPA: Left pulmonary artery; MPA: Main pulmonary artery.



**FIGURE 2:** Coronary angiography designated that the contrast agent injected through the left coronary artery filled the fistula tract initially, and then the left atrium and left ventricle respectively.

Coronary angiography was also carried out and it was confirmed that a fistula originating from the main left coronary artery opened into the left upper pulmonary vein. That is, it was designated that the contrast agent injected through the left coronary artery filled the fistula tract initially, and then the left atrium and left ventricle respectively (Figure 2).

There was nothing particular in the telecardiography of the patient and his electrocardiogram treadmill testing was considered to be normal. Serum concentrations of cardiac enzymes were within the normal range: creatine kinase: 120 U/L (range: 30-150 U/L), creatine kinase-MB: 1.0 µg/L (range: 0-1.7 µg/L) and troponin I: 0.018 µg/L (range: <0.1 µg/L).

Since the patient was asymptomatic and had normal cardiac functions, only clinical follow up was scheduled for him. Echocardiography, exercise electrocardiogram stress test and biochemical markers did not indicate any cardiac dysfunction so that myocardial scintigraphy was reserved for the time the patient would become symptomatic or the aforementioned tests would have abnormal results during clinical follow up.

## DISCUSSION

Coronary artery fistulas are mostly situated between coronary arteries and either cardiac chambers or prominent vascular structures.<sup>1,2</sup> The incidence of congenital coronary artery fistulas has been reported as 1:50 000 births. Congenital coronary artery fistulas accompany 0.2% to 0.4% of all heart defects detected after birth.

Previously published studies have demonstrated that nearly half of the congenital coronary artery fistulas originate from the right coronary artery and the other half begins at the left coronary artery. On the other hand, the majority of congenital coronary artery fistulas open into the right heart. That is, 41% of these fistulas drain into the right ventricle and 26% of them open into the right atrium. Moreover, 17% of these fistulas join pulmonary artery, 7% of them open into the coronary sinus and approximately 1% of them drain into the superior vena cava.<sup>4,5</sup> A case report by Cetin et al. described a congenital arteriovenous fistula lying between left descending coronary artery and main pulmonary artery in a pediatric subject.<sup>6</sup>

Coronary artery fistulas are generally asymptomatic.<sup>6,7</sup> These fistulas rarely present with dyspnea, chest pain and dysrhythmias which may require treatment. It has been reported that thin calibrated fistulas usually remain silent whereas thick calibrated fistulas may cause a left-to-right shunt which may eventually lead to heart failure. Sometimes coronary artery fistulas may give rise to coronary artery steal syndrome which is related with myocardial ischemia and infarction. Occasionally coronary artery fistulas may lead to infec-

tive endocarditis, hemopericardium and even sudden death.<sup>7</sup>

As coronary artery fistulas are frequently asymptomatic, most of them are diagnosed incidentally. Such an incidental diagnosis usually takes place while children with continuous cardiac murmurs are examined by echocardiography.<sup>6</sup> Whenever coronary artery fistulas are identified during echocardiographic examination, their origin, insertion, calibration and size should be specified.<sup>8</sup>

The management of coronary artery fistulas involves surgical closure in patients with the existence of cardiac dysfunction, myocardial ischemia and/or heart failure. It has been claimed that prophylactic closure of coronary artery fistulas can be considered in children with high shunt ratio even if they had no clinical symptoms or signs.<sup>6,9</sup> Surgical repair of the coronary artery fistulas may be implemented by either epicardial or endocardial techniques which are reported to be equally reliable, efficient and valid. Recently transcatheter closure has become the widely accepted method of treatment for coronary artery fistulas because catheterization reduces the hospital cost, shortens the hospital stay and improves the surgical results.<sup>8</sup>

The present case report describes a child who does not have any clinical symptoms or signs other than a continuous cardiac murmur at the aortic focus. Since no cardiovascular problems occurred during the last eight years and cardiac functions were assessed to be normal, only clinical follow up with regular intervals was recommended for the patient. Despite this conservative approach, surgical closure may be planned in case his clinical symptoms worsen and/or systolic functions become impaired. Due to the absence of any clinical symptoms and functional disorder, a similar conservative approach was also adopted for the pediatric case that was described by Cetin et al.<sup>6</sup>

To the best of our knowledge, the present manuscript is the first to report about the diagnosis of a congenital coronary fistula lying between the left main coronary artery and pulmonary vein

during childhood.<sup>3</sup> The present case report aimed to remind the clinicians of this rarely encountered cardiovascular abnormality which usually remains asymptomatic. The children with cardiac murmurs should undergo a detailed echocardiographic ex-

amination and coronary artery fistulas should be featured in the differential diagnosis of cardiac murmurs in children. Further research is warranted to clarify the clinical outcomes associated with congenital coronary artery fistulas.

## REFERENCES

1. Mangukia CV. Coronary artery fistula. *Ann Thorac Surg* 2012;93(6):2084-92.
2. Rippel RA, Kolvekar S. Coronary artery fistula draining into pulmonary artery and optimal management: a review. *Heart Asia* 2013; 5(1):16-7.
3. Doganay S, Bozkurt M, Kantarci M, Erkut B. Coronary artery-pulmonary vein fistula diagnosed by multidetector computed tomography. *J Cardiovasc Med (Hagerstown)* 2009;10(5): 428-30.
4. Sunder KR, Balakrishnan KG, Tharakan JA, Titus T, Pillai VR, Francis B, et al. Coronary artery fistula in children and adults: a review of 25 cases with long-term observations. *Int J Cardiol* 1997;58(1):47-53.
5. Schumacher G, Roithmaier A, Lorenz HP, Meisner H, Sauer U, Müller KD, et al. Congenital coronary artery fistula in infancy and childhood: diagnostic and therapeutic aspects. *Thorac Cardiovasc Surg* 1997;45(6): 287-94.
6. Çetin M, Yıldırım M, Evrengül H, Özen S, Genç B, Coşkun Ş. [Coronary artery-pulmonary artery fistula detected by transthoracic echocardiography: Case report]. *Türkiye Klinikleri J Pediatr* 2012;21(3):197-200.
7. Gowda RM, Vasavada BC, Khan IA. Coronary artery fistulas: clinical and therapeutic considerations. *Int J Cardiol* 2006;107(1):7-10.
8. Xu L, Xu ZY, Jiang SL, Zheng H, Zhao SH, Ling J, et al. Transcatheter closure of coronary artery fistula in children. *Chin Med J (Engl)* 2010;123(7):822-6.
9. Yaşa H, Arıkan ME, Tetik Ö, Lafçı B, Bademci M, Güneş T, et al. Coronary artery fistulas in adult period. *Türkiye Klinikleri J Med Sci* 2008;28(6):886-91.