




# Anesthetic Approach and Literature Review in a Patient with Fraser Syndrome

## Fraser Sendromlu Hastada Anestezik Yaklaşım ve Literatür Taraması

 Hilmi DEMİRKIRAN<sup>a</sup>,  
 Arzu ESEN TEKELİ<sup>a</sup>,  
 Veli AVCI<sup>b</sup>

Departments of

<sup>a</sup>Anesthesiology and Reanimation,

<sup>b</sup>Pediatric Surgery,

Van Yüzüncü Yıl University

Faculty of Medicine,

Van, TURKEY

Received: 09 May 2019

Received in revised form: 23 Jul 2019

Accepted: 26 Aug 2019

Available online: 04 Sep 2019

Correspondence:

Veli AVCI

Van Yüzüncü Yıl University

Faculty of Medicine,

Department of Pediatric Surgery, Van,

TURKEY/TÜRKİYE

veliavci\_21@hotmail.com

This study was presented orally at the 22<sup>nd</sup> International Intensive Care Symposium 3,4 May 2019, İstanbul, Turkey.

**ABSTRACT** Fraser syndrome is a rare, autosomal recessive genetic disorder. Among the frequent findings there are cryptophthalmus, fusion on eyelids, focal hearing loss and/or external and middle ear anomalies, syndactyly on the hands and/or toes, genitourinary anomalies (renalagenesis-hypoplasia, micropenis, uterus bicornus, clitoromegaly, cryptorchidism, hypospadias etc.). Also multiple anomalies such as flattened nasal roots, cleft palate, and/or lips can be seen. Likelihood of laryngeal stenosis/atresia and lung problems are common in these patients. And these abnormalities lead to inspiratory difficulty, perhaps death. Some cases are diagnosed by difficult intubation or unsuccessful entubation. Herein we presented a patient with Fraser syndrome who was planned to undergo an operation due to acute abdomen. The possibility of difficult airway and the clinical situation was discussed in the light of the literature.

**Keywords:** Fraser syndrome; impossible tracheal intubation; glottic stenosis

**ÖZET** Fraser sendromu nadir bir otozomal resesif geçişli genetik hastalıktır. Sık görülen bulgular kriptoftalmus, göz kapaklarını füzyonu, fokal işitme kaybı ve/veya dış ve orta kulak anormallikleri, ellerde ve/veya ayak parmaklarda sindaktili, genitoüriner anomaliler (renal agenezi-hipoplazi, mikropenis, uterus bikornus, klitoromegali, kriptorşidizm, hipospadias vb)dir. Ayrıca düz burun kökü, yarı damak ve/veya dudak da görülebilir. Bu hastalarda laringeal stenoz/atrezi ve akciğer problemleri görülme olasılığı yüksektir. Bu anormallikler solunum güçlüğüne, belki de ölüme yol açar. Bazı olgular zor veya entübasyon ile tanı alır. Burada akut batın nedeniyle ameliyat edillmesi planlanan bir hastayı sunuyoruz. Zorlu hava yolu olasılığı ve klinik durum literatür ışığında tartışıldı.

**Anahtar Kelimeler:** Fraser sendromu; imkansız trakeal entübasyon; glottik darlık

The main principles of anesthesia practice is to develop a plan to determine the characteristics of the difficult airway and to manage the airway problems.<sup>1</sup> Foreseeing difficult airway in children can provide effective airway management. There is limited evidence for the recognition of difficult airways in children.<sup>2</sup> A reasonable approach can be developed by using evidence from the operating room and clinical experience. Patients with Fraser sendrom may have features that may complicate airway management.<sup>3</sup> In this article, anesthesia management in a pediatric patient with Fraser syndrome is presented and discussed under the light of literature.

### CASE REPORT

A 3-years-old girl with mental retardation who was born with normal vaginal route as the 3<sup>rd</sup> child of the mother and father who had no kinship

was brought to the emergency clinic for complaints of nausea, vomiting and abdominal pain. Physical examination, mallampati I, facial asymmetria, the distance between forehead and both eyes was wide and there was fusion in eyelids (Figure 1). Both hands and the right foot were syndactylated, in genital system vaginalgenesis, clitoromegaly and labial fusion were observed. Biochemical parameters were normal. On radiological examination; air-liquid level in chest x-ray, left ovarian agenesis, left renal agenesis and right renal grade II parenchymal damage on were detected abdomen tomography. There was bowel malrotation and the caecum was detected in the left lower quadrant. Preoperative and preanesthesia examinations were performed and 1 mg midazolam was administered via intra-venous route in the operating room.

Electrocardiography (ECG) monitorization, peripheral oxygenation with pulse oximetry and non invasive blood pressure measurement were done. Number 4 endotracheal tube with cuff was prepared with a guide. Between number 3 to 5 cuffed and non cuffed tubes, LMAs between number 1-2.5 and pediatric fiberoptic bronchoscope were kept in the operating room. After 3 minutes preoxygenation with 10L/min oxygen rapid serial intubation was done with 1 mg/kg propofol, 1 mg/kg rocuronium and 1 µcg/kg

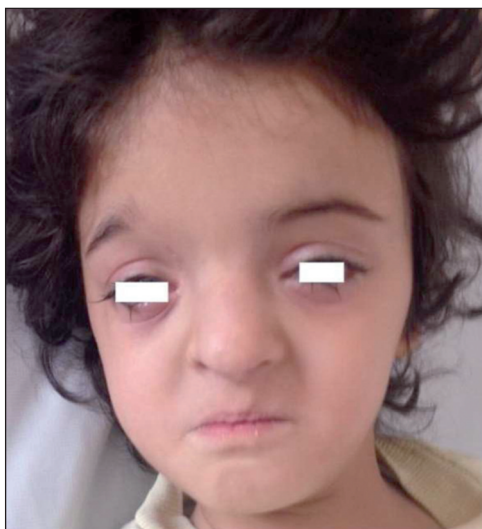

FIGURE 1: Wide forehead and fusion in the eyelids.

fentanyl to the patient who had mallampati I and whose mouth open was comfortable. There were no problems during entubation. 2.5 MAC sevoflurane was used for anesthesia maintenance. 4 mg/kg sugammadex was used for extubation.

Volvulus was observed after midline incision under general anesthesia and bowel obstruction was evaluated. Caecum was seen as mobile. There were ladd bands between terminal ileum and colon. The colon was enlarged to fill the entire part of the pelvis and the middle part of the abdomen and was observed to be filled with dark consistency gaita. Stone fecaloids were seen in the rectum and hypoperistaltic intestines were detected. Stoma was created in the patient who underwent ileocaecal resection. The left kidney and the left ovary could not be seen during surgery.

Informed consent was obtained from the legal guardian of individual participant for publication of the paper.

## DISCUSSION

Fraser syndrome is a rare, autosomal recessive disorder characterized by multiple anomalies. It was first described by George Fraser in 1962.<sup>4</sup> Presence in the majority of consanguineous marriages and observation in more than one child in the same family indicates autosomal recessive inheritance.<sup>5</sup> Approximately the incidence is 0.043/10,000 in live births and 1.1/10,000 in in-utero deaths.<sup>6</sup> It is clinically diagnosed with eye problems such as cryptophthalmus, lacrimal canal problems, hypertelorism and blindness, structural disorders such as ear structures and/or dysfunctions, nasal obstruction, hypoplastic and notched nose wings, facial anomalies such as cleft palate and/or lip, laryngeal anomalies, renal problems, skeletal anomalies, umbilical hernia, and mental retardation.<sup>7,8</sup> With no clear pathogenesis, it is thought because of a migration defect of neural crest cells, apoptosis inadequacy, and retinoid metabolism defect.<sup>9</sup>

Thomas et al. determined the major and minor criteria used in the diagnosis of Fraser syndrome.<sup>5</sup> However, these criteria were later revised by Van

Haelst et al. according to the new patient series, not according to the patient scan results.<sup>10</sup> Our patient met 4 major criteria and 3 minor criteria (Table 1).

In the case of Fraser syndrome, prenatal tests are important. DNA analysis and advanced tests are helpful in prenatal diagnosis. Berg et al. stated that some ultrasonographic findings may be indicative of Fraser syndrome. Among the prenatal findings; polyhydramnios in the case of oesophageal atresia, oligohydramnios in the case of renal agenesis, hyperechogenic image in the lungs in the case of laryngeal atresia, syndactyly, suspicious genitalia, microphthalmia, ascites, renal agenesis/dysplasia may be seen.<sup>7</sup>

Cryptophthalmus is the most unique finding of Fraser syndrome and found in 80% of the cases.<sup>6</sup> Cryptophthalmus has complete, incomplete and symblefaron forms and may be symptomatic or asymptomatic. It is the most common complete form.<sup>11</sup> In our case, incomplete form was observed together with discrete eyebrow structure.

In a study by Gorlin et al. 85% of cryptophthalmic infants were reported to have laryngeal stenosis.<sup>3</sup> Death in Fraser syndrome is usually associated with renal agenesis and laryngeal stenosis.<sup>12</sup> In the case of laryngeal atresia or stenosis the fluid which is released by the fetal lung and has an important role in lung development, can not be

thrown sufficiently into the amnion wax and the lung development is not complete. If this transition is possible pulmonary development is partly normal, as is our cases. We have made necessary preparations for the possibility of laryngeal stenosis but this has not happened. However, in this syndrome, coanal stenosis/atresia, tracheal atresia, hypoplastic epiglottis, subglottic stenosis and diaphragm anomalies have also been reported in the respiratory system.<sup>13</sup>

In Fraser syndrome, adherence of the hands or toes (syndactyly) occurs in 60% of cases. In 50% of the cases, there is a syndactyly in the fingers and toes.<sup>9,12</sup> In our case, both hand and right foot are attracting attention with syndactyly.

Although Fraser syndrome can be seen in both gender, it is more common among girls. It can be repeated in the ratio of 25% in consecutive pregnancies and 25% post-stillbirth.<sup>7,13</sup> Ambiguous genitalia is often. Clitoromegaly, hypoplastic uterus, hydrometrocolpos, adhesion on labiums, uterusbicornis, vaginal agenesis or hypoplasia, imperforate vagina; in men micro penis, hypospadias, scrotal hypoplasia can be seen.<sup>12,14</sup> In our case, vaginal agenesis, clitoromegaly and labial fusion were observed.

Our patient had left renal agenesis and 37% of cases have renal agenesis.<sup>8</sup> However, bladder

**TABLE 1:** Diagnostic criteria of Fraser syndrome the findings of our patient.

Major criteria	Case
Cryptophthalmos and ocular findings	+ (fusion in the eyelids and distance between the two eyebrows)
Syndactyly	+ (both hands and right foot)
Urinary system anomaly	+ (left renal agenesis, right renal grade II parenchymal damage)
Ambiguous genitalia	+ (clitoromegaly and labial fusion)
Family history	-
Minor criteria	Case
Ear deformities, auditory problems	-
Anorectal malformations	+ (bowel malrotation)
Nose anomaly	+ (flat nasal bridge)
Respiratory tract anomalies	-
Umbilical hernia	-
Cleft palate-lip	-
Mental retardation	+
Defects in skull bones	-

agenesis or small bladder, dysplastic kidney, bilateral renal artery agenesis, pelvic single kidney, renal cysts, hydronephrosis have been reported.<sup>13</sup>

While the most common gastrointestinal anomaly is imperforate anus, bowel malrotation and caecum in the left lower abdomen were seen in our patient. Anal atresia, anal stenosis, umbilical hernia, hiatus hernia, abdominal wall defect, hepatomegaly, ectopic pancreas, duodenal stenosis are the less common findings.<sup>3,13</sup> Maruotti et al. reported some unspecified findings of the gastrointestinal tract in a case with Fraser syndrome and informed researchers that all types of malformations could be seen in families with no family trait.<sup>15</sup>

Approximately 25% of cases with Fraser syndrome lead to death. Life span varies according to the anomalies they have, but 25% are lost in the first year because of renal agenesis or laryngeal stenosis. It has been found that the number of major criteria is very small in cases of more than ten years of life. The survivors have mental retardation at 80% induration.<sup>13</sup>

In conclusion, it is necessary to follow up in pregnancy with regular intervals and Fraser syndrome should be prepared for clinical situations that may come to mind if there is evidence of stimulant findings (oligohydramnios, polyhydramnios) and major criteria in pregnancy at absolute.

In cases with Fraser syndrome, the possibility of difficult airway should be kept in mind, the anesthesia process must be managed correctly, and the patient should be monitored taking into account the possibility of surgical tracheostomy in the perioperative system.

#### Source of Finance

*During this study, no financial or spiritual support was received neither from any pharmaceutical company that has a direct connection with the research subject, nor from a company that provides or produces medical instruments and materials which may negatively affect the evaluation process of this study.*

#### Conflict of Interest

*No conflicts of interest between the authors and / or family members of the scientific and medical committee members or members of the potential conflicts of interest, counseling, expertise, working conditions, share holding and similar situations in any firm.*

#### Authorship Contributions

**Idea/Concept:** Hilmi Demirkiran, Arzu Esen Tekeli, Veli Avcı; **Design:** Hilmi Demirkiran, Arzu Esen Tekeli, Veli Avcı; **Control/Supervision:** Hilmi Demirkiran, Arzu Esen Tekeli, Veli Avcı; **Data Collection and/or Processing:** Hilmi Demirkiran, Arzu Esen Tekeli, Veli Avcı; **Analysis and/or Interpretation:** Hilmi Demirkiran, Arzu Esen Tekeli, Veli Avcı; **Literature Review:** Hilmi Demirkiran; **Writing the Article:** Hilmi Demirkiran, Arzu Esen Tekeli, Veli Avcı; **Critical Review:** Hilmi Demirkiran, Veli Avcı; **References and Fundings:** Arzu Esen Tekeli, Veli Avcı; **Materials:** Veli Avcı, Arzu Esen Tekeli.

## REFERENCES

1. Apfelbaum JL, Hagberg CA, Caplan RA, Blitt CD, Connis RT, Nickinovich DG, et al. Practice guidelines for management of the difficult airway: an updated report by the American Society of Anesthesiologists Task Force on Management of the Difficult Airway. *Anesthesiology*. 2013;118(2):251-70. [Crossref] [PubMed]
2. Pallin DJ, Dwyer RC, Walls RM, Brown CA 3rd. Techniques and trends, success rates, and adverse events in emergency department pediatric intubations: a report from the national emergency airway registry. *Ann Emerg Med*. 2016;67(5):610-5. [Crossref] [PubMed]
3. Gorlin RJ, Cohen MM, Levan LJ. Cryptophthalmos syndrome (Fraser syndrome). Syndromes of the head and neck. Oxford Monographs on Medical Genetics. No: 19. 3<sup>rd</sup> ed. New York: Oxford University Press; 1990. p.816-9.
4. Fraser GR. "Our genetical load": review of some aspects of genetical variation. *Ann Hum Genet*. 1962;25:387-415. [Crossref]
5. Thomas IT, Frias JL, Felix V, Sanchez de Leon L, Hernandez RA, Jones MC, et al. Isolated and syndromic cryptophthalmos. *Am J Med Genet*. 1986;25(1):85-98. [Crossref] [PubMed]
6. Narang M, Kumar M, Shah D. Fraser-cryptophthalmos syndrome with colonic atresia. *Indian J Pediatr*. 2008;75(2):189-91. [Crossref] [PubMed]
7. Berg C, Geipel A, Germer U, Pertersen-Hansen A, Koch-Dörfler M, Germbruch U. Prenatal detection of Fraser syndrome without cryptophthalmos: case report and review of the literature. *Ultrasound Obstet Gynecol*. 2001;18(1):76-80. [Crossref] [PubMed]

8. Fryns JP, van Schoubroeck D, Vandenberghe K, Nagels H, Klerckx P. Diagnostic echographic finding in cryptophtalmos syndrome (Fraser syndrome). *Prenat Diagn.* 1997;17(6):582-4. [[Crossref](#)] [[PubMed](#)]
9. Kiran G, Namita G, Dheeraj S. Recurrent Fraser syndrome. *Prenat Diagn.* 2007;27(2):184-5. [[Crossref](#)] [[PubMed](#)]
10. van Haelst MM, Scambler PJ; Fraser Syndrome Collaboration Group, Hennekam RC. Fraser syndrome: a clinical study of 59 cases and evaluation of diagnostic criteria. *Am J Med Genet A.* 2007;143A(24):3194-203. [[Crossref](#)] [[PubMed](#)]
11. Comstock JM, Putnam AR, Opitz JM, Pysher TJ, Szakacs J. Prenatal death in Fraser syndrome. *Fetal Pediatr Pathol.* 2005;24(4-5):223-38. [[Crossref](#)] [[PubMed](#)]
12. Mahadevan B, Bhat BV, Sastri AT, Rao S, Kusre G. Fraser syndrome with unusual features: a case report. *J Anat Soc India.* 2002;51(1):59-60.
13. Slavotinek AM, Tiffet CJ. Fraser syndrome and cryptophtalmos: review of the diagnostic criteria and evidence for phenotypic modules in complex malformation syndromes. *J Med Gen.* 2002;39(9):623-33. [[Crossref](#)] [[PubMed](#)]
14. Chattopadhyay A, Kher AS, Udwadia AD, Sharma SW, Bharucha BA, Nicholson AD. Fraser syndrome. *J Postgrad Med.* 1993;39(4):228-30. [[PubMed](#)]
15. Maruotti GM, Paladini D, Agangi A, Martinelli P. Prospective prenatal diagnosis of Fraser syndrome variant in a family with negative history. *Prenat Diagn.* 2004;24(1):69-70. [[Crossref](#)] [[PubMed](#)]