

Approach of Dental Treatment in Arteriovenous Vascular Malformations Affecting Oral Tissues: Case Report

Oral Dokuları Etkileyen Arteriovenöz Vasküler Malformasyon Vakalarında Dental Tedavi Yaklaşımı

Metin ÇALIŞIR,^a
Aysun AKPINAR,^b
Deniz İŞÇEN^c

^aDepartment of Periodontology,
Adiyaman University Faculty of Dentistry,
Adiyaman

^bDepartment of Periodontology,
Cumhuriyet University
Faculty of Dentistry,
Sivas

^cPrivate Dentist,
İstanbul

Geliş Tarihi/Received: 02.11.2016

Kabul Tarihi/Accepted: 30.01.2017

Yazışma Adresi/Correspondence:

Metin ÇALIŞIR
Adiyaman University Faculty of Dentistry,
Department of Periodontology, Adiyaman,
TURKEY/TÜRKİYE
metincalisir@adiyaman.edu.tr

*This study was presented as a poster at the
Europerio 7 Congress, 6-9 June, 2012, Vienna,
Austria.*

ABSTRACT Large arteriovenous vascular malformations (AVM) of the jaws are relatively rare and potentially life-threatening lesions. When these lesions are not suspected, extraction of teeth or other surgery procedures can be fatal in dentistry. Gingival bleeding seems to be a symptom common to most documented cases. Despite their benign histology, deep lesions can produce serious systemic signs and symptoms due to extensive arteriovenous shunting and soft tissue hypertrophy. Mandibular AVM shows a wide variety of signs and symptoms, such as dental mobility, otalgia, secondary pain due to thrombosis, facial asymmetry, and cosmetic distress. A clinical case report was presented in this study. A 24-year-old girl, seen for gingival bleeding during oral hygiene and facial asymmetry, was found to have a high-flow AVM located around the right mandible. In dental and clinical examination, although she had good oral hygiene, common gingival bleeding was observed. At the mandibular right molar region, non-hemorrhagic, gingival granulomatous swelling was noted. Scaling and root planning and polishing was performed to the teeth carefully. The patient was called maintenance phases. During 2 year, no recurrence of the lesion has been seen. Dentists must always consider the possibility and be able to recognize the clinical signs of AVMs in order to propose proper treatment. Because, AVMs of the maxillofacial region give rise to dental emergencies and may cause disfigurement, morbidity, even death.

Keywords: Vascular malformations; dentistry

ÖZET Çenelerin geniş arteriovenöz vasküler malformasyonları (AVMs) nadir ve yaşamı tehdit eden lezyonlardır. Bu lezyonlar tespit edilemediği zaman, diş çekimi ya da diğer cerrahi işlemler ölümcül olabilir. Çalşılmış vakaların çoğunda dişeti kanaması yaygın bir semptom olarak görülür. Benin histolojisine rağmen, derin lezyonlar yumuşak doku hipertrofisi ve aşırı arteriovenöz damar yumağı nedeniyle ciddi sistemik belirti ve semptomlar gösterir. Alt çene AVM leri kozmetik problemler, fasyal asimetri, trombozis nedeniyle sekonder ağrı, otalji, dişlerde mobilite gibi geniş bir semptom ve belirti spektrumu gösterir. Bu çalışmada klinik bir vaka raporu sunulmuştur. Fasyal asimetri ve oral hijyenik bakım esnasında dişeti kanaması olan 24 yaşındaki kadın hastada sağ mandibula çevresinde yerleşimli yüksek akımlı AVM varlığı tespit edildi. Dental ve klinik muayenede, oral hijyen iyi olmasına rağmen, hastada yaygın dişeti kanaması gözlemlendi. Mandibular sağ molar bölgede, non-hemorajik, granüloamatöz dişeti büyümesi kaydedildi. Dikkatli bir şekilde diş taşı temizliği, kök yüzeyi düzleştirme ve polisaj işlemi uygulandı. Hasta idame fazlarına çağrıldı. İki yıl süresince lezyonda hiç nüks görülmedi. Maksillofasiyal bölgenin arteriovenöz vasküler malformasyonları sıklıkla diş hekimliğinde acil durumlara yol açar ve morbidite ve hatta ölümlerle sonuçlanabilir. AVM ler nadir lezyonlar olmasına rağmen, diş hekimleri bu olasılığı her zaman göz önünde bulundurmalı ve uygun tedavi yaklaşımı için klinik belirtilerini tanıyabilmelidir.

Anahtar Kelimeler: Vasküler malformasyonlar; diş hekimliği

Vascular anomalies are categorized into 2 main types based on the endothelial cell characteristics and clinical behaviors of vascular anomalies: hemangiomas and vascular malformations.¹ Heman-

giomas and vascular malformations are congenital abnormalities of vascular development.² Vascular malformations are subdivided according to the predominant vessel type [e.g. lymphatic, venous malformations, arteriovenous malformations (AVMs)].³ These lesions are usually visible in the skin, mucous membranes and underlying soft tissues. Among the vascular abnormalities, AVMs mainly occur within the head and neck and affect approximately one in 22 children.² AVMs of the head and neck region include soft tissue and intraosseous AVMs.⁴ Intraosseous maxillofacial malformations constitute 50% of all vascular malformations.⁵

AVMs of the head and neck (extra-cranial) are high-flow lesions and the most serious vascular malformations because they have some difficult diagnostic and therapeutic dilemmas in medicine.⁶ AVMs are usually existing at birth. But it may not occur for a while.² They grow throughout life continuously and aggressively as a result of various environmental influences.⁷ Rapid progression may occur during periods of hormonal fluctuations such as puberty, pregnancy, or hormonal therapy, excision and local trauma.⁸ The clinical table can vary from an asymptomatic birthmark to life-threatening congestive heart failure. The main problem is the rarity of these lesions.⁶ AVMs are very destructive and infiltrative lesions. So, they often cause life-threatening secondary to massive bleeding.⁷

Arteriovenous malformations have different histopathologic features.⁹ The pathogenesis of AVMs has still not been explained exactly. It is unknown whether these lesions are congenital or not. Also, the errors in vasculogenesis that cause them are unknown.² Most AVMs occur before the age of 20. They have a history that includes the presence of a vascular blush in the overlying skin at childhood. And then the lesions begin to expand and bleed. The prognosis shows that the vascular lesion grew more rapidly when the patient entered puberty or had other hormonal changes. The next symptoms of AVM growth are bleeding, pain, and tissue destruction. Patients suffer significantly

when the malformation reaches this stage.^{2,8} Sudden onset of pain especially is observed in lesions involving the facial bones. Heat of affected skin has increased. After minor trauma, recurrent bleeding may play a life-threatening role. Destruction of osseous structures is seen in craniofacial arteriovenous malformations.⁸

These anomalies were often misdiagnosed, mismanaged, and poorly understood. Nowadays, many disciplines focus on the treatment of these diseases.² Radiologically, these lesions are seen like diffusion in angiography. Angiography determines the lesion border.^{8,10} Treatment of these lesions is difficult. They are benign lesions but they show recurrence. Therefore wide resection is required.^{5,8} Selective arteriography and embolization were first mentioned in 1977 for these lesions. Treatment can be planned as selective embolization, surgical intervention and combined treatment. Angiography is necessary before the treatment plan. Because vascular anatomy of facial skeleton is complex.^{8,10}

In the oral cavity, lesions can present at any site, but most commonly occur on anterior two-thirds of the tongue, palate, and gingival and buccal mucosa.² Dentists may be faced with serious bleeding during treatment because of this rare condition. If the treatment is necessary, surely, a specialist should be consulted.

In this paper, we present a case of arteriovenous vascular malformation involving the buccal gingiva and cheek of a 24-year-old male followed by a review of the literature.

CASE REPORT

24 year-old female patient was referred to our clinic with gingival swelling at the right mandibular posterior region and bleeding when brushing teeth. Extraoral examination revealed significant facial asymmetry (Figure 1A).

Medical history of the patient was received. The patient is systemically healthy. No abnormalities were detected on hematological investigations which included a coagulation profile. Laboratory

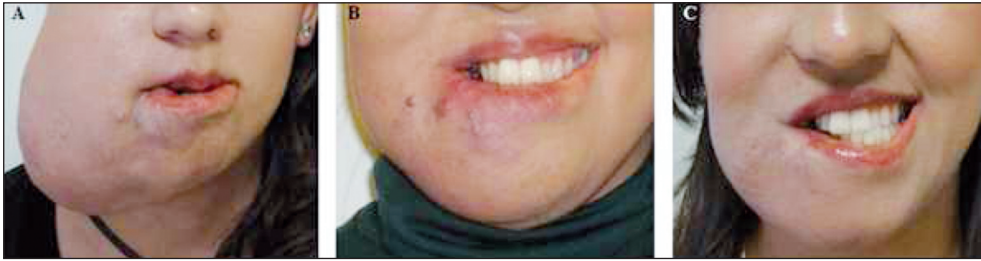

FIGURE 1: A) Soft, tender, pulsatile swelling in right mandibular region and facial asymmetry B) Six months after the selective embolization and total excision of the lesion C) A second attempt to the corner of mouth and the chin after 6 months for aesthetic.

data showed that red blood cell count, white blood cell count, hemoglobin, hematocrit, platelet count, prothrombin time, partial thromboplastin time were normal.

After clinical examination, a mass was detected at the right part of the gingiva and the cheek area (Figures 2A-C). Though gingiva seems clinically healthy, moderate bleeding was observed at

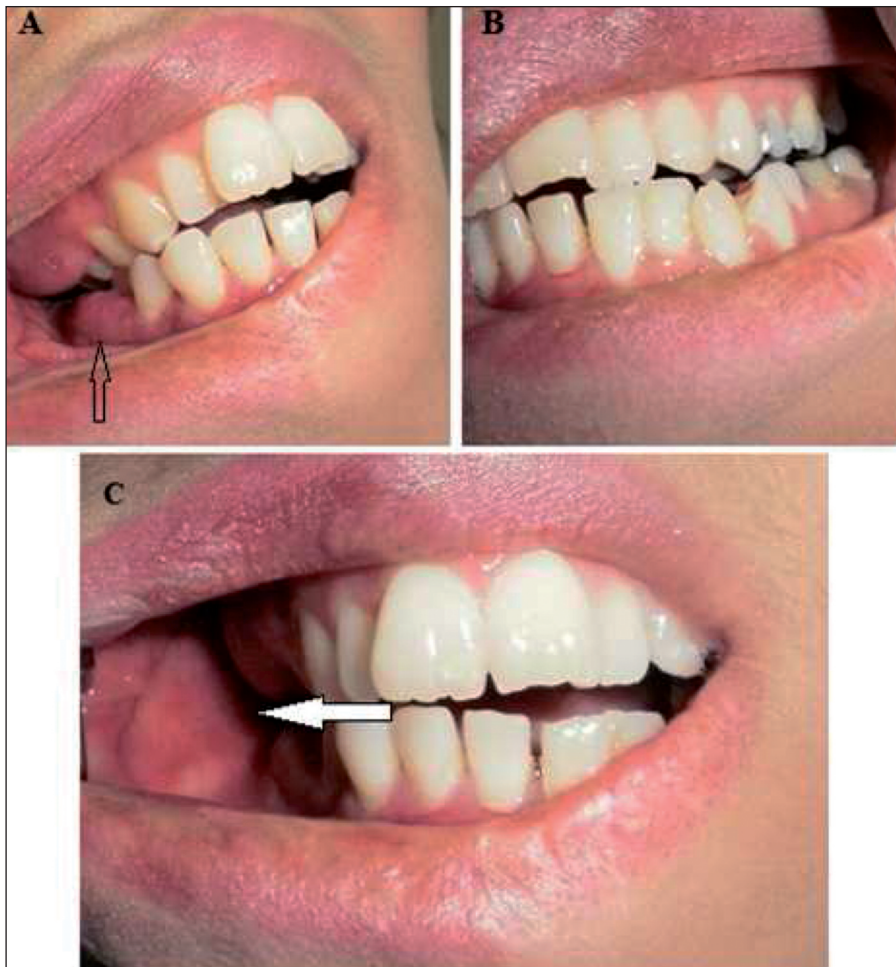


FIGURE 2: Intraoral photography shows that A) A mass detected at the mandibular right posterior gingiva B) Mandibular left posterior gingiva is seen normally C) A mass detected at the cheek area.

slightest provocation of gingiva at the right part of the gingiva. The mass at the gingiva and cheek area which put pressure on the posterior teeth cause corruption of the occlusal arch. Depending on the movements of the teeth, an increase was detected in the opening of the periodontal ligament after radiographic examination. And the periradicular radiolucency was seen at the mandibular right first molar (Figure 3). But there was no symptom in that teeth. She has good oral hygiene periodontally. There was no calculus around the teeth. Although there was slightly plaque around the gingival sulcus, there was moderate bleeding at the affected site. Whereas there was no bleeding at the other sites. Gingival bleeding that has been seen only affecting area was thought a different pathology suspicion to us.

The patient underwent an angiogram and a computerized tomography (CT) scan to further confirm the diagnosis of AVM by a specialist (Figure 4). The angiogram demonstrated the presence of several arteries feeding the vascular intra-buccal lesion. The CT scan showed the presence of a radiolucent lesion in the right mandible. As a result of angiography and computerized tomography, the patient was diagnosed with high-flow AVM. Skin invasion and maxillomandibular deformity

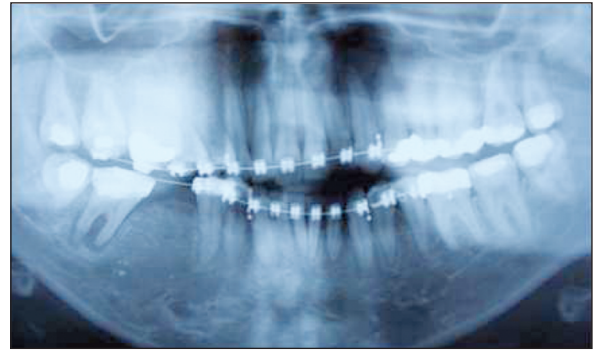


FIGURE 3: Preoperative orthopantomogram radiography showing corruption of the occlusal arch on the posterior teeth and periradicular radiolucency at the mandibular right first molar.

with severe pulsation in the right cheek of the patient were observed.

Surgical procedures for the resection of the AVM lesion was made by a plastic, reconstructive and aesthetic surgeon (DI). Selective embolization with 150 to 350 μ m polyvinyl alcohol (PVA) particles was performed in preparation for surgery. Hypotensive general anesthesia was made providing systolic pressure of approximately 70mmHg. The patient was intubated for airway protection on an emergency basis. After preoperative embolization, a submandibular incision was performed. Dissec-

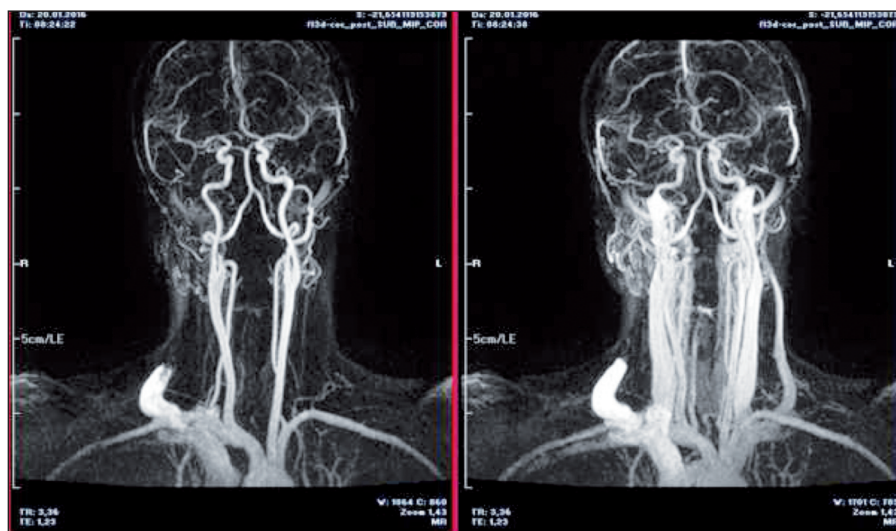


FIGURE 4: MR angiogram scans showing an extensive highly vascularized lesion involving the right side of the mandible and right submandibular region. The presence of several arteries feeding the vascular lesion.

tion was done to identify arteria carotis externa. After achieving proximal and distal control, arteria carotis externa was temporarily suspended above arteria thyroidea superior. Engorged vessels supplying to lesion were identified. Resection of the lesion was rapidly performed and the lesion was removed. Finally, flap was repositioned and sutured. The patient was invited the maintenance seances. Then, a second attempt was made to the corner of mouth and the chin after 6 months for aesthetic (Figure 1 B, C). During follow up of 2 years, no new vascular lesion in the cheek and submandibular region was revealed.

6 months after surgery, phase 1 periodontal therapy was performed gently and carefully by a periodontologist (MC). Periodontal treatment which was initiated with phase I therapy using hand instruments resulted in spontaneous brisk bleeding which was difficult to control. The bleeding site was suctioned and severe hemorrhage was controlled by manual pressure which took no less than 10 minutes. Mild bleeding that occurs during the scaling process was controlled with local anesthesia impregnated sponges. Postoperative bleeding was controlled by cold compression.

At the same appointment, mandibular right molar was endodontically treated and then restored with amalgam restoration by an endodontist. To bring back the teeth their normal positions, orthodontic treatment was carried. During the orthodontic treatment, to keep the patient healthy, the patient was followed-up for a period of two years. After the two-year follow-up seances, no recurrence of the gingival lesion and no bleeding at the gingiva were observed.

DISCUSSION

AVM is an abnormal communication between an artery and a vein.³ AVMs are quite rare conditions and they could be fatal if left untreated as the result of a massive blood loss after extraction or attempts to remove or biopsy the lesion.⁷ Therefore, it is considered a complicated clinical situation.⁶ Especially, the head and neck AVMs are seen at the cheek, lips, neck, scalp, neck, ear,

tongue, and mandible. They often spread multiple cervical-facial regions as they enlarge. Our knowledge is little about the origin and pathogenesis of AVM.⁵

AVMs of the head and neck region include soft tissue and intraosseous AVMs. Endovascular embolotherapy is the first choice for treatment. Combined of embolization and surgery is often necessary for advanced cases to improve their facial contour and oral function.¹¹ Once the diagnosis of AVM is confirmed, an angiography and embolization should be considered. The purpose of embolization is to control the growth of AVMs and bleeding. Successful embolization is completed when active bleeding has stopped.⁴ Angiographic and ultrasound tests are often used to provide the diagnosis and the exact location of the lesion. Angiography is very important for the determination of location and flow characteristics of these lesions.¹² Ethanol embolisation has been suggested more recently as an alternative treatment for AVM reporting that 40% of patients have been "cured".¹³

The resection of the whole mass without nerve or vascular injury or major bleeding is a surgical risk. Because of the risk of excessive bleeding, some authors suggest proceeding with 2 steps for the surgical procedures. To reduce the blood flow into the mass, embolization is done before surgery to permit formation of thrombus before the resection of the lesion. Some authors describe the use of embolization at the same time of surgery. Embolic materials such as gel foam and ethanol are at higher risk for pulmonary embolism. But in this case, no complication has developed.¹⁴

The external carotid ligation is a controversial technique, because of risk of recurrence. Therefore, the resection of the lesion should be as complete as possible because of this risk. In our study, during follow up of 2 years, no new vascular lesion in the cheek and submandibular region was revealed.¹⁴

Multiple treatment options must be evaluated to achieve the final result.¹³ Surgical removal of the lesion may lead to impaired facial growth, resulting

in an abnormal appearance and dental occlusion. Therefore orthodontic-prosthetic rehabilitation may require heaps of times. Unawareness of presence AVM in dental field can cause exsanguination results due to dental extractions, minor surgery, incision or other dental treatments.¹² One of the most common signs of these patients is excessive mobility of the teeth with spontaneous hemorrhage from the surrounding gingival crevicular sulcus. Abnormal bluish areas around mobile teeth can be an indication of such a lesion.¹⁵ Although AVM of the head and neck region is a rare condition, its knowledge is necessary for the periodontist, oral surgeons, and radiologists. The symptoms can be local or general, so a periodontist can play an important role in the diagnosis of the these lesions. Otherwise, the diagnosis cannot be made.¹²

CONCLUSION

AVM is a rare condition with a heterogeneous presentation, location and symptoms. Multidisciplinary team effort is vital to achieve an optimal outcome. Complete surgical resection with or without preoperative intra-arterial embolisation is necessary to prevent recurrence.

Only surgical resection of the lesion is not enough for patient's satisfaction. Reconstruction is an important part of surgical treatment of AVM. In addition to, AVMs of the affecting oral and dental structures require a complete multidisciplinary studies. To provide the aesthetic appearance, proper dental treatment is needed. Therefore, dentists should be able to diagnose these diseases and make necessary treatments. Dentist should avoid to make dental procedure before consulting the Plastic, Reconstructive and Aesthetic Surgeon.

Conflict of Interest

Authors declared no conflict of interest or financial support.

Authorship Contributions

Idea/concept: Metin Çalışır, Aysun Akpınar, Deniz İşcen; **Design:** Metin Çalışır, Deniz İşcen; **Control/supervision:** Metin Çalışır, Deniz İşcen; **Data Collection and/or Processing:** Metin Çalışır, Deniz İşcen; **Analysis and/or Interpretation:** Metin Çalışır, Aysun Akpınar, Deniz İşcen; **Literature review:** Metin Çalışır, Aysun Akpınar, Deniz İşcen; **Writing the Article:** Metin Çalışır; **Critical Review:** Metin Çalışır; **References and Fundings:** Metin Çalışır, Aysun Akpınar; **Materials:** Deniz İşcen.

REFERENCES

- Mulliken JB, Glowacki J. Hemangiomas and vascular malformations in infants and children: a classification based on endothelial characteristics. *Plast Reconstr Surg* 1982;69(3):412-22.
- Buckmiller LM, Richter GT, Suen JY. Diagnosis and management of hemangiomas and vascular malformations of the head and neck. *Oral Dis* 2010;16(5):405-18.
- Ziyeh S, Schumacher M, Strecker R, Rössler J, Hochmuth A, Klisch J. Head and neck vascular malformations: time-resolved MR projection angiography. *Neurorehabil* 2003;45(10):681-6.
- Zheng JW, Zhou Q, Yang XJ, Wang YA, Fan XD, Zhou GY, et al. Treatment guideline for hemangiomas and vascular malformations of the head and neck. *Head Neck* 2010;32(8):1088-98.
- Seccia A, Salgarello M, Farallo E, Falappa PG. Combined radiological and surgical treatment of arteriovenous malformations of the head and neck. *Ann Plast Surg* 1999;43(4):359-66.
- Yakes WF, Rossi P, Odink H. How I do it. Arteriovenous malformation management. *Cardiovasc Intervent Radiol* 1996;19(2):65-71.
- Greene MW, Nishioka GJ, Triplett RG, Holt GR. Arteriovenous malformation of the mandible: survey of previously unreported cases and case report. *J Oral Maxillofac Surg* 1989;47(12):1322-7.
- Fathi M, Manafi A, Ghenaati H, Mohebbi H. Large arteriovenous high-flow mandibular malformation with exsanguinating dental socket haemorrhage: a case report. *J Craniomaxillofac Surg* 1997;25(4):228-31.
- Richter GT, Suen J, North PE, James CA, Waner M, Buckmiller LM. Arteriovenous malformations of the tongue: a spectrum of disease. *Laryngoscope* 2007;117(2):328-35.
- Beziat JL, Marcelino JP, Bascoulergue Y, Vitrey D. Central vascular malformation of the mandible: a case report. *J Oral Maxillofac Surg* 1997;55(4):415-9.
- Kaneko R, Tohnai I, Ueda M, Negoro M, Yoshida J, Yamada Y. Curative treatment of central hemangioma in the mandible by direct puncture and embolisation with n-butyl-cyanoacrylate (NBCA). *Oral Oncol* 2001;37(7):605-8.
- Narang S, Gupta R, Narang A, Nema RN. Periodontal manifestations and management of a patient with AV malformation. *J Indian Soc Periodontol* 2012;16(2):266-70.
- Do YS, Yakes WF, Shin SW, Lee BB, Kim DI, Liu WC, et al. Ethanol embolization of arteriovenous malformations: interim results. *Radiology* 2005;235(2):674-82.
- Dieng PA, Ba PS, Gaye M, Diatta S, Diop MS, Sene E, et al. Giant arteriovenous malformation of the neck. *Case Reports in Vascular Medicine* 2015;2015:124010.
- Rance BR, Laws RA, Keeling JH 3rd, Warden PJ. Traumatic arteriovenous fistula of the upper lip. *Cutis* 1998;62(5):235-7.