

Paracetamol and Chlorpheniramine Combination-Induced Linear Ig A Bullous Dermatitis

Parasetamol ve Klorfeniramin Kombinasyonuna Bağlı Lineer Ig A Bullöz Dermatitisi

Sevilay KILIÇ^a, Alper EKİNCİ^a

^aÇanakkale Onsekiz Mart University Faculty of Medicine, Department of Dermatology, Çanakkale, TURKEY

This study was presented as a poster at 28th National of Dermatology Congress 24-28 September, Antalya, TURKEY

ABSTRACT Linear IgA bullous dermatosis (LABD) is an autoimmune, subepidermal vesiculobullous dermatosis. The etiology is unknown in most patients. Most recent case reports report drug-induced LABD cases. A 35 year-old male patient presented to our clinic with the complaint of tense bullous lesions located on trunk and extremities which started to occur after using a combined drug including paracetamol and chlorpheniramine. The lesions on the patient had responded quickly to systemic and topical corticosteroid treatment, no new lesion had existed since fifth day of treatment and older lesions had begun to be epithelized. Clinical findings and histopathologic and direct immunofluorescent examination findings are important for differentiation between LABD and other bullous dermatoses. The clinical course is lighter than the idiopathic form in drug-induced LABD. Drug-induced LABD is rarely observed compared to idiopathic form. Many drugs can cause this condition. The reported drug lists and variety continue to increase. Dermatologists should be aware of the rare adverse effects that may occur as a result of drug use.

Keywords: Linear IgA bullous dermatosis; paracetamol; chlorpheniramine

ÖZET Lineer IgA bullöz dermatitisi (LABD), otoimmün, subepidermal vezikülobullöz bir dermatitistir. Hastaların çoğunda, etiyoloji bilinmemektedir. Ancak son olgu raporlarının çoğu, ilaca bağlı LABD olgularını bildirmektedir. Hastamız, 35 yaşında erkek hasta, parasetamol ve klorfeniramin kombinasyonu bir ilaç kullanımı sonrasında, gövde ve ekstremitelerde yaygın ve dağınık yerleşimli, gergin bullöz lezyonların gelişmesi şikâyetiyle başvurdu. Sistemik ve topikal kortikosteroid tedavisine hızlı yanıt verdi ve tedavinin 5. gününden itibaren yeni lezyon çıkışı olmadı, mevcut lezyonları da iyileşmeye başladı. Klinik ve histopatolojik ile immüno Floresan incelemeler gibi laboratuvar bulguları LABD'yi diğer bullöz dermatozlardan ayırt etmede çok önemlidir. Klinik seyir, ilaca bağlı LABD'de idiyopatik olan forma göre daha hafiftir. İlaça bağlı LABD, idiyopatik forma göre nadir görülür. Birçok ilaç, bu tabloya yol açabilir. Bildirilen ilaç listeleri ve çeşitliliği giderek artmaktadır. Dermatologlar, ilaç kullanımının sonucunda gelişebilecek bu nadir advers etki konusunda dikkatli olmalıdırlar.

Anahtar Kelimeler: Lineer IgA bullöz dermatitisi; parasetamol; klorfeniramin

Linear IgA bullous dermatosis (LABD) is a rare autoimmune subepidermal bullous disease that was first described as an entity different from dermatitis herpetiformis in the 1970s. It is characterized by linear IgA accumulation in the basement membrane on the direct immunofluorescence examination. The clinic has heterogeneous findings

such as erythematous papules, plaques-like urticaria, annular or rosette-shaped vesiculobullous lesions on the mucosa, trunk and extremities.¹ Most cases are idiopathic. But it may also develop due to treatment with pharmacological agents and is most commonly associated with vancomycin Labdien.² In addition, developing sporadic cases depend on

Correspondence: Sevilay KILIÇ

Çanakkale Onsekiz Mart University Faculty of Medicine, Department of Dermatology, Çanakkale, TURKEY/TÜRKİYE

E-mail: sevilay.oguz@gmail.com



Peer review under responsibility of Türkiye Klinikleri Journal of Dermatology.

Received: 18 Oct 2019

Received in revised form: 11 Dec 2019

Accepted: 23 Dec 2019

Available online: 09 Jan 2020

2146-9016 / Copyright © 2021 by Türkiye Klinikleri. This is an open access article under the CC BY-NC-ND license (<http://creativecommons.org/licenses/by-nc-nd/4.0/>).

many medications, including acetaminophen have also been reported.³ We also found appropriate to present a case of LABD secondary to paracetamol chlorpheniramine use in our clinic, because because it is a rare entity. We believe that our case was the first LABD case report induced by paracetamol + chlorpheniramine.

CASE REPORT

A 35-year-old male patient was admitted to our out-patient clinic with the complaint of vesiculobullous lesions on the trunk and extremities about 1 week ago. He was accompanied by itching. It was learned that the rashes of the patient had been intermittent for 2 years and regressed with topical steroid treatment. There was no significant feature in his medical history and family history. He had no history of drug use

except for a combination of paracetamol + chlorpheniramine which he used intermittently for headache. He had recently used a drug with a combination of paracetamol + chlorpheniramine 6 days before the onset of his complaints. During the dermatological examination, diffuse, scattered, sharp-edged, on annular erythematous plaques, strained bullous lesions and diffuse erode areas were observed in the trunk and extremities of the patient (Figures 1-4). Nikolsky's sign was negative. Examination of the oral mucosa and other mucosal areas was normal. The patient's vital signs were stable. There was no significant findings except for leukocytosis (white blood cell count= 1,500/ μ l), sedimentation (45 mm/h) and C-reactive protein elevation (33.4 mg/dL) in the laboratory findings. Biopsy was taken for histopathological and direct immunofluorescence examinations

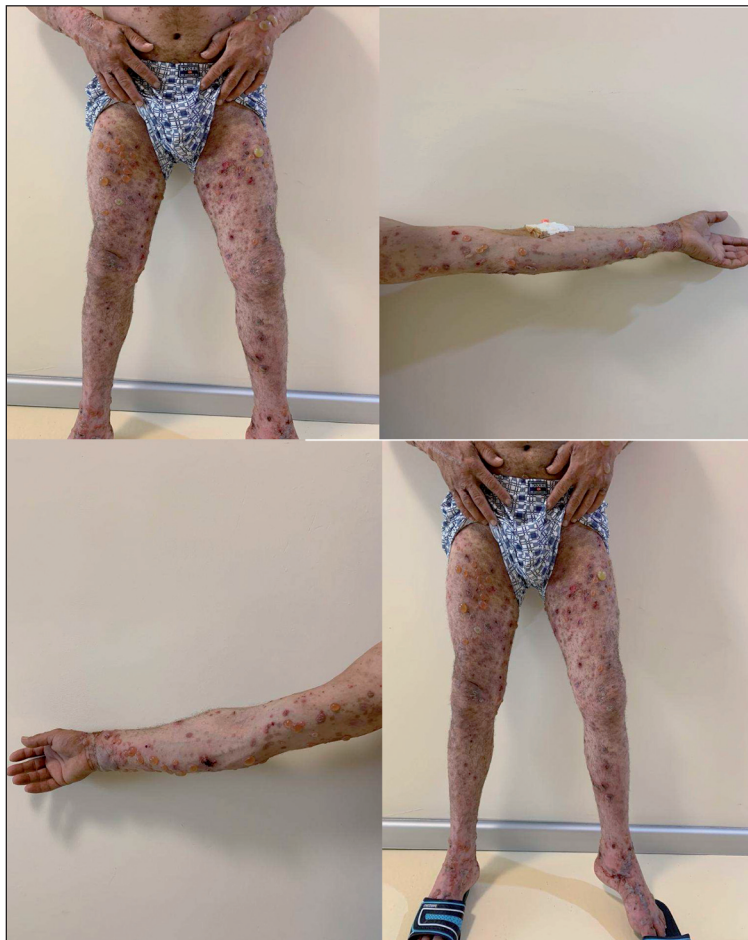

FIGURE 1-4: During the dermatological examination, diffuse, scattered, sharp-edged, on annular erythematous plaques, strained bullous lesions and diffuse erode areas were observed in the trunk and extremities of the patient.

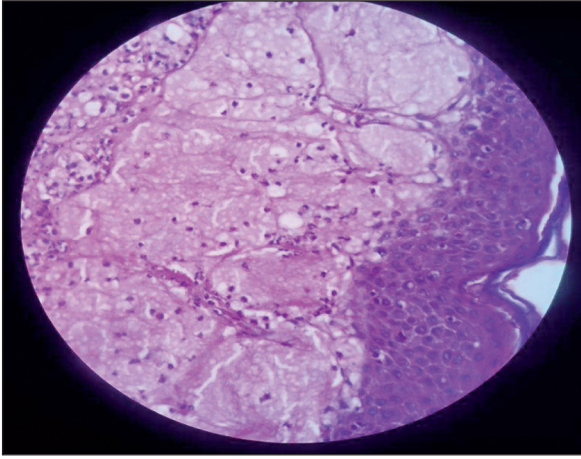


FIGURE 5: On histopathological examination; In the epidermis, it was observed septant orthokeratosis acanthosis, spongiosis, large bulla formation which is separating the dermo-epidermal junction in the subepidermal area and containing mixed types of inflammatory cells. Inflammatory cells were eosinophil-containing polymorphonuclear leukocytes and lymphocytes and were also found in the perivascular and interstitial areas.

with the preliminary diagnoses of bullous pemphigoid, LABD, dermatitis herpetiformis, epidermol-

ysis bullosa acquisita and generalized fix drug eruption. During histopathological examination; in the epidermis, it was observed septant orthokeratosis acanthosis, spongiosis, large bulla formation which is separating the dermo-epidermal junction in the subepidermal area and containing mixed types of inflammatory cells. Inflammatory cells were eosinophil-containing polymorphonuclear leukocytes and lymphocytes and were also found in the perivascular and interstitial areas (Figure 5). Direct immunofluorescence examination of the perilesional skin revealed linear IgA, immunoglobulin G (IgG) and C3c accumulation in the basement membrane in accordance with LABD. After biopsy, the patient was treated with 40 mg/day systemic steroid, topical steroid creams and topical antibiotic creams for erode infected lesions. On the 5th day of systemic steroid treatment, no new lesion emerged, and the patient's existing lesions were completely epithelized by responding dramatically to the treatment (Figures 6-9). (The necessary permission was taken from the patient).

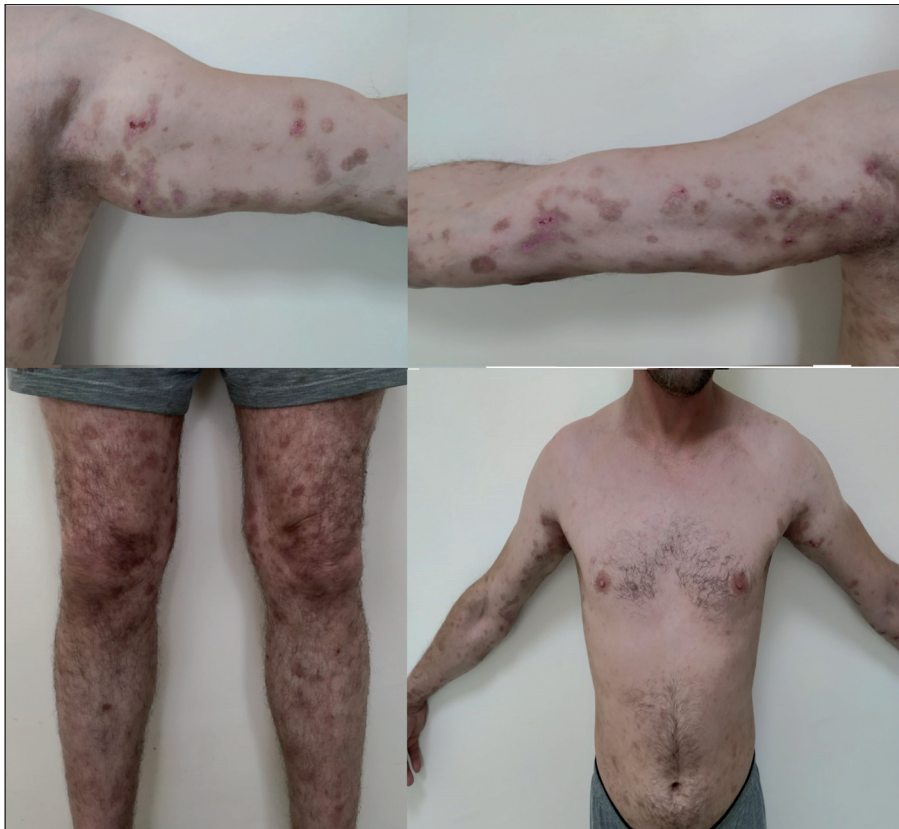

FIGURE 6-9: The patient's existing lesions were completely epithelized by responding dramatically to the treatment.

DISCUSSION

LABD is an autoimmune, subepidermal vesiculobullous dermatosis. It may occur as idiopathic or due to drugs. The clinical status is heterogeneous in both. The etiology is unknown in most patients. Most recent case reports report drug-induced LABD cases, however it may be equally common in idiopathic form. LABD-related drugs, most commonly vancomycin, are various antibiotics, nonsteroidal anti-inflammatory drugs (eg, diclofenac, naproxen, piroxicam), lithium, captopril, amiodarone, phenytoin, cyclosporine, furosemide, interferon alpha and somatostatin.² Genetic factors may also contribute to the development of LABD. The relationship of LABD with HLA B8, HLA Cw7, HLA DR3, HLA DQ2 and tumor necrosis factor-2 allele has been reported.⁴

The pathophysiology underlying the drug-induced LABD is still unclear. However, it is thought to result from an immune response against a drug-induced hapten-protein antigen. An alternative explanation for the pathogenesis of drug-induced LABD is the structural modification of protein molecules or the emergence of a previously concealed antigenic determinant that leads to an immune response of the drug.⁵ Target antigens are different antigenic structures in lamina lucida, sublamina densa or located both regions. Identification of target antigen in LABD is important for clinical picture and prognosis. For example; if the target antigen is Type VII collagen, patients are less likely to respond to treatment and are considered to be a subset of epidermolysis bullosa acquisita. Similarly, patients with antibodies directed against bullous pemphigoid antigens have clinically bullous pemphigoid. However, they indicate an IgA response instead of an IgG response. Those with antibodies to laminin 332 may potentially have mucosal involvement.⁶ In addition, the subunits of laminin 332 have been the target antigen in vancomycin-induced linear IgA dermatosis.⁷ The clinical presentation of drug-induced cases is generally not different from that of idiopathic patients. They usually show a clinical appearance similar to other

vesiculobullous dermatoses such as bullous pemphigoid and dermatitis herpetiformis. Rarely, the lesions may be localized or show similar clinical features such as morbilliform drug eruptions, erythema multiforme or toxic epidermal necrolysis. The presence of mucosal involvement is variable.⁸ There is no mucosal involvement in our case. The lesions were in the form of tense vesiculobullous lesions with asymmetric distribution in the trunk and extremities.

Most of the drug-induced LABD cases are observed in adults. The disease usually occurs within a month of the onset of the drug and cures within a few weeks of discontinuation. However, repeated exposure to the causative drug may cause the disease to develop more rapidly. For example; rash in vancomycin-induced LABD cases; occurred between 1 and 15 days after the first dose; it occurred 2 days after the first dose in one case reported to be related to acetaminophen. In our case, lesions appeared 6 days after ingestion of the drug, and all lesions were epithelized by treatment 5 days later after cessation of the trigger drug.^{3,9}

The differential diagnosis of LABD includes dermatitis herpetiformis, bullous impetigo, bullous pemphigoid and acquired epidermolysis bullosa. Direct immunofluorescent examination is the gold standard method to differentiate LABD from other bullous disorders. Especially, bullous pemphigoid which is more common in elderly patients, is differentiated from LABD with the histopathological finding of more prevalent eosinophil infiltration compared with LABD. Also, direct immunofluorescent examination of bullous pemphigoid is characterized with linear IgG and C3 deposition on basement membrane.

Diagnosis is made by histopathological examination and direct immunofluorescence examination which is the gold standard in diagnosis. The histopathological findings of LABD are non-specific and often resemble dermatitis herpetiformis. An infiltration which subepidermal bullae and polymorphonuclear leukocyte predominancy is characteristic.¹⁰ During direct immunofluorescence examination,

linear IgA deposition is typically seen in BMZ. Linear C3 deposition may also be observed. In some patients, both linear IgA accumulation and IgG accumulation may be seen in BMZ. Immunoglobulin M accumulation has rarely been reported. In our case, linear IgA, IgG and C3c accumulation was seen in the basement membrane zone. Some researchers have suggested that coexistence of linear IgA and IgG accumulations in LABD is coincidental or these cases be categorized as vesicular pemphigoid or bullous pemphigoid/LABD overlap or linear IgA/IgG bullous dermatosis.¹¹ The induction of autoantibody synthesis in autoimmune bullous dermatoses is not well understood. Also, pathogenic anti-IgA, anti-IgG or the factors which are leading to the synthesis of both antibodies are unknown. Recent studies make us think that specific cytokine microenvironments (eg transforming growth factor β 1, interleukin 4, interferon gamma) play a role.¹² Data on treatment options are limited in LABD. The treatment approach is usually based on case reports and case series. The first step in drug-related cases is discontinuation of causative drug and dapsons, sulfapyridine, topical and systemic steroids can be selected for treatment. The clinical course is milder than the idiopathic form in drug-induced LABD. In drug-induced LABD, cessation of new lesion formation typically occurs within three days after discontinuation of the drug,

and complete recovery usually occurs within a few weeks.¹³ In our patient, near-complete epithelialization developed in the lesions 5 days after discontinuation of the causative drug and with systemic steroid treatment.

As a result, drug-induced LABD is rare compared to idiopathic form. Many drugs can lead to this picture.^{14,15} The reported drug lists and variety are increasing. Dermatologists should be aware of this rare adverse effect that may occur as a result of drug use.

Source of Finance

During this study, no financial or spiritual support was received neither from any pharmaceutical company that has a direct connection with the research subject, nor from a company that provides or produces medical instruments and materials which may negatively affect the evaluation process of this study.

Conflict of Interest

No conflicts of interest between the authors and / or family members of the scientific and medical committee members or members of the potential conflicts of interest, counseling, expertise, working conditions, share holding and similar situations in any firm.

Authorship Contributions

All authors contributed equally while this study preparing.

REFERENCES

- Machado TYS, Enokihara MMSES, Iida TM, Porro AM. Adult linear IgA bullous dermatosis: report of three cases. *An Bras Dermatol.* 2018;93(3):435-7. [[Crossref](#)] [[PubMed](#)] [[PMC](#)]
- Selvaraj PK, Khasawneh FA. Linear IgA bullous dermatosis: a rare side effect of vancomycin. *Ann Saudi Med.* 2013;33(4):397-9. [[Crossref](#)] [[PubMed](#)] [[PMC](#)]
- Avci O, Okmen M, Cetiner S. Acetaminophen-induced linear IgA bullous dermatosis. *J Am Acad Dermatol.* 2003;48(2):299-301. [[Crossref](#)] [[PubMed](#)]
- Collier PM, Wojnarowska F, Welsh K, McGuire W, Black MM. Adult linear IgA disease and chronic bullous disease of childhood: the association with human lymphocyte antigens Cw7, B8, DR3 and tumour necrosis factor influences disease expression. *Br J Dermatol.* 1999;141(5):867-75. [[Crossref](#)] [[PubMed](#)]
- Klein PA, Callen JP. Drug-induced linear IgA bullous dermatosis after vancomycin discontinuance in a patient with renal insufficiency. *J Am Acad Dermatol.* 2000;42(2 Pt 2):316-23. [[Crossref](#)] [[PubMed](#)]
- Sakaguchi M, Bito T, Oda Y, Kikusawa A, Nishigori C, Munetsugu T, et al. Three cases of linear IgA/IgG bullous dermatosis showing IgA and IgG reactivity with multiple antigens, particularly laminin-332. *JAMA Dermatol.* 2013;149(11):1308-13. [[Crossref](#)] [[PubMed](#)]
- Zenke Y, Nakano T, Eto H, Koga H, Hashimoto T. A case of vancomycin-associated linear IgA bullous dermatosis and IgA antibodies to the α 3 subunit of laminin-332. *Br J Dermatol.* 2014;170(4):965-9. [[Crossref](#)] [[PubMed](#)]
- Garel B, Ingen-Housz-Oro S, Afriat D, Prost-Squarcioni C, Tétart F, Bensaid B, et al. Drug-induced linear immunoglobulin abullous dermatosis: a French retrospective pharmacovigilance study of 69 cases. *Br J Clin Pharmacol.* 2019;85(3):570-9. [[Crossref](#)] [[PubMed](#)] [[PMC](#)]
- Whitworth JM, Thomas I, Peltz SA, Sullivan BC, Wolf AH, Cytryn AS, et al. Vancomycin-induced linear IgA bullous dermatosis (LABD). *J Am Acad Dermatol.* 1996;34(5 Pt 2):890-1. [[Crossref](#)] [[PubMed](#)]

10. Fortuna G, Marinkovich MP. Linear immunoglobulin a bullous dermatosis. *Clin Dermatol.* 2012;30(1):38-50. [[Crossref](#)] [[Pubmed](#)]
11. Hertl M, Büdinger L, Christophoridis S, Yancey KB, Borradori L. IgG and IgA antibodies in linear IgA/IgG bullous dermatosis target the ectodomain of bullous pemphigoid antigen 2. *Br J Dermatol.* 1999;140(4):750-2. [[Pubmed](#)]
12. König C, Eickert A, Scharfetter-Kochanek K, Krieg T, Hunzelmann N. Linear IgA bullous dermatosis induced by atorvastatin. *J Am Acad Dermatol.* 2001;44(4):689-92. [[Crossref](#)] [[Pubmed](#)]
13. Navi D, Michael DJ, Fazel N. Drug-induced linear IgA bullous dermatosis. *Dermatol Online J.* 2006;12(5):12. [[Crossref](#)] [[Pubmed](#)]
14. Stamenkovic HM, Lazarevic D, Stankovic T, Vojinovic J, Lekic B, Marinkovic A, et al. Linear IgA dermatosis of the childhood-Report of an amoxicillin-induced case. *Dermatol Ther.* 2020;33(1):e13173. [[Crossref](#)] [[Pubmed](#)]
15. Sarikaya Solak S, Ficioglu S. Cephalosporin-induced linear IgA dermatosis in a child: case report and literature review. *Dermatol Ther.* 2019;32(4):e12927. [[Crossref](#)] [[Pubmed](#)]