

# Real Function of Superior Head of Lateral Pterygoid Muscle by Magnetic Resonance Imaging<sup>¶</sup>

## MUSCULUS PTERYGOIDEUS LATERALIS'İN ÜST KARNININ ESAS FONKSİYONUNUN MANYETİK REZONANS METODU İLE BELİRLENMESİ

Bayram Ufuk ŞAKUL\*, Rabet GÖZİL\*\*, Engin ÇALGÜNER\*\*, Tuğra TACAL\*\*\*, Erdinç TUNÇ\*\*, Muzaffer BABADAĞ\*\*\*\*

\* Anatomy Dept. School of Dentistry, Ankara University,

\*\* Anatomy Dept. School of Medicine, Gazi University,

\*\*\* Specialist Radiolog, Mithatpaşa cad. 16/B , Yenışehir,

\*\*\*\* Oral Diagnosis and Radiology Dept., School of Dentistry, Ankara University, Ankara, TURKEY

### Summary

**Purpose:** This study aims to clarify the real function of superior lateral pterygoid muscle.

**Material and Method:** In this study, Magnetic Resonance Imaging Technique (MRI) was used and the real function of superior lateral pterygoid muscle of thirty volunteers (13 males and 17 females) ranging in age from 20 to 57 were investigated.

**Results and Conclusions:** Our results indicated that the superior lateral pterygoid muscle is active while the mouth is open.

**Key Words:** Superior lateral pterygoid muscle, Magnetic resonance imaging

T Klin J Dental Sci 2000, 6:73-78

### Özet

**Amaç:** Bu çalışmanın amacı, m. pterygoideus lateralis'in üst karnının esas fonksiyonunu ortaya koymaktır

**Materyal ve Metod:** Çalışmamızda manyetik rezonans tekniği kullanılmış ve yaşları 20-57 arasında değişen otuz gönüllünün (13 erkek, 17 kadın) m. pterygoideus lateralis'inin üst karnının esas fonksiyonu araştırılmıştır.

**Bulgular ve Sonuç:** M. pterygoideus lateralis'in üst karnının ağız açık olduğu zaman aktif olduğu tesbit edilmiştir.

**Anahtar Kelimeler:** M. pterygoideus lateralis'in üst karnı, Manyetik rezonans tekniği

T Klin Diş Hek Bil 2000, 6:73-78

M. pterygoideus lateralis, particularly in man, is a triangular muscle with a history of controversy. It has been described as a single unit (1-5), but it has also been widely accepted as a double-headed muscle (5-14).

The upper head or superior lateral pterygoid muscle is considerably smaller than the lower head

**Geliş Tarihi:** 21.09.1999

**Yazışma Adresi:** Dr.Erdinç TUNÇ  
23. Sokak 7/1  
06490, Bahçelievler, Ankara, TURKEY

<sup>¶</sup>Bu çalışma 3-5 Haziran 1999 da Romanya'da yapılan "5. National Congress of Romanian Society of Anatomists"de sunulmuştur.

T Klin J Dental Sci 2000, 6

or inferior lateral pterygoid muscle. It originates at infratemporal surface of the greater sphenoid wing, extending almost horizontally, backward and outward to insert on pterygoid fovea of the mandibular condyle, the articular disc and capsule (3,4,9,10,12,14,15). The inferior lateral pterygoid muscle originates at outer surface of the lateral pterygoid plate and extends backward, upward and outward to its insertion primarily on the neck of the condyle (3,9,10,12,14). Two heads of the lateral pterygoid muscle make a unique contribution to jaw movement control by virtue of their attachments to temporomandibular joint disc and condyle (16). However, there are some confliction for the function of two heads of this muscle. Some authors

73

stated that the mandible are protruded by the two heads which are opening muscle of the chin (14,17). The others revealed that the inferior lateral pterygoid muscle is only active during opening, the superior lateral pterygoid muscle remains inactive, becoming active only in conjunction with the elevator muscles (3,11).

A number of studies, including electromyography (EMG), have investigated the function of the lateral pterygoid muscle. However the real function of the superior head has not been resolved yet due to its deep placement (18-23). Birou (24) has investigated the lateral pterygoid muscle by Tomodensitometry (TDM) and Magnetic Resonance Imaging (MRI). The author stated that MRI is better than TDM because of its three dimensional aspect.

This study aims to clarify the real function of the superior head of the lateral pterygoid muscle using MRI.

### Materials and Methods

The study was performed on 30 musculoarticular areas of healthy subjects (13 males and 17 females) aged from 20 to 57 years. Data were collected by the same person throughout the study. Clinical examination did not reveal any craniomandibular disorders or any muscular spasms.

For each exploration, two mandibular positions were defined:

1. The position of the chin with lips closed and the condyle placed in the mandibular fossa.
2. The position of the chin with lips opened and the condyle on the articular eminence.

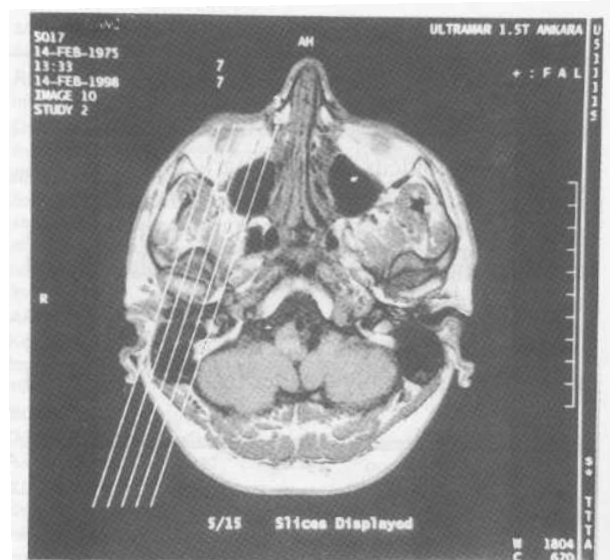
Volunteers were examined with a 1.5 T Siemens Magnetom Vision MRI system. All images were focused into the infratemporal fossa. First axial images of infratemporal fossa with 4 mm slice thickness are obtained with a T1W sequence (TR: 352 ms, TE: 12 ms). After localizing the superior head of lateral pterygoid muscle on transvers images, sagittal oblique images with 3 mm slice thickness (TR: 352 ms, TE: 12 ms) parallel to this muscle were obtained with mouth closed position. Afterwards the volunteer was required to open his/her mouth with an apparatus of 3 cm thickness

(if it was possible for the volunteer to open his/her mouth more than this, then the images were obtained with the mouth wide open position instead of using the apparatus) and the same sagittal oblique images were obtained. The MRI system used, which gives to run like the same sequence as many times as, it makes possible to examine the same coordinates with the mouth closed and open positions. And on these sagittal oblique images, the length of superior head of the lateral pterygoid muscle of each volunteer was measured from crista infratemporalis to temporomandibular joint disc with the mouth open and closed positions. The vertical lengths of these muscles were also measured on its largest portion on both positions (this time we did not measure the same coordinates since when the muscle contracts, the position of its largest portion changes due to contraction).

The sagittal and vertical lengths of the superior lateral pterygoid muscle were measured for each position (Figure 1). Morphometric values were obtained and statistically evaluated by the "paired-samples t test" (25).

### Results

The inferior and superior heads have a strong opening action as expected. Sagittal and vertical



**Figure 1a.** On transvers T1W images, shows a superior head of lateral pterygoid muscle, and used these images as a localizer to our sagittal oblique images.

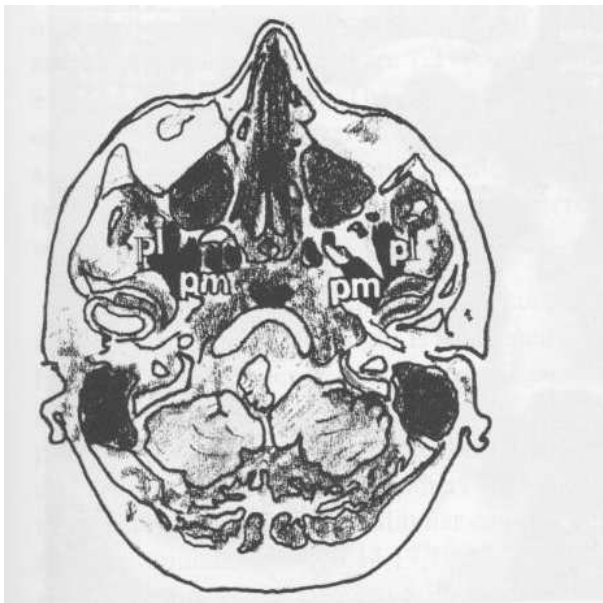


Figure 1b. Scheme of figure 1a.

lengths of the muscle are presented in Table 1 for the open and closed positions of the mouth. The mean sagittal length of the superior lateral pterygoid muscle is  $23.6 \pm 0.45$  mm.,  $27.3 \pm 0.34$  mm. in the open and closed mouth, respectively. The mean vertical length of the superior lateral pterygoid muscle of the open and closed mouth position are  $7.2 \pm 0.36$  mm.,  $5.4 \pm 0.33$  mm. respectively.

Difference between open and closed mouth was statistically found to be significant for sagittal and vertical lengths ( $p < 0.01$ ). Indicating that muscle length is decreased, when the mouth is open.

### Discussion

The lateral pterygoid muscle in man is triangular shaped and has two distinct anatomical heads

(4,9,10,14). Birou et al. (26) have studied the relationship between anatomic and CT sections of the lateral pterygoid muscle in anatomic specimens. Anatomic and CT sections show that three parts can be distinguished. The head classically called pterygoid being itself divided into two parts by a septum.

The superior lateral pterygoid muscle is of particular interest because it inserts in pterygoid fovea of the mandibular condyle, the articular disc and capsule (4,9,10,14,15).

Activity of superior lateral pterygoid muscle in relation to the function of other jaw muscles seems to be important in mandibular condyle- disc coordination of temporomandibular joint and muscle pain (9,10).

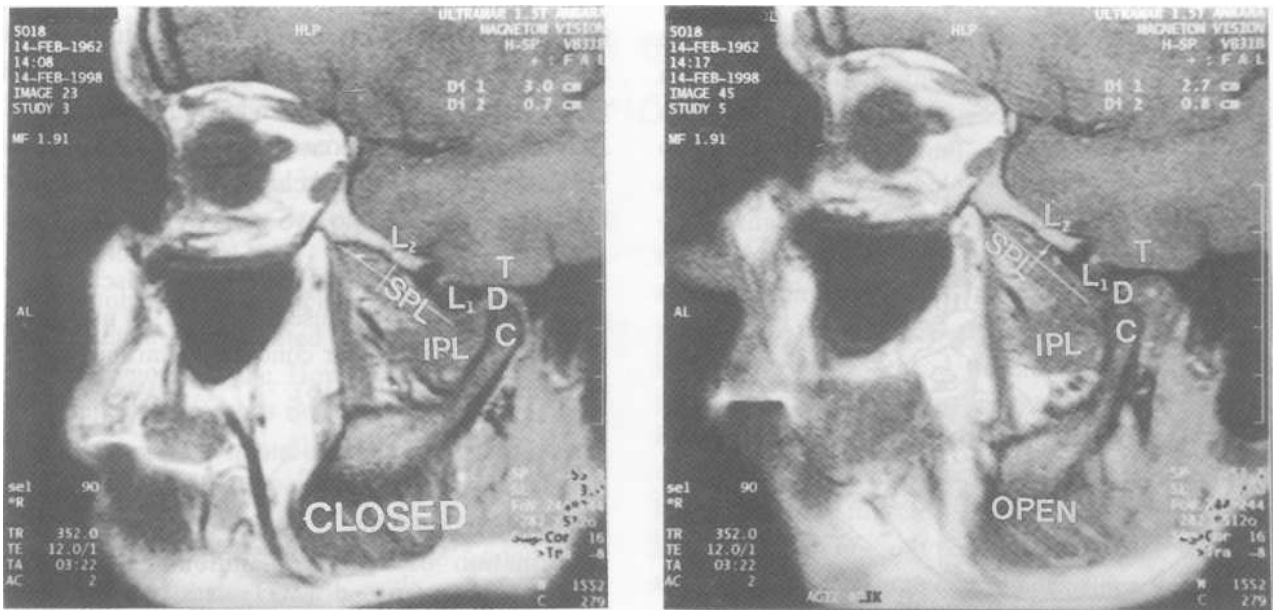
Although researchers generally agree on the function of inferior lateral pterygoid muscle, there is conflicting reports in the literature with respect to function of the superior lateral pterygoid muscle (3,11,16,20,27).

The lack of certainty about the structural organization of this muscle makes it difficult to understand how it functions and what the electromyographic recording actually represents. Electromyo-graphic evidence indicates that the superior head is active during closing movements (3,6,11,28). However, Auf der Maur (29) revealed that the electrode was positioned wrongly in the temporal muscle. In addition, Carpentier et al. (2) stated that the location of electrodes recording muscle activity remains questionable, at least in human research.

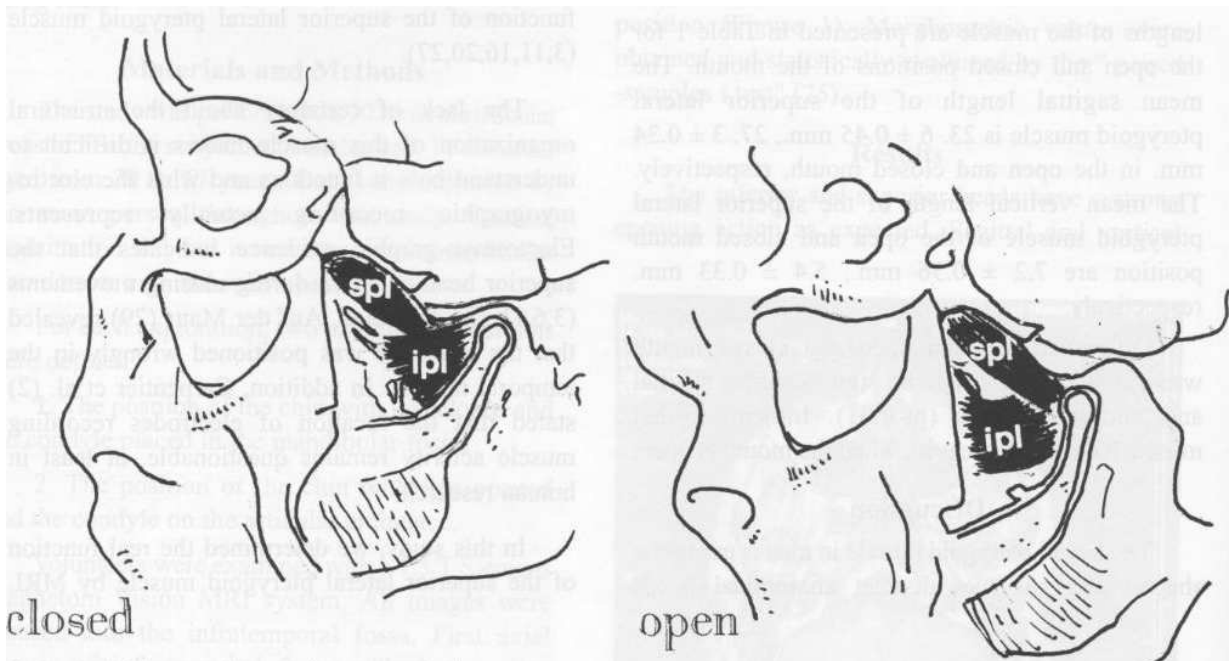
In this study, we determined the real function of the superior lateral pterygoid muscle by MRI.

**Table 1.** The sagittal and vertical lengths of the superior lateral pterygoid muscle are shown (mm). (Minimum and maximum values are given in paranthesis)

	SAGITTAL		VERTICAL	
	Open	Closed	Open	Closed
Means and SEM	$23.6 \pm 0.45$ (20.0-28.0)	$27.3 \pm 0.34$ (24.0-30.0)	$7.2 \pm 0.36$ (3.0-11.0)	$5.4 \pm 0.33$ (3.0-9.0)



**Figure 2a-b.** On sagittal oblique image, shows the measurements of the length of the muscle from crista infratemporalis to temporomandibular joint disc with the mouth closed (a) and open (b) positions. The figure also shows the vertical length of the muscle on both positions.



**Figure 2c-d.** Schemes of figures 2a-b, respectively.

- L1 = Sagittal length
- L2 = Vertical length
- SPL = Superior Lateral Pterygoid muscle
- IPL = Inferior Lateral Pterygoid muscle

- D = Disc
- C = Caput mandibulae
- T = Tuberculum articulare
- PM= Medial Pterygoid muscle

For this purpose, the sagittal and vertical lengths of the muscle were measured in the open and closed mouth (Figure 1). The mean sagittal lengths of the

superior lateral pterygoid muscle of the open and closed mouth position are  $23.6 \pm 0.45$  mm.,  $27.3 \pm 0.34$  mm, respectively. The mean vertical lengths

of the superior lateral pterygoid muscle of the open and closed mouth position are  $7.2 \pm 0.36$  mm.,  $5.4 \pm 0.33$  mm., respectively. The differences between open and closed mouth were statistically found to be significant for sagittal and vertical lengths ( $p < 0.01$ ). Indicating that muscle length is decreased when the mouth is open.

When a triangular - shaped muscle contracts to initiate a movement, its length is shortened (4,14). For this reason, superior head of lateral pterygoid muscle is an opening muscle of the mouth by protracting the mandibular condyle rotates on the disc. This is in agreement with others who state that this muscle protracts the mandibular condyle on the articular eminence (2,4,10,14,17,19,27,30-35). The results of this study also have important clinical implications for interpretation of MRI.

#### REFERENCES

- Basmajian JW: Primary Anatomy. Baltimore, Williams & Wilkins, 1970, p 137
- Carpentier PD, Yung JP, Bonnet RM, Meunisser M: Insertions of the lateral pterygoid muscle. J Oral Maxillofac Surg 46 : 477, 1988
- Grant PG: Lateral pterygoid: two muscles? Am J Anat 138: 1, 1973
- Lindner HH: Clinical Anatomy. California, Appleton & Lange, 1989, p. 45
- Thompson JS: Core Textbook of Anatomy. Philadelphia, JB Lippincott Company, 1977, p 239
- Juniper RP: Temporomandibular joint dysfunction: A theory based upon electromyographic studies of the lateral pterygoid muscle. Brit J Oral Maxillofac Surg 22: 1, 1984
- Leeson CR, Leeson TS: Human Structure. Philadelphia: BC Decker Inc, 1989, p 156
- McMinn RMH: Last's Anatomy, Edinburgh, Churchill Livingstone, 1994, p 458
- Ogutcen-Toller M, Juniper RP: The development of the human lateral pterygoid muscle and the temporomandibular joint and related structures: a three-dimensional approach. Early Hum Dev 39: 57, 1994
- Ogutcen-Toller M: The morphogenesis of the human discomalleolar and sphenomandibular ligaments. J Craniomaxillofac Surg 23: 42, 1995
- Okeson JP: Management of Temporomandibular Disorders and Occlusion, Baltimore, The CV Mosby Company, 1989, pp 19-20
- Staubesand J: Atlas of Human Anatomy. Baltimore, Urban & Schwarzenberg 1989, p 61
- Velasco JRM, Vazquez JFR, Collado J: The relationships between the temporomandibular joint disc and related masticatory muscles in humans. J Oral and Maxillofac Surg 51: 390, 1993
- Williams PL, Warwick R, Dyson M, Bannister LH: Gray's Anatomy. Edinburgh, Churchill Livingstone, 1989, pp 487, 565-567
- Gozil R, Calguner E, Sakul U, Evrenkaya T: Histologic examination of the relationship between m. pterygoideus lateralis and capsula articularis, discus articularis in the temporomandibular joint of human cadavers. T Clin J Dent Sci 2 : 48, 1996
- Klineberg I: The lateral pterygoid muscle: Some anatomical, physiological and clinical considerations. Ann R Australas Coll Dent Surg 11: 96, 1991
- Drenckhahn D, Zenker W: Benninghoff Anatomie. München, Urban & Schwarzenberg, 1994, p 510
- Gibbs CH, Mahon PE, Wilkinson TM, Mauderli A: EMG activity of the superior lateral pterygoid muscle in relation to other jaw muscles. J Prosthet Dent 51: 691, 1984
- Huiyun W, Weiya P: A comparative electromyographic study of the lateral pterygoid muscle and arthrography in patients with temporomandibular joint disturbance syndrome sounds J Prosthet Dent 62 : 229, 1989
- Mahan PE, Wilkinson TM, Gibbs CH, Mauderli A, Brannon LS: Superior and inferior bellies of the lateral pterygoid muscle EMG activity at basic jaw positions. J Prosthet Dent 50 : 710, 1983
- Wang MQ: The study on the relationships between malocclusion of the third molar and craniomandibular dysfunction. Chung Hua Kou Chiang Hsueh Tsa Chih 29 : 85, 1994
- Widmalm SE, Lillie JH, Ash MM: Anatomical and electromyographic studies of the lateral pterygoid muscle. J Oral Rehabil 14: 429, 1987
- Yoshida K: The electromyographic activity of the masticatory muscles during temporomandibular joint clicking. Schweiz Monatsschr Zahnmed 105: 24, 1995
- Birou G, Garcier JM, Guillot M, Vanneville G, Escande G: Corrélatons de l'imagerie TDM et IRM du muscle ptérygoïdien latéral Annales De Radiologie 35: 193, 1992
- Snedecor GW: Statistical Methods. Iowa, Iowa State University Press, 1965, p 105
- Birou G, Garcier JM, Guillot M, Vanneville G, Chazal J: A study of the lateral pterygoid muscle : anatomic sections and CT appearances. Surg Radiol. Anat. 13: 307, 1991.
- Takahashi K: An electromyographic study of the inferior head of the lateral pterygoid muscle and the anterior belly of the digastric muscle during jaw - opening. Nippon Hotetsu Shika Gakkai Zasshi 34: 559, 1990
- McNamara JA: The independent functions of the two heads of the lateral pterygoid muscle. Am J Anat 138: 197, 1973

29. Auf der Maur HJ: Electromyographic recordings of the lateral pterygoid muscle in activator treatments of Class II, Division 1, malocclusion cases. *Eur J Orthod* 2: 161, 1980
30. Barlattani A, Gargari M: The external pterygoid muscle: Functional aspects. *Dent Cadmos* 59: 56, 1991
31. Easton JW, Carlson DS: Adaptation of the lateral pterygoid muscle and superficial masseter muscles to mandibular protrusion in the rat. *Am J Orthod Dentofac Orthop* 97: 149, 1990
32. Ferrario V, Sforza C: Biomechanical model of the human mandible: A hypothesis involving stabilizing activity of the superior belly of lateral pterygoid muscle. *J Prosthet Dent* 68: 829, 1992
33. Ger R, Abrahams P: *Essentials of Clinical Anatomy*. Philadelphia, FA Davis Company, 1988, p 208
35. Schmolke C: The relationship between the temporomandibular joint capsule, articular disc and jaw muscles. *J Anat* 184 : 335, 1994