

## CASE REPORT

DOI: 10.5336/caserep.2023-96798

# A Rare Postoperative Complication in a Pediatric Hydrocephalus Case: Migration of the Ventriculoperitoneal Shunt Catheter Into the Scrotal Hernia Sac

<sup>1</sup> Veysel KIYAK<sup>a</sup>, <sup>2</sup> Sabri CANSARAN<sup>b</sup>

<sup>a</sup>Department of Neurosurgery, Tokat Gaziosmanpaşa University Faculty of Medicine, Tokat, Türkiye

<sup>b</sup>Department of Pediatric Surgery, University of Health Sciences Zeynep Kamil Maternity and Children's Diseases Health Training and Research Center, İstanbul, Türkiye

**ABSTRACT** Displacement of the catheter outside the intrabdominal area after ventriculoperitoneal (VP) shunt is an extremely rare complication. In a 4-month-old male patient with a history of VP shunt due to hydrocephalus in the neonatal period, abdominal X-ray showed that the distal end of the shunt catheter was in the scrotum. The catheter tip was reduced to the abdomen via left inguinal herniotomy, and hernia repair was performed with high ligation. Migration of the VP shunt catheter into the scrotal area is a complication that is easy to treat, but has not yet been clarified in terms of prevention. The recognition of this complication and its correction with early surgical intervention are important in terms of preventing possible visceral organ damage and clinical worsening due to shunt obstruction.

**Keywords:** Catheters; inguinal hernia; hydrocephalus; pediatrics; ventriculoperitoneal shunt

Hydrocephalus is the excessive accumulation of cerebrospinal fluid (CSF) in the ventricular cavities and the associated increase in intracranial pressure. While this may sometimes occur due to excess CSF production or low absorption, it may sometimes occur as a result of an abnormality in CSF flow.<sup>1</sup>

The most commonly used method in the treatment of hydrocephalus is ventriculoperitoneal (VP) shunting, and many complications related to this procedure have been reported.<sup>2</sup> One of these complications is the progression or spontaneous migration of the distal end of the shunt, which should be located intra-abdominal, to areas such as the mediastinum, gastrointestinal tract, vagina, and scrotum during or after the procedure.<sup>3,4</sup> In this study, it was aimed to present a 4-month-old case whose distal end of the catheter migrated into the left scrotal hernia sac after VP shunt applied for hydrocephalus in the neonatal period.

## CASE REPORT

A 4-month-old male patient who applied to the pediatric emergency outpatient clinic with the complaint of swelling in the groin only, was consulted to the pediatric surgery clinic due to the suspicion of left inguinal hernia. On physical examination, a hard and tubular structure extending from the left inguinal region to the scrotum was palpated, and both testes were located scrotally (Figure 1). Additionally, a firm structure was palpated in the right parietal region, and there was also a transverse incision scar on the left of the umbilicus and a vertical midline incision scar in the lumbar region. It was learned that the patient had been operated due to meningomyelocele in the neonatal period, and a VP shunt was applied at the age of 1.5 months due to the development of hydrocephalus. In the patient with a history of VP shunt, it was thought that the distal end of the catheter might

**Correspondence:** Sabri CANSARAN

Department of Pediatric Surgery, University of Health Sciences Zeynep Kamil Maternity and Children's Diseases Health Training and Research Center, İstanbul, Türkiye

**E-mail:** sabrican@hotmail.com



Peer review under responsibility of Türkiye Klinikleri Journal of Case Reports.

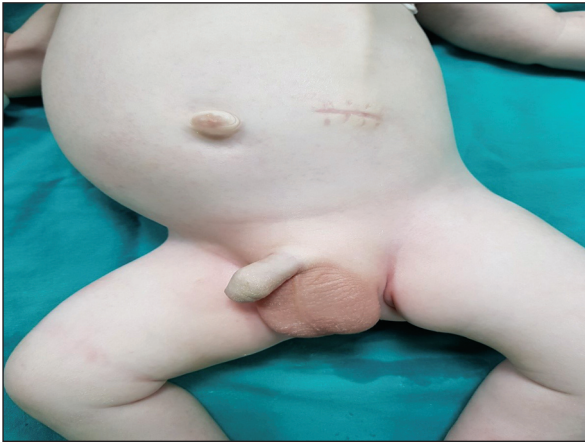**Received:** 17 Mar 2023

**Received in revised form:** 23 Aug 2023

**Accepted:** 24 Aug 2023

**Available online:** 29 Aug 2023

2147-9291 / Copyright © 2023 by Türkiye Klinikleri. This is an open access article under the CC BY-NC-ND license (<http://creativecommons.org/licenses/by-nc-nd/4.0/>).



**FIGURE 1:** The patient at the time of admission with the complaint of swelling in the left groin.

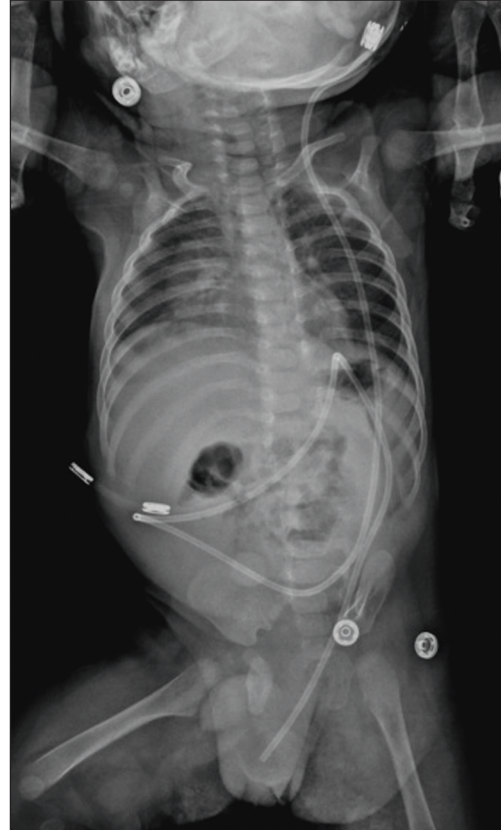extend into the scrotal area due to the left indirect inguinal hernia.

In the abdominal X-ray, it was seen that the distal end of the shunt catheter migrated into the scrotal cavity as predicted (Figure 2). Subsequently, the superficial tissue and scrotal ultrasound report of the left inguinal region showed that the VP shunt catheter pushed the peritoneum and protruded from the left inguinal canal into the scrotum, and there was reactive thickening in the surrounding peritoneum. No pathological finding was detected in the brain computed tomography performed to evaluate the increase in hydrocephalus that may develop due to obstruction of the shunt catheter.

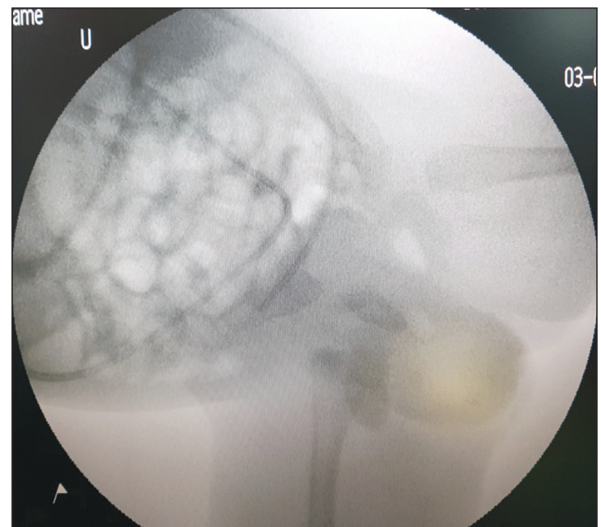
Due to the risk of visceral organ incarceration, the patient underwent shunt catheter control and hernia repair with an emergency left inguinal exploration planned by the pediatric surgery clinic. The patient's preoperative complete blood count, biochemistry, coagulation and serology tests were within normal limits. During the operation, the distal end of the catheter was seen in the hernia sac. However, when the hernia sac was isolated from the cord and vessels, it was observed that the catheter was reduced spontaneously into the abdomen. The inner part of the hernia sac was controlled, and high ligation was achieved. In the control X-ray taken with the mobile device, it was seen that the catheter was placed normally in the abdomen (Figure 3). The patient, who had no early complications, was discharged on the ninth postoperative day after the follow-up at the neurosurgery

clinic was completed. The patient's outpatient clinic controls were uneventful.

Informed consent for participating in the study was obtained from the parents of the patient included in the study.



**FIGURE 2:** Preoperative plain abdominal X-ray.



**FIGURE 3:** Postoperative abdominal X-ray for catheter control.

## DISCUSSION

VP shunt is one of the most commonly used and most effective methods in the treatment of hydrocephalus.<sup>2</sup> The most common complications associated with a VP shunt are catheter infection and obstruction.<sup>5</sup> Intracranial hematoma, intestinal perforation, and migration of the peritoneal end of the shunt to the thorax, umbilicus, scrotum or anal region are less common complications.<sup>6</sup>

Migration of the shunt into the scrotum usually occurs through the processus vaginalis, which does not close before birth. Processus vaginalis patency is seen at a rate of 60-70% in the first 3 months of the postnatal period, 50-60% in the first 1 year, and 40% between the ages of 2-6.<sup>7-9</sup> After VP shunt application, it is argued that intra-abdominal pressure increases, therefore the duration of the processus vaginalis patency is prolonged, and hernia and hydrocele are seen at a higher rate in patients with shunt compared to normal children.<sup>7</sup> Spina bifida surgery has been associated with intra-abdominal complications, and Özveren et al. stated that repair of a large spina bifida defect may be another factor that increases intra-abdominal pressure in addition to hydrocephalus. In addition, they argued that scrotal swelling or hydrocele developing in a child with a VP shunt should be considered as a possible shunt complication.<sup>10</sup>

Catheter migration usually does not require shunt revision.<sup>8</sup> In a similar case report, the existing shunt was replaced with a high-pressure shunt.<sup>11</sup> In another case in the literature, the distal part of the shunt catheter was shortened.<sup>12</sup> In the review conducted by Kita et al., it was observed that this complication usually occurs in patients older than 18 months and approximately 3-4 months after VP shunt surgery.<sup>8</sup> The development of scrotal swelling approximately 3.5 months after the VP shunt application in the patient in this study is similar to the

literature. In a migration case reported by Rehm et al., there is also scrotal perforation.<sup>13</sup> It has been stated that laparoscopic investigation of the patent processus vaginalis during the application of the VP shunt can prevent inguinal complications.<sup>14</sup>

In conclusion, migration of the VP shunt catheter into the scrotal area is a complication that is easy to treat, but has not yet been clarified in terms of prevention. The diagnosis can be made with the help of plain abdominal X-ray and ultrasound if there is doubt in the history and physical examination. Evaluating the cases together with pediatric surgery clinicians and investigating the patent processus vaginalis laparoscopically before VP shunt application may reduce the complications. Recognition of this complication and its correction with early surgical intervention are important to prevent possible visceral organ incarceration, necrosis and/or perforation due to blood supply disorder, and clinical worsening due to shunt obstruction.

### Source of Finance

*During this study, no financial or spiritual support was received neither from any pharmaceutical company that has a direct connection with the research subject, nor from a company that provides or produces medical instruments and materials which may negatively affect the evaluation process of this study.*

### Conflict of Interest

*No conflicts of interest between the authors and / or family members of the scientific and medical committee members or members of the potential conflicts of interest, counseling, expertise, working conditions, share holding and similar situations in any firm.*

### Authorship Contributions

**Idea/Concept:** Veysel Kiyak, Sabri Cansaran; **Design:** Veysel Kiyak, Sabri Cansaran; **Control/Supervision:** Sabri Cansaran; **Data Collection and/or Processing:** Veysel Kiyak, Sabri Cansaran; **Analysis and/or Interpretation:** Veysel Kiyak, Sabri Cansaran; **Literature Review:** Veysel Kiyak; **Writing the Article:** Veysel Kiyak, Sabri Cansaran; **Critical Review:** Sabri Cansaran.

## REFERENCES

1. Gupta N, Park J, Solomon C, Kranz DA, Wrensch M, Wu YW. Long-term outcomes in patients with treated childhood hydrocephalus. *J Neurosurg.* 2007;106(5 Suppl):334-9. [[Crossref](#)] [[PubMed](#)]
2. Brydon HL, Hayward R, Harkness W, Bayston R. Does the cerebrospinal fluid protein concentration increase the risk of shunt complications? *Br J Neurosurg.* 1996;10(3):267-73. [[Crossref](#)] [[PubMed](#)]
3. Oktem IS, Akdemir H, Koç K, Menkü A, Tucer B, Selçuklu A, et al. Migration of abdominal catheter of ventriculoperitoneal shunt into the scrotum. *Acta Neurochir (Wien).* 1998;140(2):167-70. [[Crossref](#)] [[PubMed](#)]
4. Ahmed F, Derwish W, Al-wageeh S, Ghabisha S, Al-shami E, Al-naggar K, et al. Migration of a ventriculo-peritoneal shunt into the scrotum. *J Pediatr Surg Case Rep.* 2021;73:102010. [[Crossref](#)]
5. Agha FP, Amendola MA, Shirazi KK, Amendola BE, Chandler WF. Abdominal complications of ventriculoperitoneal shunts with emphasis on the role of imaging methods. *Surg Gynecol Obstet.* 1983;156(4):473-8. [[PubMed](#)]
6. Taub E, Lavyne MH. Thoracic complications of ventriculoperitoneal shunts: case report and review of the literature. *Neurosurgery.* 1994;34(1):181-3; discussion 183-4. [[Crossref](#)] [[PubMed](#)]
7. Mohammadi A, Hedayatiasl A, Ghasemi-Rad M. Scrotal migration of a ventriculoperitoneal shunt: a case report and review of literature. *Med Ultrason.* 2012;14(2):158-60. [[PubMed](#)]
8. Kita D, Hayashi Y, Kinoshita M, Ohama K, Hamada J. Scrotal migration of the peritoneal catheter of a ventriculoperitoneal shunt in a 5-year-old male. Case report. *Neurol Med Chir (Tokyo).* 2010;50(12):1122-5. [[Crossref](#)] [[PubMed](#)]
9. Taha MM, Almenshaw HA, Ezzat M, Elbadawy MK. Migration of distal end of VP shunt into the scrotum: A Management Review. *Surg J (N Y).* 2022;8(3):e245-e8. [[Crossref](#)] [[PubMed](#)] [[PMC](#)]
10. Özveren MF, Kazez A, Çetin H, Ziyal IM. Migration of the abdominal catheter of a ventriculoperitoneal shunt into the scrotum—case report. *Neurol Med Chir (Tokyo).* 1999;39:313-5. [[Crossref](#)] [[PubMed](#)]
11. Bawa M, Garge S, Garg R, Narasimha Rao KL. Scrotal migration of tubing: an unusual complication after ventriculo-peritoneal shunt. *Asian J Neurosurg.* 2017;12(4):738-40. [[Crossref](#)] [[PubMed](#)] [[PMC](#)]
12. Paterson A, Ferch R. Infant with recurrent ventriculoperitoneal shunt migration to right scrotum. *J Clin Neurosci.* 2018;51:65-6. [[Crossref](#)] [[PubMed](#)]
13. Rehm A, Bannister CM, Victoratos G. Scrotal perforation by a ventriculoperitoneal shunt. *Br J Neurosurg.* 1997;11(5):443-4. [[Crossref](#)] [[PubMed](#)]
14. Ricci C, Velimirovic BM, Fitzgerald TN. Case report of migration of 2 ventriculoperitoneal shunt catheters to the scrotum: Use of an inguinal incision for retrieval, diagnostic laparoscopy and hernia repair. *Int J Surg Case Rep.* 2016;29:219-22. [[Crossref](#)] [[PubMed](#)] [[PMC](#)]