

# Repair of a First Trimester Uterine Dehiscence with Continuation of Pregnancy: Case Report

## İlk Trimester Eski Sezaryen Skar Dehisensinin Gebeliğin Korunarak Onarımı

İlhan ŞANVERDİ,<sup>a</sup>  
Habibe AYYACI,<sup>a</sup>  
Osman TEMİZKAN,<sup>b</sup>  
Erşan DEMİRAGÇI,<sup>a</sup>  
Sadiye EREN<sup>c</sup>

<sup>a</sup>Clinic of Obstetrics and Gynecology, Zeynep Kamil Women and Children's Training and Research Hospital,

<sup>b</sup>Clinic of Obstetric and Gynecology, Şişli Etfal Training and Research Hospital,

<sup>c</sup>Clinic of Obstetrics and Gynecology, Gynecologic Oncology Medistate Hospital, İstanbul

Geliş Tarihi/Received: 03.03.2017

Kabul Tarihi/Accepted: 22.05.2017

Yazışma Adresi/Correspondence:

Habibe AYYACI

Zeynep Kamil Women and Children's Training and Research Hospital,

Obstetrics and Gynecology, İstanbul,

TURKEY/TÜRKİYE

habibayvaci@hotmail.com

**ABSTRACT** Spontaneous uterine rupture and dehiscence are rare complications of pregnancy. While uterine rupture refers to full thickness disruption of the uterine wall, uterine dehiscence is an incomplete separation of the uterine wall with intact serosa. The dehiscence of a uterus in fetal viability limit creates a dilemma because there is not any clear treatment approach. Although rare, pregnancy continuation with the expectant approach or defect repair in the second trimester has been published. We report a first trimester uterine scar dehiscence. Ultrasound examination during valsalva maneuver and synchronous elevation of uterus by manual examination helped us in correct diagnosis. The dehiscence has been repaired with laparotomy and the pregnancy continued until 32 weeks of gestation.

**Keywords:** Pregnancy trimester, first; uterine rupture

**ÖZET** Uterus ruptürü ve dehisensi gebeliğin nadir komplikasyonlarından. Uterin ruptürde uterusun tüm katları ayrışırken, uterus dehisensinde seroza bütünlüğünü korumakta ve bu duruma kısmi bir ayrışma eşlik etmektedir. Fetal viabilite için sınır olan haftalar ve öncesinde ortaya çıkan bir uterus dehisensi tedavisi yaklaşımında netlik olmadığı için gebeliğin takibinde ikilem yaratmaktadır. Nadir olsa da, ikinci trimester dehisens olgularında beklemenin tercih edilmesi ya da uterusun onarımı sonrasında devam eden gebelik olguları bildirilmiştir. Bu olguda birinci trimester bir gebelikte uterin dehisens olgusu sündür. 31 yaşında, geçirilmiş 2 sezaryen öyküsü olan hastanın ultrasonografi eşliğinde yapılan muayenesinde, valsalva manevrası esnasında amniyotik kesenin eski insizyon hattından mesaneyeye doğru protrude olduğu izlendi. Dehisens laparotomi ile onarıldı, gebelik 32 haftaya dek devam etti.

**Anahtar Kelimeler:** Gebelik trimesteri, birinci; uterus ruptürü

Spontaneous uterine rupture and dehiscence are rare complications of pregnancy. While uterine rupture refers to full thickness disruption of the uterine wall, uterine dehiscence is an incomplete separation of the uterine wall with intact serosa.

The dehiscence of a uterus in fetal viability limit creates a dilemma because there is not any clear treatment approach.<sup>1</sup> Although rare, pregnancy continuation with the expectant approach or defect repair in the second trimester has been published.<sup>2,3</sup>

Also, there are few reported cases of first trimester uterine dehiscence associated with surgical abortion or following incomplete abortion.<sup>4,5</sup>

We report a first trimester uterine scar dehiscence. The dehiscence has been repaired with laparotomy and the pregnancy continued until 32 weeks of gestation.

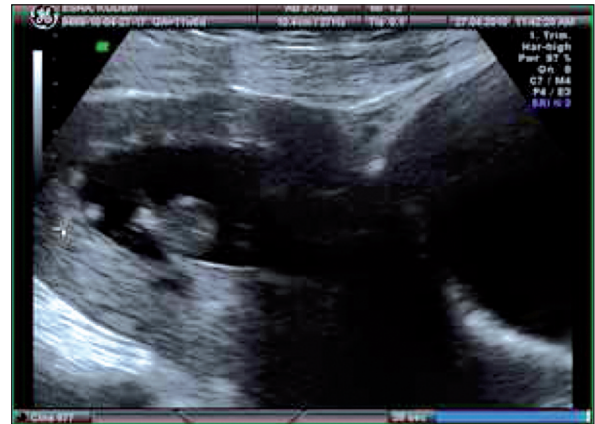## CASE REPORT

A 31-year-old woman, gravida 4, para 2, abort 1 was admitted to our institution with groin pain. She had two cesarean sections previously. Physical examination was uneventful. Vaginal examination revealed minimal vaginal bleeding with no cervical dilatation. There was pain on palpation in the suprapubic area. There was no rebound and defense.

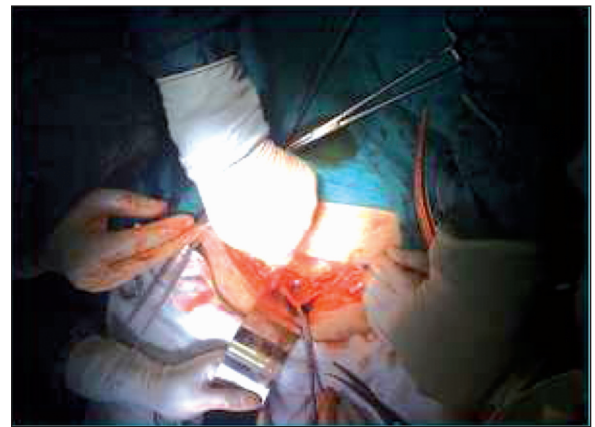
Transvaginal ultrasound (TVUSG) has detected intrauterine pregnancy compatible with 9+6 weeks with fetal cardiac activity. Complete blood count and urinalysis were uneventful. In the course of transabdominal ultrasonography (TAUSG), we observed an intrauterine gestational sac protruding towards the bladder after an uterine contraction. Therefore, the patient asked to make a valsalva maneuver. It was seen that the gestational sac got dislocated towards the bladder due to the increasing abdominal pressure. It was suspected to be a separation at the old incision level (Figure 1). Then the uterus has been elevated manually by vaginal examination and the suspected scar disruption viewed clearer.

The family was informed that the pregnancy could lead to a bleeding that poses a risk for the mother and for the fetus. The family decided to continue this pregnancy. For this reason, we decided to repair the scar dehiscence by laparotomy. The family was also informed against likely failure of repair; bleeding if the pregnancy continues, re-occurring separation, premature birth, placental abnormalities.

In the course of the laparotomy, the peritoneum was intact, the bladder was hanging on the incision line. All layers of the uterus were completely separated (Figure 2). There was 4-5 cm of opening at the old incision line of uterus. Sharp and blunt dissection was applied to suspend the bladder.



**FIGURE 1:** TAUSG: The bladder and previous cesarean scar are seen while the patient is making a valsalva maneuver. Cervix is intact.



**FIGURE 2:** Uterine dehiscence during laparotomy. Bladder was mobilized by sharp and blunt dissection.

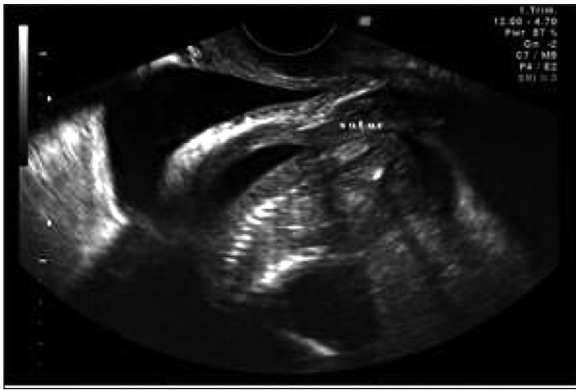Separated sutures were passed through each lip of the uterus and knotted after suturation.

In 10<sup>th</sup> postoperative day, the incision line was observed intact by ultrasonography (Figure 3).

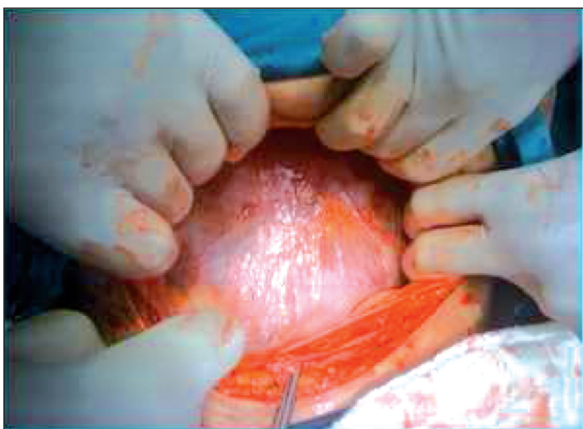At 26 weeks of gestation, TVUSG evaluation revealed a funnel shaped placenta closing the cervix but placental invasion was not considered.

At 31 weeks, the patient was admitted to the hospital with the diagnosis of preterm labor.

Antenatal corticosteroids and tocolysis with indomethacin were administered. At 32 weeks patient's vaginal bleeding began and the delivery of the fetus was planned.



**FIGURE 3:** Evaluation by TVUSG, ten days after dehiscence repair. The sutures are seen hypoechoic.



**FIGURE 4:** The uterus during cesarean section. Lower segment was clean and thick. No signs of dehiscence.

The family refused the tubal ligation suggestion. The abdomen was accessed by Pfannenstiel incision. The uterus had a clean and thick lower segment (Figure 4). A male infant of 1760 gr, with APGAR score of 6-8 was delivered. Uterus was closed in single layer with continuing locked and full-thickness sutures. The postpartum period was uneventful. The infant stayed 14 days at the newborn intensive care unit. Gynecologic examination of woman after 2 years revealed no trait, her menstrual period was regular. In the ultrasound examination the endometrium was regular, and there was a niche appearance of 2 mm. The neurological and physical development of the infant was found in natural limits.

The patient gave consent for the use of patient data, ultrasound images and operation photos for this case report.

## DISCUSSION

The dehiscence or rupture of the caesarean scar during pregnancy is a rare complication. The women who underwent caesarean, have 12 times the risk of uterine rupture or dehiscence during the delivery. The rate of uterine rupture in term pregnant women who were not at labor, was reported at 1.6 per thousand.<sup>6</sup>

The complication which is manifested due to the caesarean scar in the early pregnancy, is the caesarean scar pregnancy. Our case is a uterine dehiscence noticed in the first trimester. Following the primer suturation of the dehiscence area with laparotomy, the pregnancy continued up to 32 weeks of gestation. To our knowledge, there is one more case reported at first trimester which is a uterine scar isthmocele that was repaired with ultrasound-guided laparoscopic surgical management, and the pregnancy continued until 38 weeks.<sup>7</sup>

No treatment plan has been clarified in uterine rupture cases at gestational ages of fetal viability limit. Shiratani et al. reported that they repaired the area with fleece-coated fibrin glue in combination with closing the ruptured area by absorbable suture of a case who was admitted with hemoperitoneum in week 24 of the gestation, thus the pregnancy is prolonged until 35 weeks.<sup>8</sup> Sugawara et al. presented 5 cases as well as their case. All cases are within second trimester. All patients were intervened after they had active bleeding or while the bleeding continued. The cases were patched with TachoComb following Vicryl suture.

One case has been patched with Gore Tex.<sup>8</sup> Another case was restored with double layer sutured monocryl, single layer sutured with 3-0 Vicryl. The case reported by Roeters et al. was restored with a single layer chromic catgut with successful continuation of pregnancy.<sup>10</sup>

We did not consider the use of a synthetic patch. In intrauterine open fetal surgery cases, the uterine closure technique is defined as “uterus is closed in multiple layers, using absorbable sutures”. Based on this view, we thought that the primary suturation would be safe and sufficient.<sup>11</sup>

There are few reported cases of first trimester uterine dehiscence associated with surgical abortion or following incomplete abortion. However, there is not any ongoing pregnancy among these cases.<sup>4,5</sup> Our case is remarkable for being a first trimester uterine dehiscence with continuation of pregnancy.

Successful pregnancy with expectant management of a second trimester uterine dehiscence has been reported by Hamar et al.<sup>2</sup> We suggested to the family the options including the termination of the pregnancy and the repair of the dehiscence area. We informed them about the potential maternal and fetal complications. We didn't share the option of expectant approach because we were not aware of the existence of the case of Hamar et al. and we didn't think that such follow-up would be safe.

Another remarkable case which is recently published, is a uterine scar isthmocele that has been repaired with laparoscopic approach at 8 weeks of pregnancy. The pregnancy has reached to 38 weeks of gestation. In our case the surgery team considered laparoscopic repair, but decided to perform a laparotomy. As the membranes could be separated because of the pressure formed during pneumoperitoneum which might jeopardize the pregnancy. The successful outcome of Bolla et al. case is spectacular for this reason.<sup>7</sup>

Vikhareva et al. identified the caesarean scar defects with regard to their size in 108 patients who have undergone caesarean, but they didn't report complete dehiscence in any case.<sup>12</sup>

Considering the published data concerning the diagnosis and treatment of the cesarean section scar defects, there is no dehiscence case among non-pregnant women included into the studies.<sup>13,14</sup> Therefore, we believe that in our case the separation occurred during the pregnancy.

Indeed, it is important to identify the techniques and factors playing a role in the formation of the cesarean scar defect for the prevention of both the uterine rupture and dehiscence.

Vervoort et al. reviewed the hypothesis on the etiology of niche development and discussed the surgical techniques and patient related factors in this publication.<sup>15</sup>

While the number of the cases in women who become pregnant after the repair of post-growing niches, is limited, previa and dehiscence wasn't reported.<sup>13</sup> As the repair of the niches presenting abnormal uterine bleeding symptoms, is being suggested, the pre-pregnancy repair should also be considered in terms of pregnancy complications in larger niches.

In conclusion, it seems to be hard to diagnose a dehiscence in the first trimester. On suspicion trying to evaluate the patient under different conditions (full-bladder, valsalva, changing organ positions with mechanical manipulations) may help in diagnosis. And a dehiscence detected in the first trimester can be repaired with primary suturation. In line with the maternal conditions and the family's request, the patient can also be informed about this kind of management.

#### **Acknowledgements**

*The patient gave consent for the use of patient data , ultrasound images and operation photos for this case report.*

#### **Conflict of Interest**

*Authors declared no conflict of interest or financial support.*

#### **Authorship Contributions**

*Each author represents and warrants that he or she has participated in this study sufficiently and fulfilled the definition of authorship.*

## REFERENCES

- Palacios-Jaraquemada JM, Fiorillo A, von Petery F, Colaci D, Leguizamón G. Uterine repair and successful pregnancy after myometrial and placental rupture with massive haemoperitoneum. *BJOG* 2009;116(3):456-60.
- Hamar BD, Levine D, Katz NL, Lim KH. Expectant management of uterine dehiscence in the second trimester of pregnancy. *Obstet Gynecol* 2003;102(5 Pt 2):1139-42.
- Chen FP. Term delivery after repair of a uterine rupture during the second trimester in a previously unscarred uterus: a case report. *J Reprod Med* 2007;52(10):981-3.
- Stitely ML, Craw S, Africano E, Reid R. Uterine scar dehiscence associated with misoprostol cervical priming for surgical abortion: a case report. *J Reprod Med* 2015;60(9-10):445-8.
- Aldakhil LO. Severe vaginal bleeding secondary to cesarean scar dehiscence following incomplete abortion management. *Saudi Med J* 2010;31(2):204-5.
- Lydon-Rochelle M, Holt VL, Easterling TR, Martin DP. Risk of uterine rupture during labor among women with a prior cesarean delivery. *N Engl J Med* 2001;345(1):3-8.
- Bolla D, Raio L, Favre D, Papadia A, In-Albon S, Mueller MD. Laparoscopic ultrasound-guided repair of uterine scar isthmocoele connected with the extra-amniotic space in early pregnancy. *J Minim Invasive Gynecol* 2016;23(2):261-4.
- Sugawara T, Ogawa M, Tanaka T. Repair of uterine rupture during second trimester leading to successful pregnancy outcome: case study and literature's review. *AJP Rep* 2014;1:9-12.
- Wang PH, Chao HT, Too LL, Yuan CC. Primary repair of cornual rupture occurring at 21 weeks gestation and successful pregnancy outcome. *Hum Reprod* 1999;14(7):1894-5.
- Roeters AE, Oudijk MA, Heydanus R, Bruinse HW. Pregnancy outcome after intra-abdominal bleeding due to placenta percreta at 14 weeks of gestation. *Obstet Gynecol* 2007;109(2 Pt 2):574-6.
- Hirose S, Harrison MR. Fetal surgery. In: Prem Puri P, ed. *Newborn Surgery*. 3rd ed. Dublin: Hodder Arnold; 2011. p.246-53.
- Vikhareva Osser O, Valentin L. Risk factors for incomplete healing of the uterine incision after caesarean section. *BJOG* 2010;117(9):1119-26.
- Marotta ML, Donnez J, Squifflet J, Jadoul P, Darii N, Donnez O. Laparoscopic repair of post-cesarean section uterine scar defects diagnosed in nonpregnant women. *J Minim Invasive Gynecol* 2013;20(3):386-91.
- Borges LM, Scapinelli A, de Baptista Depes D, Lippi UG, Coelho Lopes RG. Findings in patients with postmenstrual spotting with prior cesarean section. *J Minim Invasive Gynecol* 2010;17(3):361-4.
- Vervoort AJ, Uittenbogaard LB, Hehenkamp WJ, Brölmann HA, Mol BW, Huirne JA. Why do niches develop in Caesarean uterine scars? Hypotheses on the aetiology of niche development. *Hum Reprod* 2015;30(12):2695-702.