

Importance of Free Intraperitoneal Fluid on Ultrasound in Children with Blunt Abdominal Trauma

Künt Karın Travmalı Çocuklarda Ultrasonografi ile Saptanan İntraperitoneal Serbest Sıvının Önemi

Mehmet Selim NURAL, MD, Assoc.Prof.,^a
Meltem CEYHAN, MD, Assoc.Prof.,^a
Çınar BALÇIK, MD,^a
Muzaffer ELMALI, MD, Assoc.Prof.^a

^aDepartment of Radiology,
Ondokuz Mayıs University
Faculty of Medicine, Samsun

Geliş Tarihi/Received: 11.10.2011
Kabul Tarihi/Accepted: 10.02.2012

*This study was presented as a poster at
46th Annual Meeting of European Society of
Pediatric Radiology in Istanbul-Turkey .*

Yazışma Adresi/Correspondence:
Mehmet Selim NURAL, MD, Assoc.Prof.
Ondokuz Mayıs University
Faculty of Medicine,
Department of Radiology, Samsun,
TÜRKİYE/TURKEY
msnural@omu.edu.tr

ABSTRACT Objective: The assessment of importance of free intraperitoneal fluid determination without solid organ injury by ultrasound (US) in children who had blunt abdominal trauma (BAT). **Material and Methods:** The clinical and imaging data of 230 children with BAT were reviewed retrospectively. All children underwent an abdominal US examination as the primary screening method. Patients with free intraperitoneal fluid without any solid-organ injury according to US examination were included in the study. The localization of intra-peritoneal fluid was also noted. US findings were compared with findings of computerized tomography, laparotomy and clinical course. **Results:** Intraperitoneal fluid was determined in 22 patients by US examination. Fluid was located in any location in the abdominal cavity with or without pelvis involvement in 11 patients, and 6 of them had intra-abdominal injury according to final diagnosis. Remaining 11 patients had only free pelvic fluid and 2 of them had pelvic wall injury. However any intra-abdominal injury was not determined in 11 patients with only free pelvic fluid (group 1), intra-abdominal injury was determined in 1 (25%) of 4 patients who had free fluid in a single intraperitoneal space except pelvis (group 2) and in 5 (71%) of 7 patients who had free fluid in any of the intra-peritoneal spaces in addition to pelvis (group 3). Intra-abdominal injury was significantly higher in group 3 when compared to group 1 (Fisher's exact test p=0.002). **Conclusion:** US is an effective screening method in hemodynamically stable patients with BAT. Clinical follow up of such patients is enough because the risk of serious intra-abdominal injury is low in patients with only free fluid in pelvis detected by US. However, the presence of free fluid in any abdominal location beyond the pelvis necessitates examination with further imaging modalities.

Key Words: Abdominal injuries; child; ultrasonography

ÖZET Amaç: Künt karın travmalı (KKT) çocuklarda yapılan ultrasonografide (USG) solid organ yaralanması olmaksızın saptanan intraperitoneal serbest sıvının öneminin değerlendirilmesidir. **Gereç ve Yöntemler:** KKT'li 230 çocuk hastanın klinik ve görüntüleme bulguları geriye dönük olarak incelendi. Hastaların tümünde ilk tarama yöntemi olarak USG incelemesi yapılmıştı. USG ile solid organ yaralanması olmaksızın sadece intraperitoneal serbest sıvısı saptanan hastalar çalışmaya alındı. İntraperitoneal serbest sıvının lokalizasyonu belirlendi. USG bulguları bilgisayarlı tomografi, laparotomi bulguları ve klinik gözlem sonucu ile elde edilen son tanı ile karşılaştırıldı. **Bulgular:** USG ile 22 hastada intraperitoneal sıvı saptandı. Hastaların 11'inde serbest sıvı, pelvis dışındaki karın içi boşluklarda veya pelvis ile birlikte diğer karın içi boşluklarda idi ve bunların 6'sında, son tanıya göre karın içi yaralanma vardı. Sadece pelvik sıvı saptanan diğer 11 hastanın 2'sinde pelvik duvar yaralanması saptandı. Bu hastaların hiçbirinde karın içi yaralanma saptanmazken (grup 1), pelvis dışı tek bir intraperitoneal kompartmanda sıvı saptanan 4 hastanın (grup 2) 1'inde (%25) ve pelvis ile birlikte diğer intraperitoneal kompartmanlarda sıvı saptanan 7 hastanın (grup 3) 5'inde (%71,4) karın içi yaralanma saptanmış olup grup 3'te karın içi yaralanma saptanma sıklığı grup 1 ile karşılaştırıldığında istatistiksel olarak daha yüksekti (Fisher's exact test p=0,002). **Sonuç:** USG hemodinamisi stabil KKT'li hastalarda oldukça etkili bir tarama yöntemidir. USG ile sadece pelvik serbest sıvı saptanan hastalarda ciddi bir karın içi yaralanma riski düşük olduğundan bu hastaların klinik takibi yeterli görülmektedir. Pelvis dışında herhangi bir kompartmanda serbest sıvı varlığında ise ek görüntüleme yöntemlerine ihtiyaç vardır.

Anahtar Kelimeler: Karın yaralanmaları; çocuk; ultrasonografi

doi: 10.5336/medsci.2011-26801

Copyright © 2012 by Türkiye Klinikleri

Türkiye Klinikleri J Med Sci 2012;32(4):1049-53

Imaging methods play a major role for the evaluation of intra-abdominal organ injury because non-operative management of blunt abdominal trauma (BAT) has recently gained widespread acceptance in children. Computerized tomography (CT) and ultrasound (US) are the primary radiological methods for the detection of injury in patients with BAT. CT examination has advantages for accurately detecting localization and quantification of any injury to solid organs and hollow viscera in the abdomen.¹ On the other hand, it involves a high radiation dose (around 30 mSv in each exam) almost equal to 12 years of background radiation. It has been shown that the lifetime risk of a malignancy induced by radiation dose of a single CT examination is associated with ages.^{2,3} Therefore, it was previously stated that "if CT scanning is used uncritically as a routine screening tool in all children with BAT, a large number of children without any significant injury might be unnecessarily exposed to high levels of radiation".³ The knowledge and experience with US technique, which is a radiation-free method, in the management of patients with BAT will gradually decrease unnecessary CT examinations and radiation exposures. Although the management of BAT patients with normal abdominal US involves a routine procedure, the clinical procedures for patients with some pathological findings in US may vary in different centers. The main purpose of this study is to assess the importance of the US finding of free intraperitoneal fluid without solid organ injury after BAT in hemodynamically stable children.

MATERIAL AND METHODS

All of pediatric patients with general body trauma seen in our emergency department between June 2007 and December 2010 were enrolled into the study retrospectively. The study was conducted according to Helsinki declaration principles. A total of 230 children who had primary radiological evaluations by US were included in the study. The US examinations were performed by the radiology residents in charge at the emergency room. The presence of free fluid within the abdominal cavity and/or organ injury was accepted as a positive sign for intra-abdominal injury. Patients were divided

into 3 groups according to fluid localization: The patients who had only intra-pelvic free fluid (group 1), the ones with free fluid in intra-abdominal cavity outside pelvis (group 2) and the ones with free fluid in any location besides pelvis (group 3). US examinations were performed with SSA-270A (Toshiba, Japan) sonography device with a 3.75 MHz convex probe.

Secondary CT scan evaluations were performed by a single-row detector helical CT scanner device (X press/GX model TSX-002a, Toshiba, Tochigi-Ken, Japan) with the following scanning parameters: 80 mA, 120 kV, pitch 1.5, table feed of 5 mm per rotation, 5 mm reconstruction interval and 5 mm-thick sections. A scout image was obtained in supine position from the lower thoracic level through the level of pubic symphysis. During the examination, all patients received 2 mL/kg of intravenous non-ionic contrast material at a flow rate of 2 mL/sec. CT examination started 60 seconds after the initiation of contrast material injection.

US findings were compared with the findings obtained by repeated US, CT and laparotomy. Patients who had no examination other than initial US were evaluated by clinical observation. These patients who were discharged without any further evaluations were considered as normal. Sensitivity, specificity, positive predictive value, negative predictive value and accuracy of US for determination of intra-abdominal organ injury were calculated. The comparison of presence of injury according to the localization of intra-peritoneal fluid was done by using Fisher's exact tests. A p value of <0.05 is accepted as statistically significant. The agreement between US and the final diagnosis is evaluated by using Kappa (measurement of agreement test) test.

RESULTS

Total of 230 patients (101 males and 129 females) who had undergone US examination for BAT were included in this retrospective study. The most frequent causes of BAT were falls from height and vehicle accidents (Table 1). Ages of the patients ranged between 8 months and 204 months, median age was 66 (8-204) months.

Etiology	Patients (n)
Intra-vehicular accidents	43
Extra-vehicular accidents	39
Falls from height	133
Others	15
Total	230

Two hundred thirty patients were enrolled into the study and CT imaging was made in 30 patients, CT and laparotomy was performed in two patients and control US examination was performed in one patient whereas the remaining 197 patients were followed up at the department of emergency until they were discharged. Intra-abdominal injury was determined in 16 patients as the final diagnosis (Figure 1).

US examination was normal in 199 patients. Only nine of them had further CT scanning and of those, a single patient was reported to have hepatic capsular laceration (false negative for US) by CT. Remaining patients were observed clinically and then discharged.

Of 230 patients who had an initial US, 31 had pathological findings; free fluid in 22 patients, free fluid and organ injury in 3 patients, free fluid and retro-peritoneal hematoma in 2 patients, retro-

peritoneal hematoma in 2 patients, perirenal hematoma in 1 patient and intra-psoas muscle hematoma in 1 patient. Pathologic findings other than free abdominal fluid were diagnosed by CT and all patients were hospitalized, however only one of them needed a surgical intervention. US examination of 22 patients with free intra-peritoneal fluid without any solid organ injury revealed intra-abdominal free fluid outside of pelvis in 4, free fluid in any intra-abdominal cavity besides pelvis in 7, and only intra-pelvic free fluid in 11 patients (Figure 2). Of these 22 patients, seven were followed by observation unit of pediatric emergency department, while the remaining 15 children were followed at inpatients ward and only one needed an urgent explorative surgery.

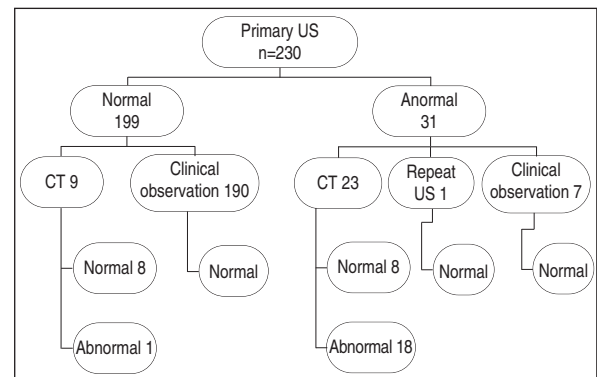


FIGURE 1: The summary of the procedure and findings of 230 patients.

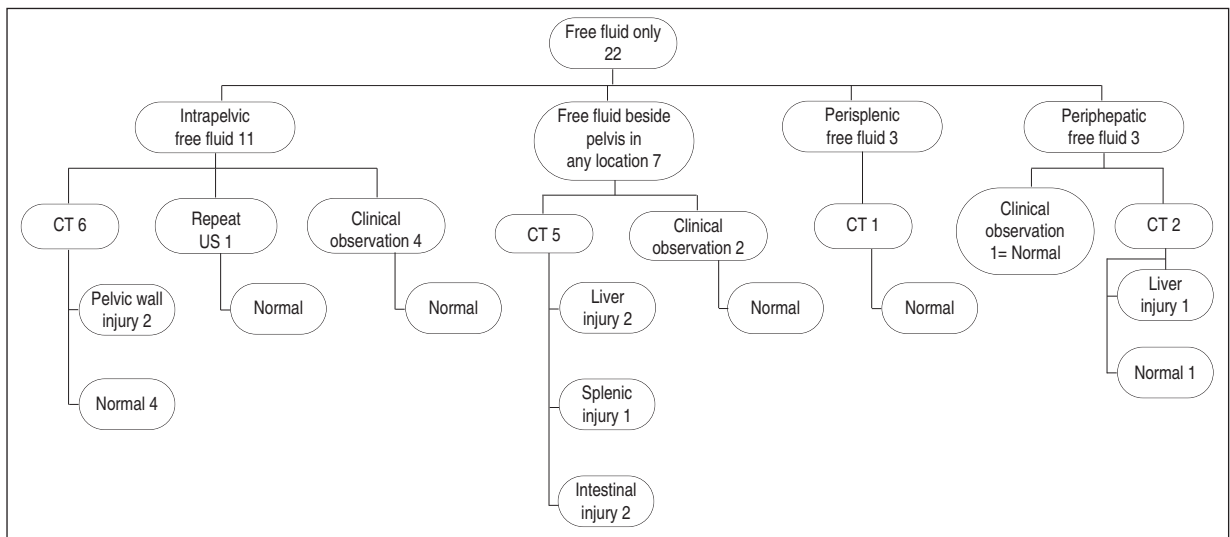


FIGURE 2: The procedure and final diagnosis of patients who had intraperitoneal free fluid.

Pelvic wall injury was determined in 2 patients among 11 patients who had only free pelvic fluid. Although intra-abdominal injury was not determined in these patients (group 1), intra-abdominal injury was determined in 1 (25%) of 4 patients who had free fluid in single intra-peritoneal space except pelvis (group 2) and in 5 (71%) of 7 patients who had free fluid in any of intra-peritoneal spaces in addition to pelvis (group 3). Intra-abdominal injury was significantly higher in group 3 compared to group 1 (Fisher's exact test $p=0.002$). There was no statistically significant difference between group 1 and group 2 ($p=0.313$) and between group 2 and group 3 ($p=0.242$).

US results were true positive in 15, false positive in 16, true negative in 198 and false negative in one patient. Sensitivity, specificity, positive predictive value, negative predictive value and accuracy for determination of the intra-abdominal organ injury were found as 93%, 92%, 48%, 99% and 92%, respectively. The agreement value between US and the final diagnosis was $k=0.60$ ($p<0.001$).

DISCUSSION

Although imaging methods used for BAT vary in different health centers, US examination has preserved its value for initial evaluation. Free intraperitoneal fluid can be an important sign in children with BAT. The management of patients who have free intra-peritoneal fluid detected by US without any organ injury is controversial. Recently, it has been reported that isolated free fluid was determined in approximately 3% of patients on the initial multidetector CT evaluation in male patients with blunt trauma and it may have no clinical significance.⁴ A small amount of isolated pelvic free fluid without any identifiable cause has been determined in 5.0% (48 of 1000) of male patients in another study.⁵ Another study, which was carried out on asymptomatic children, showed that US examination disclosed minimal free pelvic fluid in 6% of patients and it did not have any clinical value.⁶ In our study, US examination revealed isolated free pelvic fluid in 11 (4.8%) of 22 children with blunt abdominal trauma. In this group of chil-

dren, six patients undergone CT scanning and two of them were detected with pelvic bone fracture and soft tissue injury without any organ involvement. These results showed that the patients with only intrapelvic free fluids determined by US can be followed up clinically or repeated US examinations without any further investigation.

In a large series of 744 patients, Richards et al. reported that 51 patients had free intraperitoneal fluid with false positive in 9 patients.⁷ Seven of them were females and it had been suggested that pelvic fluid may depend on some physiological conditions.⁷ Similarly, the study of Brown et al. on 92 patients, who had false positive findings by US, showed that CT scan of patients with free fluid by US did not determine intra-abdominal pathology in 31 patients whereas it determined normal physiological fluid in 26 patients.⁸ In a different pediatric age group, Katz et al. reported 18 false positive results and they had argued that false positive free pelvic fluid might have been related to some normal physiological conditions commonly seen in children.⁹ In another study performed on females at reproductive age with trauma by Sirlin et al., abdominal injury was not reported in 54 out of 56 patients who had free fluid only in cul-de-sac detected by US examination.¹⁰ They commented as follows: "In female patients at reproductive age with trauma, free fluids isolated to the cul-de-sac is likely physiologic; clinical follow-up should suffice".¹⁰ In addition to this, as clearly seen in our study, some other papers also stated that free intra-abdominal fluid may exclusively related to pelvic skeletal injury without any abdominal organ involvement.¹¹⁻¹³

Rathaus et al. reported high probability of organ injury in pediatric age group with extrapelvic free fluid in US.¹⁴ In this study, there was no statistical difference in patients with or without pelvic fluid in US when compared for organ injury, and therefore it was concluded that there was minimal probability of organ injury when the fluid is absent or only pelvic.¹⁴ In our study, five out of seven patients reported with free fluid in any location besides pelvis were confirmed as true positive by CT scan (two had liver laceration, two had intestinal injury and one other had splenic injury).

Orak et al. reported that the ratios of isolated organ injuries were higher in patients with intraperitoneal fluid (34.1%) compared to patients with pelvic fluid (2.3%).¹⁵ Presence of intraperitoneal fluid was significantly associated with solid organ injuries ($p < 0.005$).¹⁵ Under the light of these findings, we may suggest that, CT scanning should be reserved for the patients who have free fluid in another intra-abdominal space in addition to pelvis.

Browning et al. stated that if CT scanning is used as a primary tool for abdominal injury, many children will superfluously be exposed to high radiation though they have no serious condition at all.³ So far, US seems to be an efficient method of evaluation for hemodynamically stable children with pelvic fluid, as it has no radiation risk, it can be used repeatedly, and it is a fast, reliable, and easy to use side-by-side tool of radiology. US was also stated as an efficient and valuable primary tool in children with BAT.¹⁶

It can be considered that clinical follow up of the patients with isolated free pelvic fluid is adequate for children with BAT because any organ injury was not determined in patients with isolated free pelvic fluid. Studies with a larger population are needed for supporting this concept. One of the limitations of our study is small sample size. The study could not be assessed if there was any relation between the amount of fluid and intra-abdominal injury because we did not measure the fluid amount in our retrospective study.

Therefore, we concluded that US is an efficient screening method for hemodynamically stable children with BAT. Due to the fact that the risk of serious intra-abdominal injury is low in patients with only free fluid in pelvis detected by US, it seems sufficient to follow up such patients clinically. However, the presence of free fluid in any abdominal location besides pelvis necessitates examination with further imaging modalities.

REFERENCES

- Sivit CJ. Contemporary imaging in abdominal emergencies. *Pediatr Radiol* 2008;38 (Suppl 4):S675-8.
- Brenner D, Elliston C, Hall E, Berdon W. Estimated risks of radiation-induced fatal cancer from pediatric CT. *AJR Am J Roentgenol* 2001;176(2):289-96.
- Browning JG, Wilkinson AG, Beattie T. Imaging paediatric blunt abdominal trauma in the emergency department: ultrasound versus computed tomography. *Emerg Med J* 2008; 25(10):645-8.
- Drasin TE, Anderson SW, Asandra A, Rhea JT, Soto JA. MDCT evaluation of blunt abdominal trauma: clinical significance of free intraperitoneal fluid in males with absence of identifiable injury. *AJR Am J Roentgenol* 2008;191(6):1821-6.
- Yu J, Fulcher AS, Wang DB, Turner MA, Ha JD, McCulloch M, et al. Frequency and importance of small amount of isolated pelvic free fluid detected with multidetector CT in male patients with blunt trauma. *Radiology* 2010;256(3):799-805.
- Simanovsky N, Hiller N, Lubashevsky N, Rozovsky K. Ultrasonographic evaluation of the free intraperitoneal fluid in asymptomatic children. *Pediatr Radiol* 2011;41(6):732-5.
- Richards JR, Knopf NA, Wang L, McGahan JP. Blunt abdominal trauma in children: evaluation with emergency US. *Radiology* 2002; 222(3):749-54.
- Brown MA, Casola G, Sirlin CB, Patel NY, Hoyt DB. Blunt abdominal trauma: screening us in 2,693 patients. *Radiology* 2001;218(2): 352-8.
- Katz S, Lazar L, Rathaus V, Erez I. Can ultrasonography replace computed tomography in the initial assessment of children with blunt abdominal trauma? *J Pediatr Surg* 1996;31(5): 649-51.
- Sirlin CB, Casola G, Brown MA, Patel N, Bendavid EJ, Deutsch R, et al. Us of blunt abdominal trauma: importance of free pelvic fluid in women of reproductive age. *Radiology* 2001;219(1):229-35.
- Nural MS, Yordan T, Güven H, Baydin A, Bayrak IK, Kati C. Diagnostic value of ultrasonography in the evaluation of blunt abdominal trauma. *Diagn Interv Radiol* 2005; 11(1): 41-4.
- Ng AK, Simons RK, Torreggiani WC, Ho SG, Kirkpatrick AW, Brown DR. Intra-abdominal free fluid without solid organ injury in blunt abdominal trauma: an indication for laparotomy. *J Trauma* 2002;52(6):1134-40.
- Brasel KJ, Olson CJ, Stafford RE, Johnson TJ. Incidence and significance of free fluid on abdominal computed tomographic scan in blunt trauma. *J Trauma* 1998;44(5):889-92.
- Rathaus V, Zissin R, Werner M, Erez I, Shapiro M, Grunebaum M, et al. Minimal pelvic fluid in blunt abdominal trauma in children: the significance of this sonographic finding. *J Pediatr Surg* 2001;36(9):1387-9.
- Orak M, Ustündağ M, Güloğlu C, Gökdemir MT, Erdoğan MO, Al B. Clinical importance of ultrasonographic pelvic fluid in pediatric patients with blunt abdominal trauma. *Turkish Journal of Trauma and Emergency Surgery* 2010;16(2):155-9.
- Akgür FM, Aktuğ T, Olguner M, Kovanlıkaya A, Hakgüder G. Prospective study investigating routine usage of ultrasonography as the initial diagnostic modality for the evaluation of children sustaining blunt abdominal trauma. *J Trauma* 1997;42(4):626-8.